Iowa ACC FIT Virtual Echo Board Prep Series

Diseases of the Aorta

Karthikeyan Ananthasubramaniam, MD FACC FASE FASNC FSCCT FSCMR FRCP
Professor of Medicine
Director, Nuclear Cardiology/Cardiac PET Laboratory
Co-Director, Adult Congenital Heart Disease Program
Program Director, Advanced Cardiac Imaging Fellowship
Heart and Vascular Institute
Henry Ford West Bloomfield Hospital,
West Bloomfield, Michigan

Governer-Elect/President-Elect, Michigan Chapter, ACC

kananth1@hfhs.org

No relevant disclosures

Examination Content Outline

I. Physical Principles, Instrumentation, Examination Principles

- A. Routine Doppler Examination
- B. Transesophageal Echocardiography, Intraoperative Echocardiography, and Catheter-Based Echocardiography (ICE)
- C. Physical Principles of Ultrasound
- D. Cross-Sectional Echocardiographic Examination
- E. Principles of Doppler Flow Measurement
- F. Cross-Sectional Scanning: Technical Principles and Instrumentation
- G. Standard Plane Positions – Standard Imaging Planes
- H. Doppler Instrumentation
- I. Principles of Flow
- J. Principles of Color Flow Mapping
- K. M-Mode Echocardiography
- L. Digital Image Processing
- M. Doppler Signal Processing, Tissue Characterization
- N. Three-Dimensional Echocardiography
- O. Place (Role) of Echocardiography
- P. Hand-Held Echo
- Q. Laboratory Accreditation

II. Valvular Heart Disease

- A. Aortic Valve, Aorta, and Subvalvular Outflow Tract
- B. Mitral Valve
- C. Echo-Doppler Assessment of Prosthetic Heart Valves
- D. Echocardiographic Findings in Infective Endocarditis
- E. Fluid Dynamics of Regurgitant Jets
- F. Tricuspid Valve
- G. Pulmonic Valve
- H. Pulmonary Hypertension

III. Chamber Size and Function

- A. Coronary Artery Disease, Stress Echocardiography
- B. General Considerations, Assessment of Chamber Size and Function
- C. Echocardiographic Assessment of the Cardiomyopathies
- D. Diastolic Function
- E. Left Atrium, Pulmonary Veins, and Coronary Sinus
- F. Right Ventricle
- G. Right Atrium
- H. Interatrial and Interventricular Septum
- I. Inferior and Superior Vena Cava
- J. Doppler Estimation of Volumetric Flow
- K. Coronary Arteries

IV. Congenital Heart Disease

- A. Complex Congenital Heart Disease
- B. Aortic Valve, Aorta, and Subvalvular Outflow Tract
- C. Tricuspid Valve Anomalies
- D. Mitral Valve
- E. Doppler Estimation of Volumetric Flow
- F. Pulmonic Valve Anomalies
- G. Coronary Arteries Anomalies
- H. Fetal Echocardiography
- I. Terminology and Anatomic and Physiologic Basis of CHD
- J. Principles of Medical and Surgical Management
- K. Echo Evaluation of Post-Op Congenital Heart Disease

V. Cardiac Masses, Pericardial Disease, Contrast and New Applications

- A. Pericardial Disease
- B. Cardiac Tumors and Masses
- C. Contrast Echocardiography
- D. Assessment of Myocardial Perfusion with Contrast
- E. Echocardiography in Disorders of Cardiac Rhythm and Conduction
- F. Echocardiography in Cardiac Transplantation

VI. Miscellaneous Topics (Role of Echo)

- A. Heart Failure
- B. Cardiac Sources of Embolism (PFO, ASA, SEC, Aortic Atheroma, etc)
- C. Pulmonary Heart Disease
- D. Systemic Diseases
- E. Atrial Fibrillation
- F. Trauma
- G. Athlete's Heart
- H. Aging Hearts
- I. Pregnancy
- J. Interventional Echocardiography
- K. Digital Lab
- L. Quality in the Echo Lab

Reference Statement

NBE does not endorse or recommend any third-party review course or material. Any text in cardiovascular techniques and evaluation, cardiac patient care and management may be used. Current standards and guidelines endorsed by professional societies are also appropriate.

Suggested reading

European Journal of Echocardiography (2010) **11**, 645–658
doi:10.1093/ejechocard/jeq056

RECOMMENDATIONS

Echocardiography in aortic diseases: EAE recommendations for clinical practice

Arturo Evangelista[1]*, Frank A. Flachskampf[2], Raimund Erbel[3], Francesco Antonini-Canterin[4], Charalambos Vlachopoulos[5], Guido Rocchi[6], Rosa Sicari[7], Petros Nihoyannopoulos[8], and Jose Zamorano[9] on behalf of the European Association of Echocardiography

GUIDELINES AND STANDARDS

Multimodality Imaging of Diseases of the Thoracic Aorta in Adults: From the American Society of Echocardiography and the European Association of Cardiovascular Imaging

Endorsed by the Society of Cardiovascular Computed Tomography and Society for Cardiovascular Magnetic Resonance

(J Am Soc Echocardiogr 2015;28:119-82.)

Aortic disease

- Atherosclerotic
  - Aneurysm
  - Atheroembolic disease
  - Rupture
  - Pseudoaneurysm
  - Penetrating ulcer
  - Dissection
  - Intramural hematoma
- Non-atherosclerotic
  - Cystic medial necrosis
  - Aneurysm
  - Aortic dissection
  - Intramural hematoma
  - Anuloaortic ectasia
- Inflammatory/infectious
  - Takayasu arteritis
  - Giant cell arteritis
  - Endocarditis
- Miscellaneous
  - Trauma
  - Intraluminal thrombus
  - Poststenotic dilation
  - Hypertension
  - Aortic insufficiency/Stenosis
  - Iatrogenic injury

Objectives

Kick off Ques
Aortic anatomy
Basic Measurements by echo
Brief comparison of modalities
Dissection (acute and chronic)
Aneurysms
False alarms
Bicuspid aortic valve/aortopathy
Coarctation
Marfan
Loeys-Dietz
Atherosclerotic Disease
Kick off Ques (Ans)

Question 1

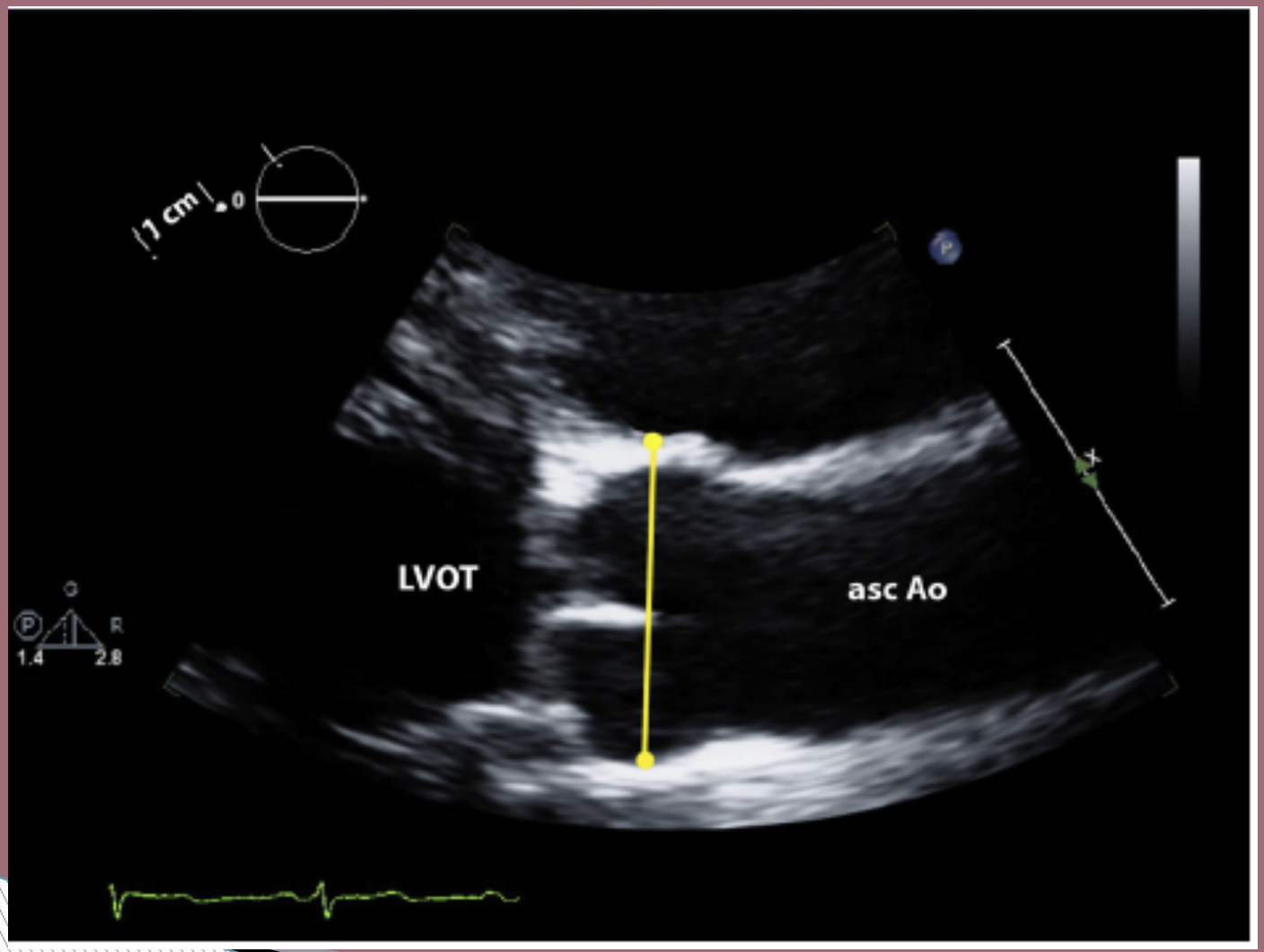

The following measurement of the aortic root on 2D TTE follows ASE guidelines

a true
b false

Question 2

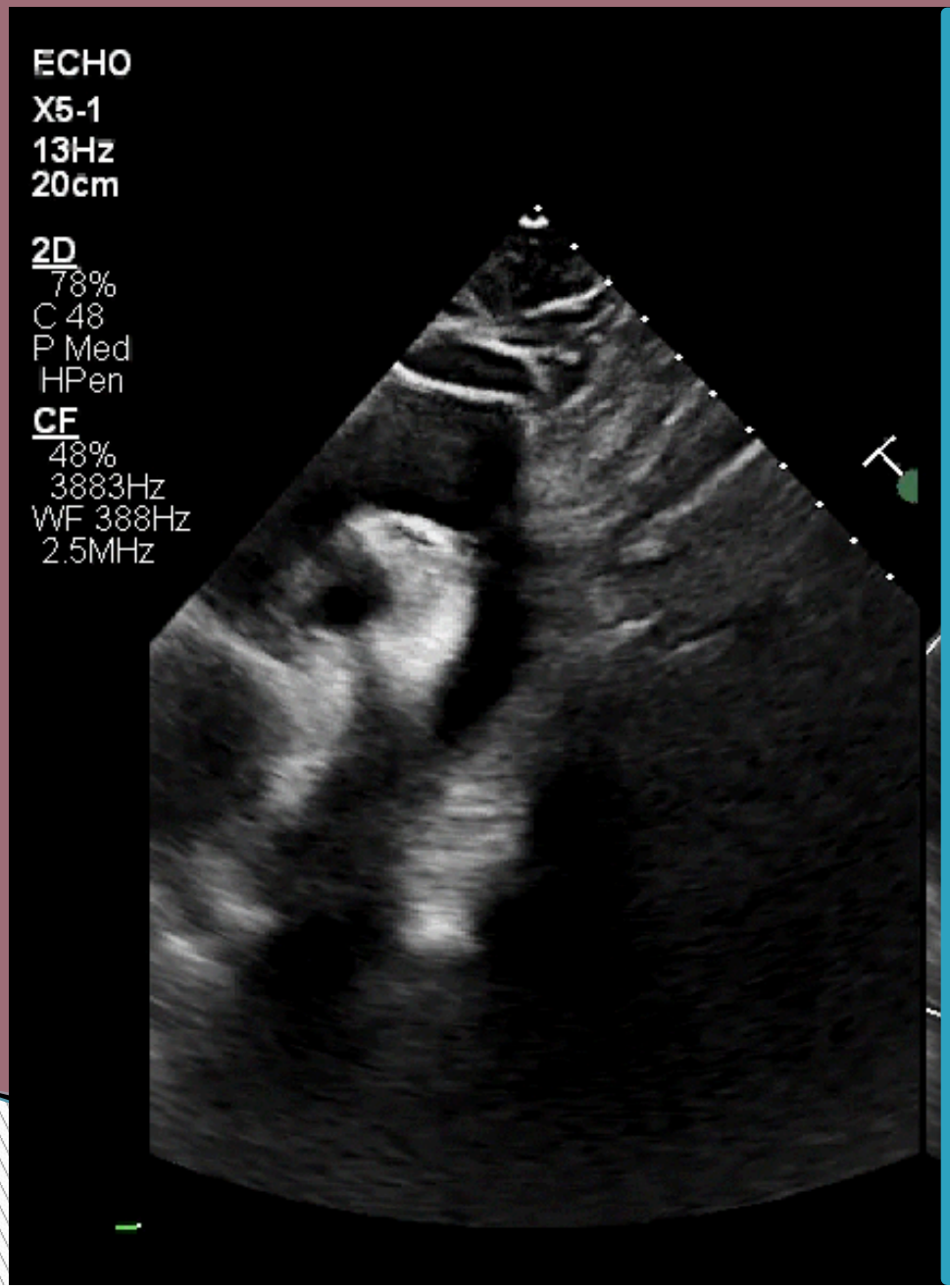

In the provided arch view choose the most appropriate response for this movie clip

1. normal suprasternal view
2. arch dissection
3. arch aneurysm
4. anomalous venous drainage

Question 3

Which of the following conditions associated with aortic aneurysmsis called by TGFBeta or SMAD 3 mutation with syst connective tissue involvement ?

a. Bicuspid Aortopathy
b. Loey Dietz syndrome
c. Marfan syndrome
d. Ehlers-Dalos syndrome

Question 4

Which of the following characteristics is true for identifying a false lumen (FL) from true lumen (TL) in aortic dissection ?

1. FL is smaller in size than true
2. Systolic compression is usually seen with FL
3. Color flow can be seen from FL to TL
4. Flow is brisk in FL

Normal Anatomy

- The aortic annulus represents the junction of the proximal ascending aorta with LVOT.
- It is part of the fibrous skeleton of the heart and is contiguous with the anterior mitral valve leaflet and perimembranous septum.
- Relatively resistant to dilation.
- Annulus dimension is very close to LVOT dimension.

- The geometry of the sinotubular junction is a crucial feature of normal aortic valve coaptation.
- Insertion of aortic valve cusps is continuous from the level of the annulus up through the sinuses to the level of the sinotubular junction.
- Dilation of the sinotubular junction can result in malcoaptation of the aortic cusps resulting in secondary aortic insufficiency.

Normal Aortic Anatomy

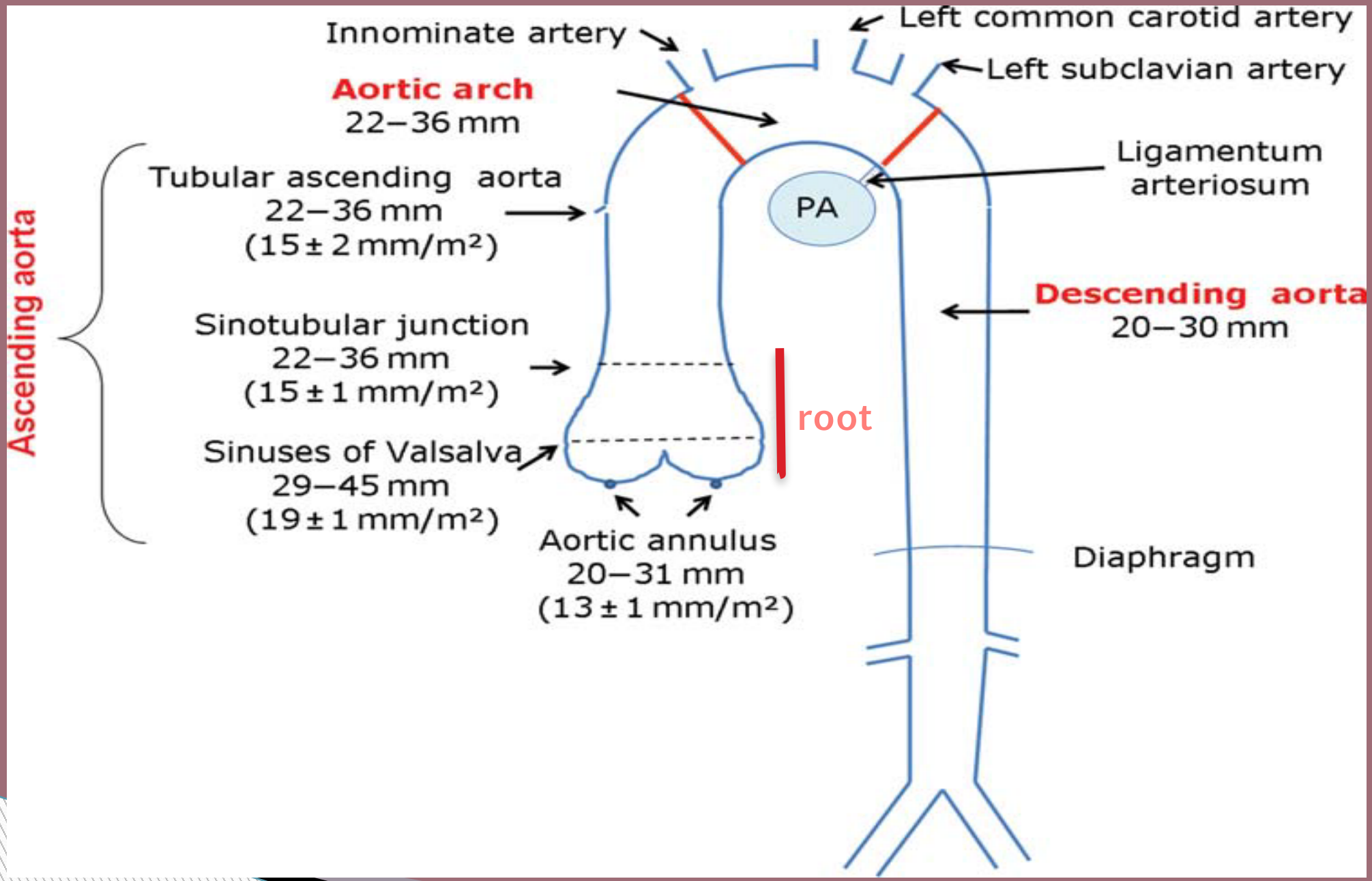

modified from

European Journal of Echocardiography (2010) **11**, 645–658

Normal Aortic Root Measurements

Male

	Age (y)					
	15–29	30–39	40–49	50–59	60–69	≥70
Mean normal (cm)	3.3	3.4	3.5	3.6	3.7	3.8
Upper limit of normal (cm) (95% CI)	3.7	3.8	3.9	4.0	4.1	4.2

Add 0.5 mm per 0.1 m^2 BSA above 2.0 m^2 or subtract 0.5 mm per 0.1 m^2 BSA below 2.0 m^2.[6]

Female

	Age (y)					
	15–29	30–39	40–49	50–59	60–69	≥70
Mean normal (cm)	2.9	3.0	3.2	3.2	3.3	3.4
Upper limit of normal (cm)	3.3	3.4	3.6	3.6	3.7	3.9

Add 0.5 mm per 0.1 m^2 BSA above 1.7 m^2 or subtract 0.5 mm per 0.1 m^2 BSA below 1.7 m^2.[6]

age : 1-15 16-39 >/=40

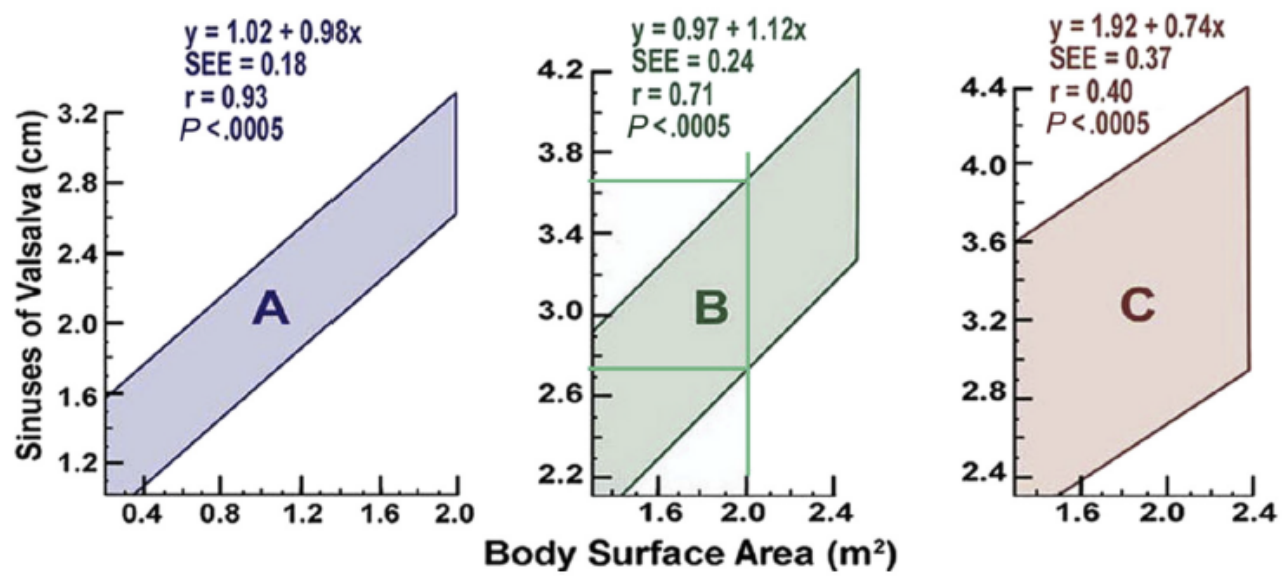

Journal of the American Society of Echocardiography
Volume 28 Number 2

- Aorta size is related most strongly to body surface area (BSA)and age.
- Indexing by height avoids the influence of overweight on BSA (limitation of large data)
- Avoid overestimation with oblique segments,
  perform measurement only when circular sections are obtained.
- Measurements of descending thoracic aorta in short axis and of the aortic arch in long axis are recommended.

Typical Echo Views for Aorta Interrogation

View	Part of aorta
Transthoracic echo	
Parasternal long + short axis	Ascending + descending thoracic
Apical four-chamber	Descending thoracic
Apical two-chamber and/or long axis	Descending thoracic
Suprasternal	Arch, descending + ascending thoracic
Subcostal	Abdominal (+ascending thoracic)
Transoesophageal echo	
Upper oesophageal long + short axis	Ascending thoracic
Aortic (long + short axis)	Descending thoracic + arch

European Journal of Echocardiography (2010) **11**, 645–658

TTE

- Although TTE is not the ideal tool for visualizing all aortic segments, important information can always be gained by careful use of all echo windows.
- In all patients with suspected aortic disease, the right parasternal view is recommended for estimating the true size of the ascending aorta.
- Underutilized : Right parasternal

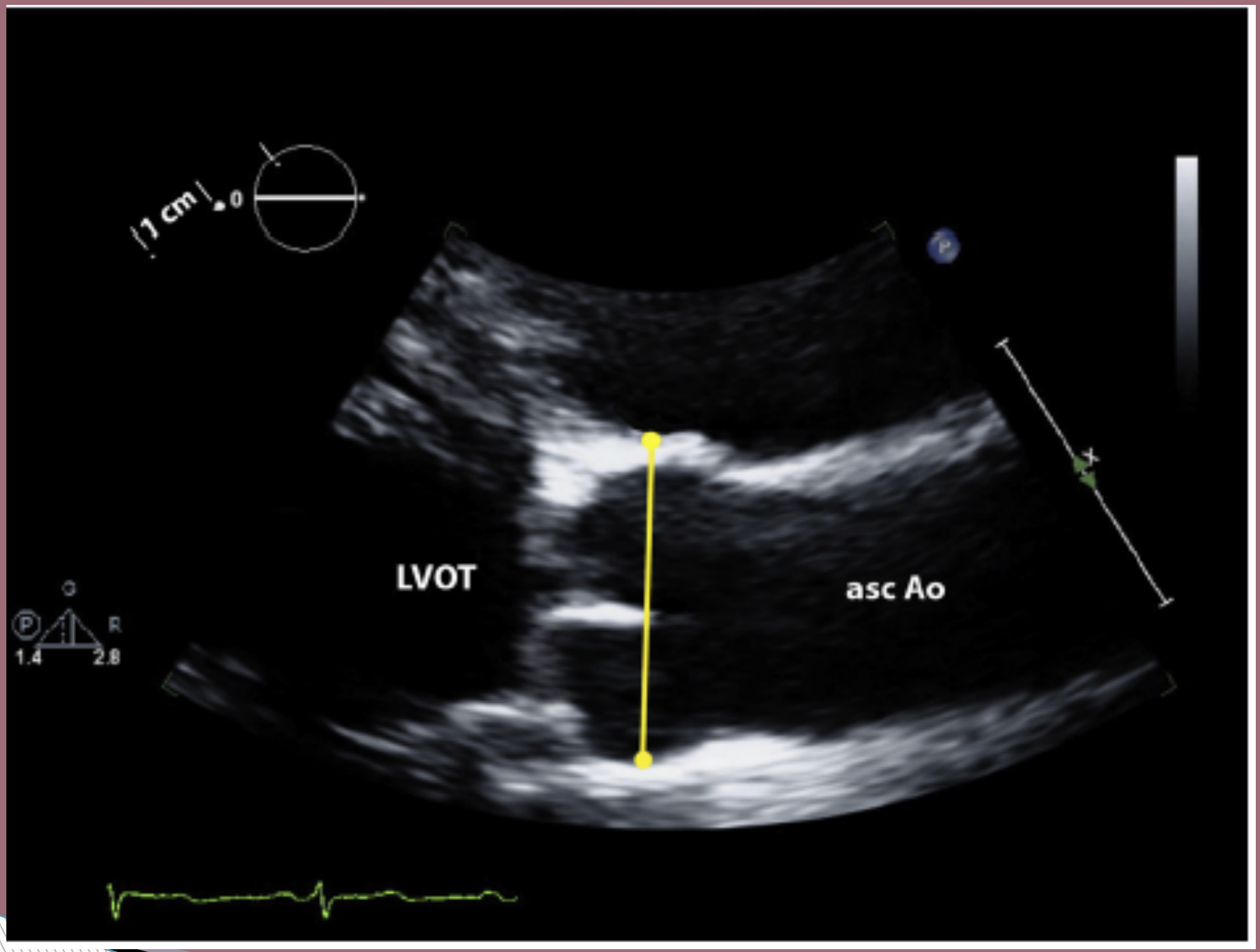
1 cm
0
LVOT
asc Ao
G
P
R
1.4
2.8

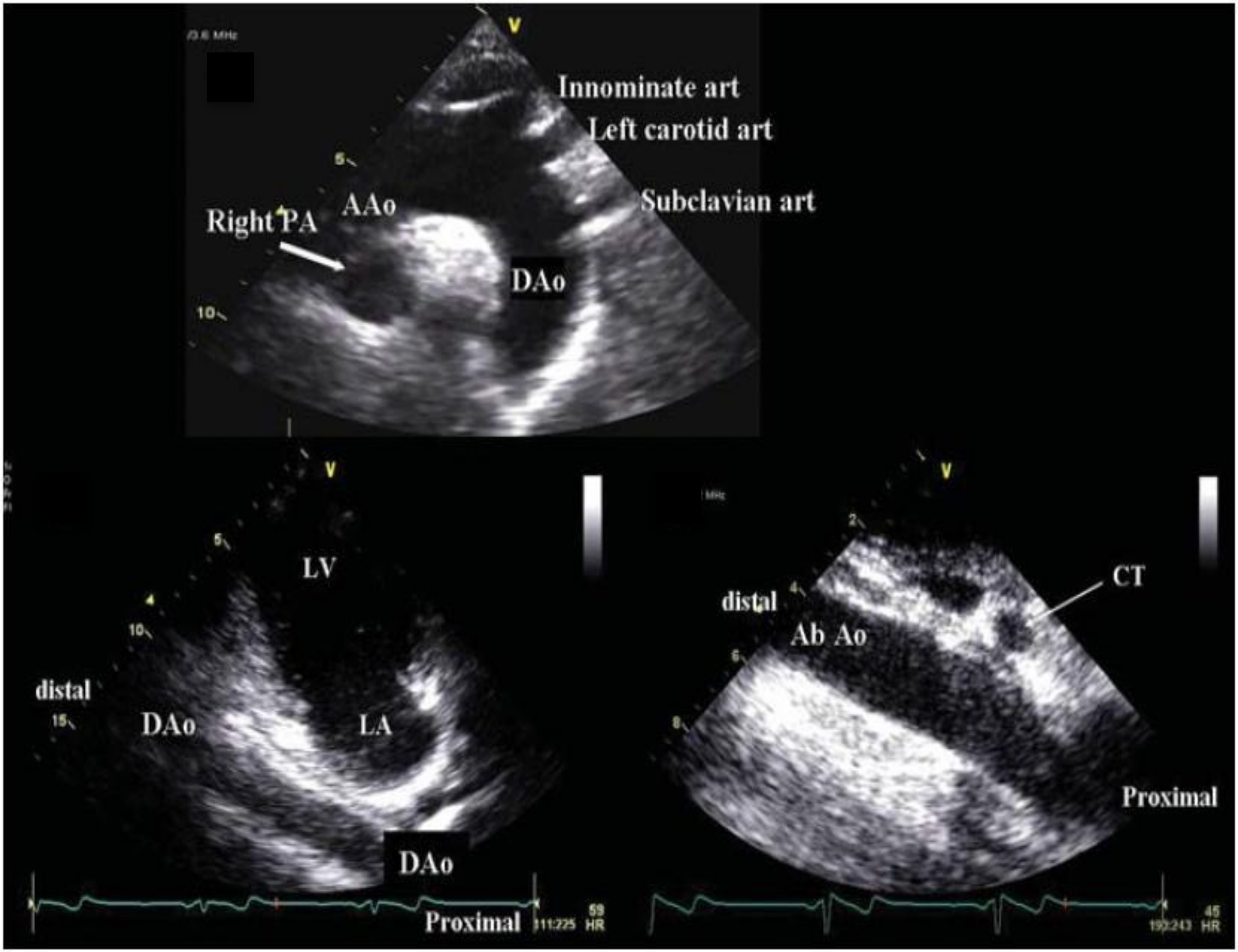
Innominate art
Left carotid art
Subclavian art
Right PA
AAo
DAo
LV
distal
DAo
LA
DAo
Proximal
CT
distal
Ab Ao
Proximal

TEE

- The aorta can be visualized from the annulus through the ascending and arch portions and the descending thoracic aorta to the level of the gastroesophageal junction
- Has several advantages:

1-Proximity of the oesophagus and the thoracic aorta permits high resolution images.

2- Availability of multiplane imaging permits improved incremental assessment of the aorta from its root to the descending aorta.

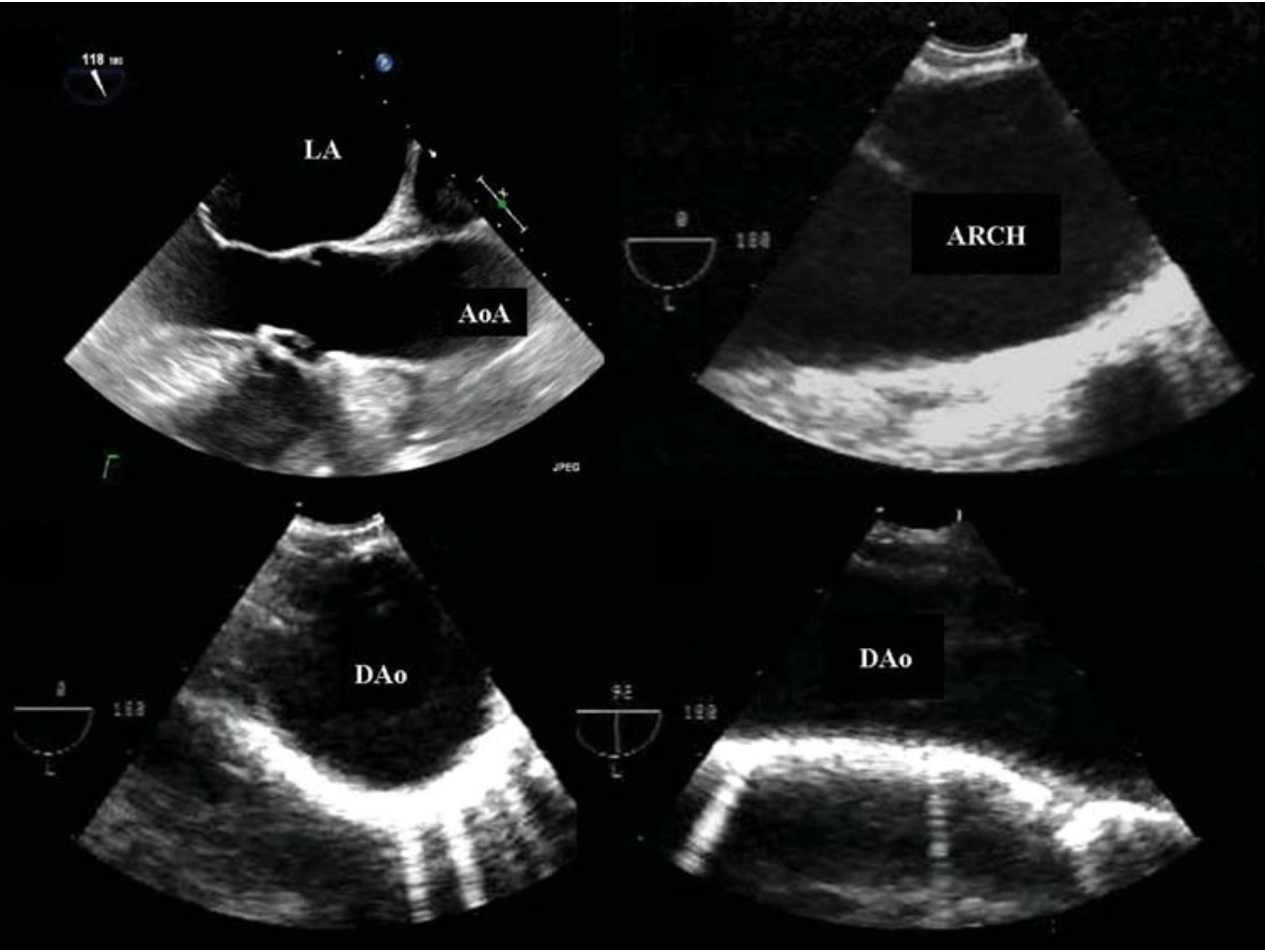
LA
AoA
ARCH
DAo
DAo

A short segment of the distal ascending aorta, just before the innominate artery, remains unvisualized owing to interposition of the right bronchus and trachea (blind spot)!!!

TEE views of innominate and left carotid are usually suboptimal

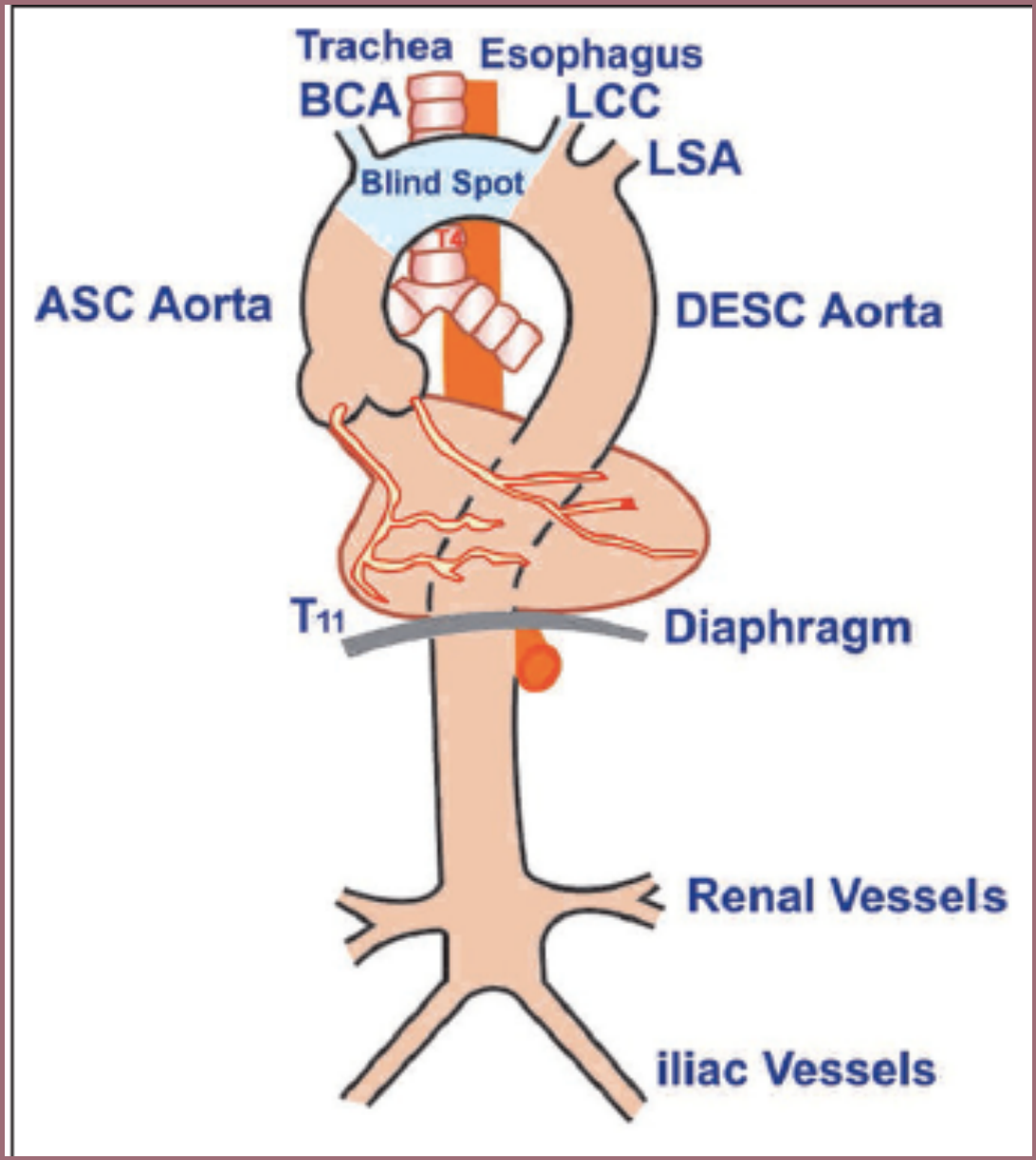

Annals of Cardiac Anaesthesia | October 2016 | Vol 19 | Special Issue 1

Aortic dissection

- Clinical presentation can be identical to other conditions in (Acute Aortic Syndrome).
- Typically in the setting of aortic dilatation.
- 40% in aortas smaller than 5 cm!
- Usually there is more than one communication point between true and false lumen.
- Classically begins at the ligamentum arteriosum or Ascending Ao.

Classification of aortic dissection

	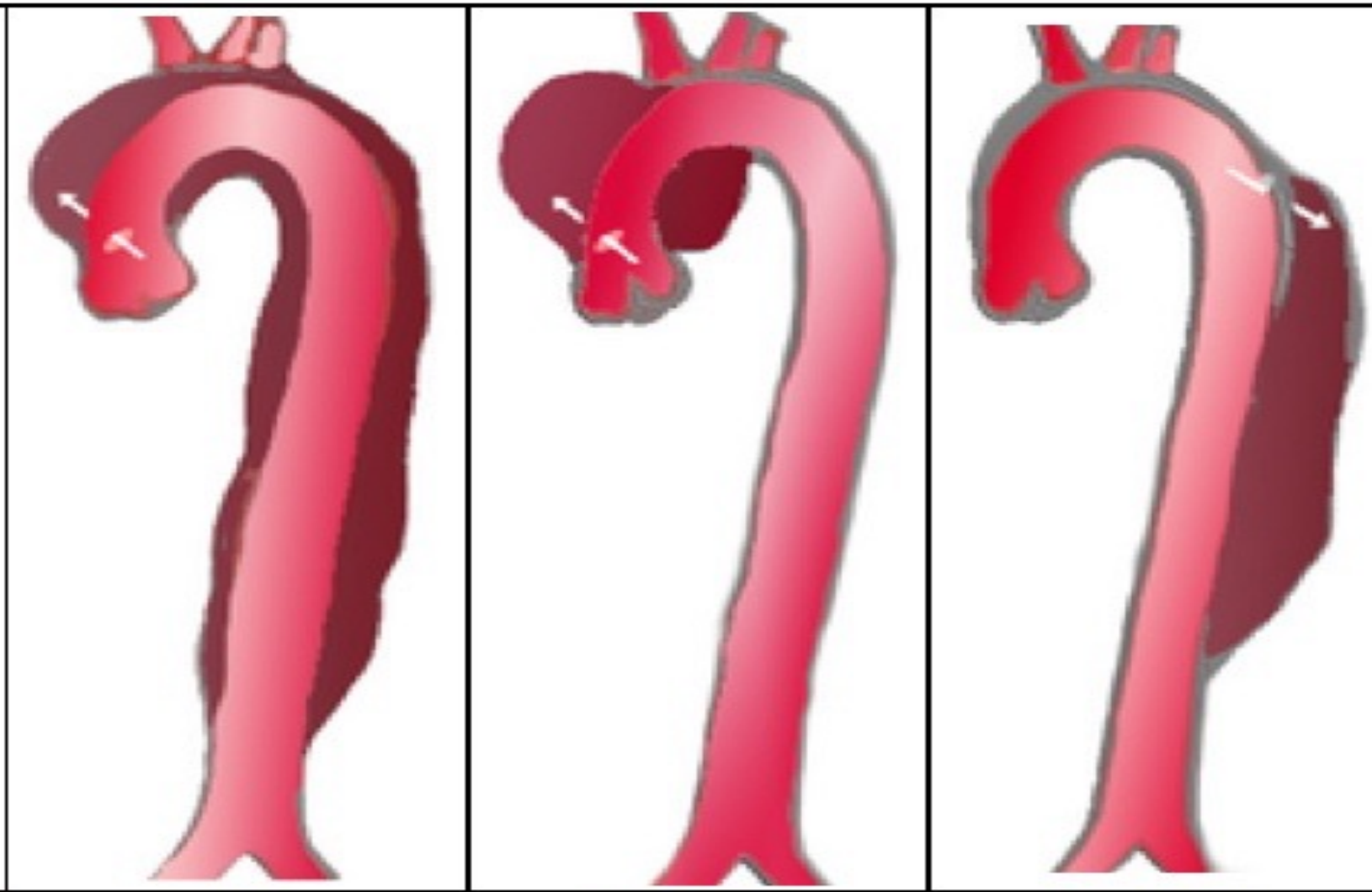		
Percentage	60%	10–15%	25–30%
Type	DeBakey I	DeBakey II	DeBakey III
	Stanford A (Proximal)		Stanford B (Distal)

Echo Assessment in Aortic Dissection

Identify presence of a dissection flap	Flap dividing two lumens
Define extension of aortic dissection	Extension of the flap and true/false lumens in the aortic root(ascending/arch/descending abdominal aorta)
Identify true lumen	Systolic expansion, diastolic collapse, systolic jet directed away from the lumen, absence of spontaneous contrast, forward systolic flow)
Identify false lumen	Diastolic diameter increase, spontaneous contrast and or thrombus formation, reverse/delayed or absent flow
Identify presence of false luminal thrombosis	Mass separated from the intimal flap and aortic wall inside the false lumen
Localize entry tear	Disruption of the flap continuity with fluttering or ruptured intimal borders; color Doppler shows flow through the tear
Assess presence, severity and mechanisms of AR	Anatomic definition of the valve (bicuspid, degenerated, normal with/without prolapse of one cusp); dilation of different segments of the aorta; flap invagination into the valve; severity by classic echocardiographic criteria
Assess coronary artery involvement	Flap invaginated into the coronary ostium; flap obstructing the ostium; absence of coronary flow; new regional wall motion abnormalities
Assess side-branch involvement	Flap invaginated into the aortic branches
Detect pericardial and/or pleural effusion	Echo-free space in the pericardium/pleura
Detect signs of cardiac tamponade	Classic echocardiographic and Doppler signs of tamponade

Journal of the American Society of Echocardiography
Volume 28 Number 2

True vs False Lumen : Key findings

	True lumen	False lumen
Size	True < false	Most often: false > true lumen
Pulsation	Systolic expansion	Systolic compression
Flow direction	Systolic antegrade flow	Systolic antegrade flow reduced or absent, or retrograde flow
Communication flow	From true to false lumen in systole	
Contrast echo flow	Early and fast	Delayed and slow

TTE views of massive aortic dilation and dissection

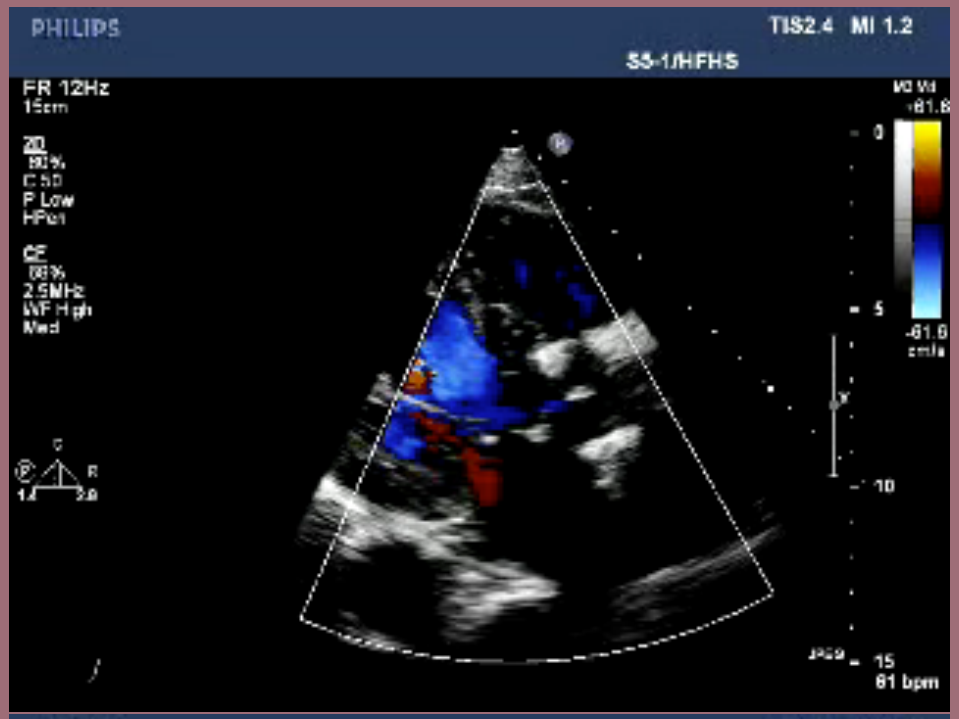

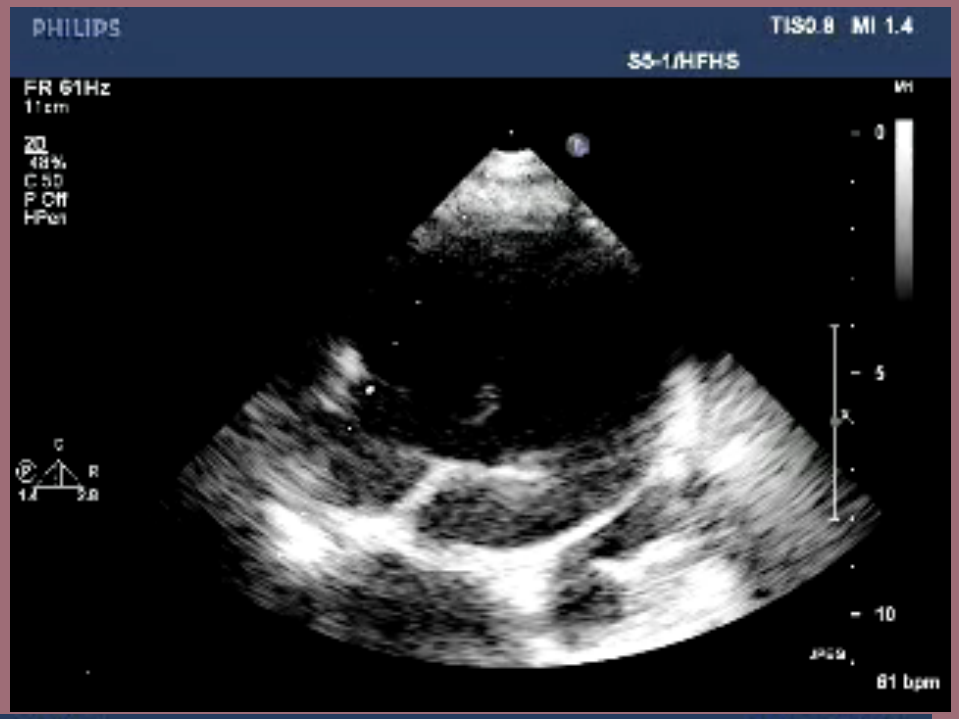

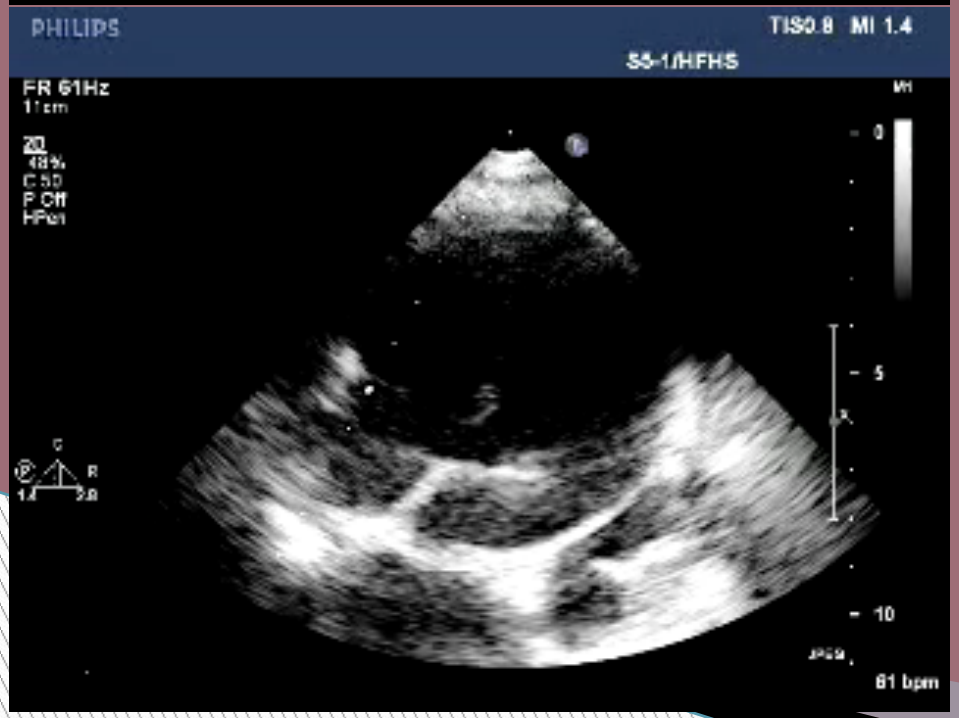

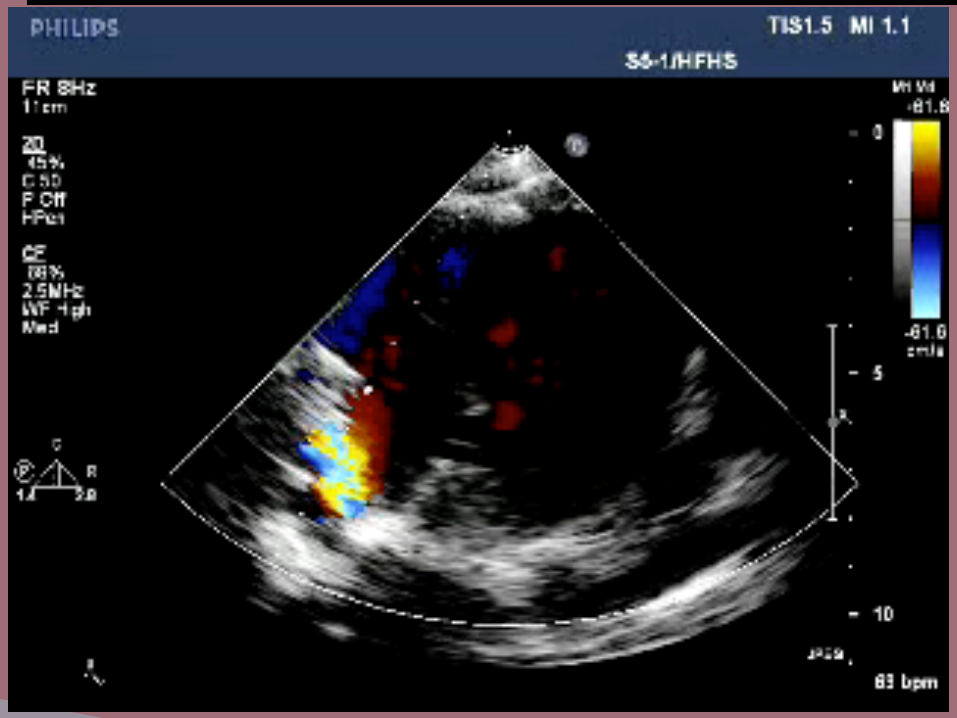

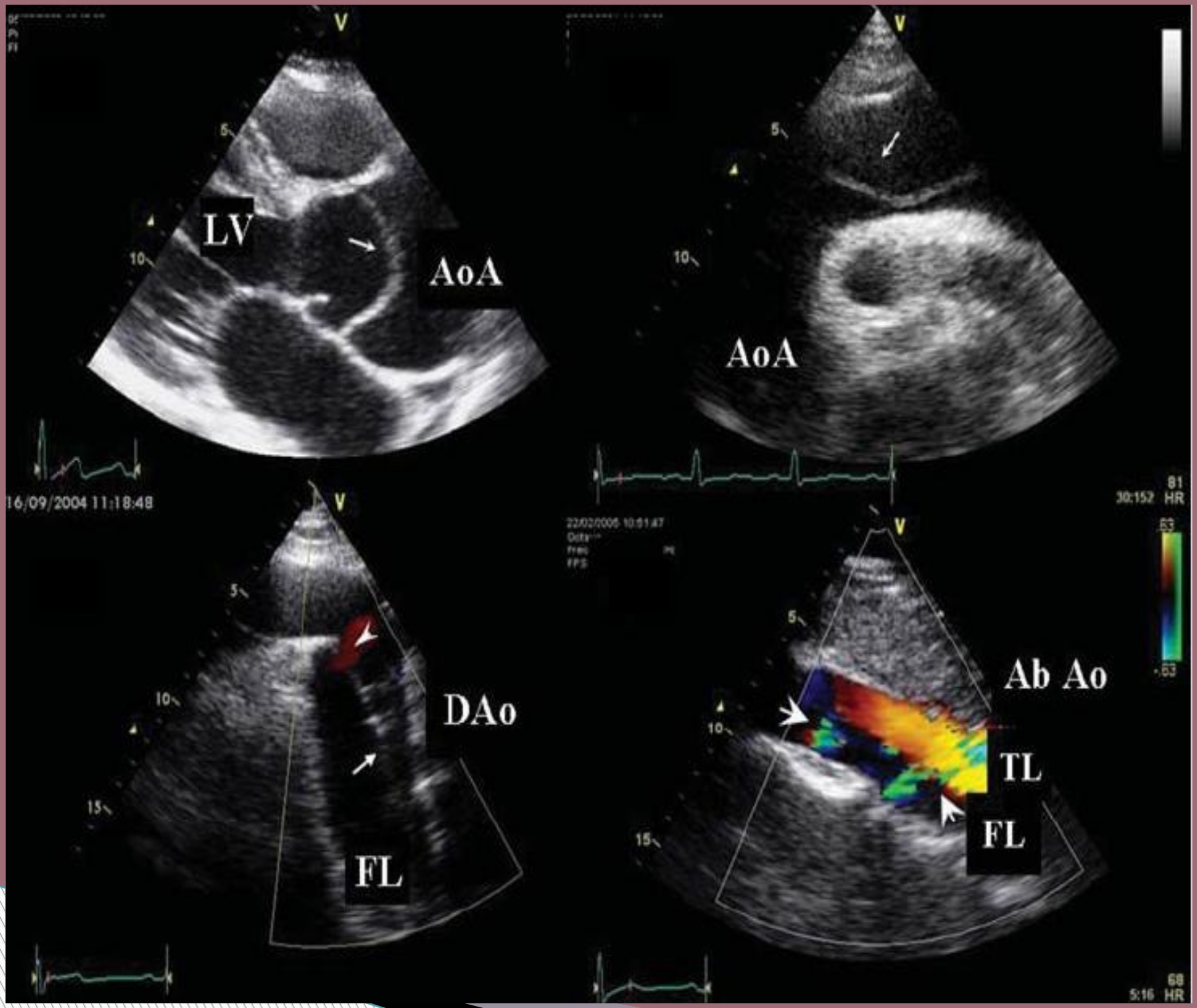
LV
AoA
AoA
16/09/2004 11:18:48
DAo
FL
Ab Ao
TL
FL

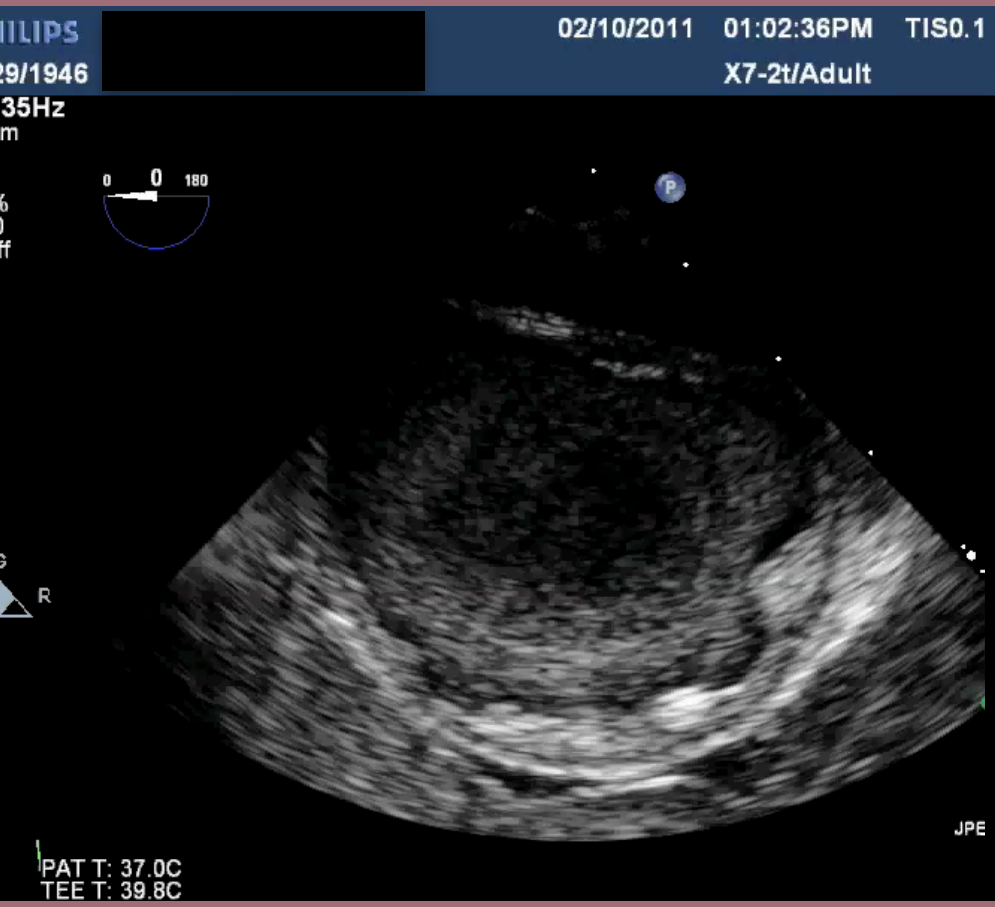
ILIPS
29/1946
02/10/2011 01:02:36PM TIS0.1
X7-2t/Adult
35Hz
m
0 0 180
G
R
JPE
PAT T: 37.0C
TEE T: 39.8C

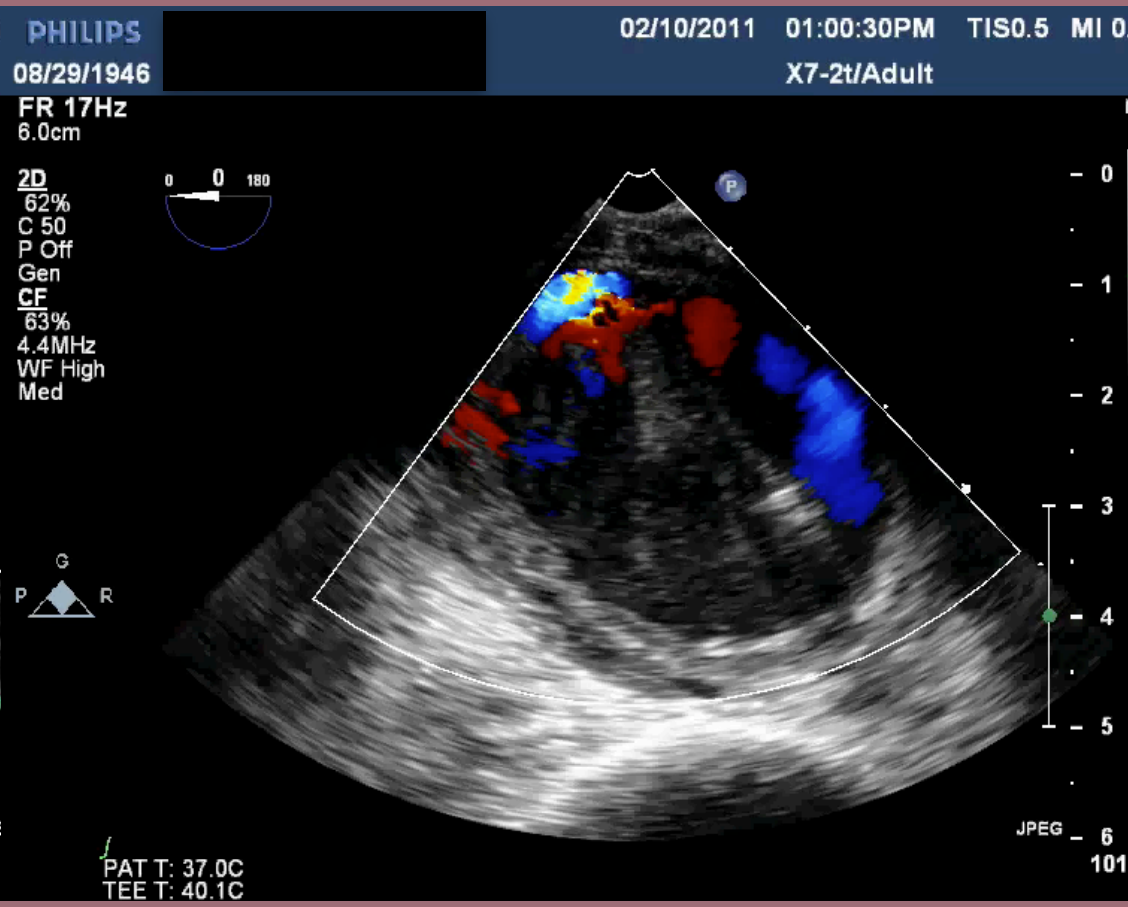
PHILIPS
08/29/1946
02/10/2011 01:00:30PM TIS0.5 MI 0
X7-2t/Adult
FR 17Hz
6.0cm
2D
62%
C 50
P Off
Gen
CF
63%
4.4MHz
WF High
Med
0 0 180
G
P R
0
1
2
3
4
5
6
JPEG
101
PAT T: 37.0C
TEE T: 40.1C

Aortic Dissection Complications

- Rupture
- Tamponade
- Aortic regurgitation
- Coronary artery involvement
- Other branch vessel involvement

Mechanisms of Aortic Regurgitation in Dissection Echo Insights

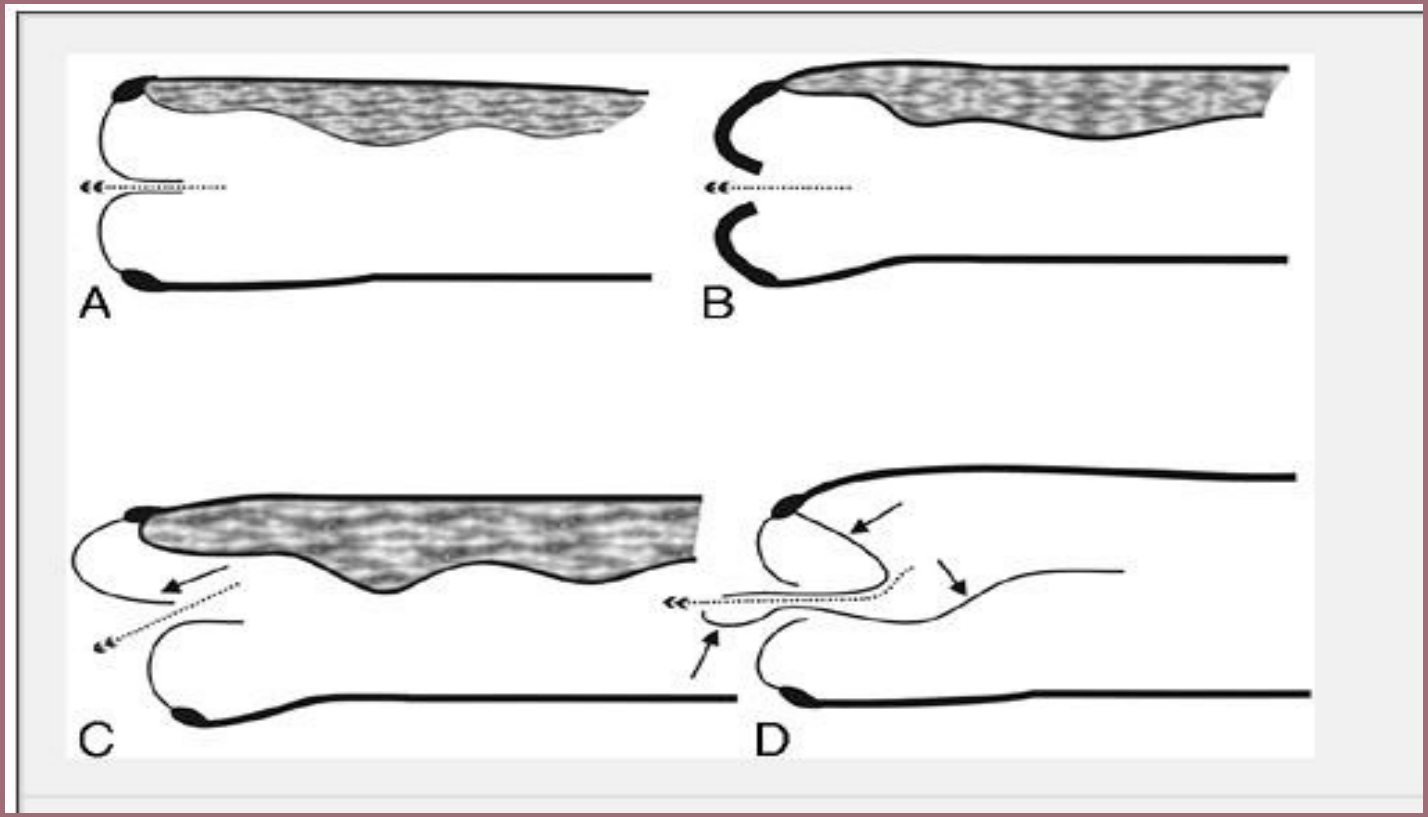

(A) effacement of dilation of the sinotubular junction resulting in malcoaptation of the aortic valve
(B) intrinsic aortic valve disease
(C) disruption of the insertion of an aortic cusp
(D) prolapse of a portion of the intimal dissection flap through the aortic valve, which serves as a conduit for aortic regurgitation (D).

Coronary Artery Involvement on TEE with AD

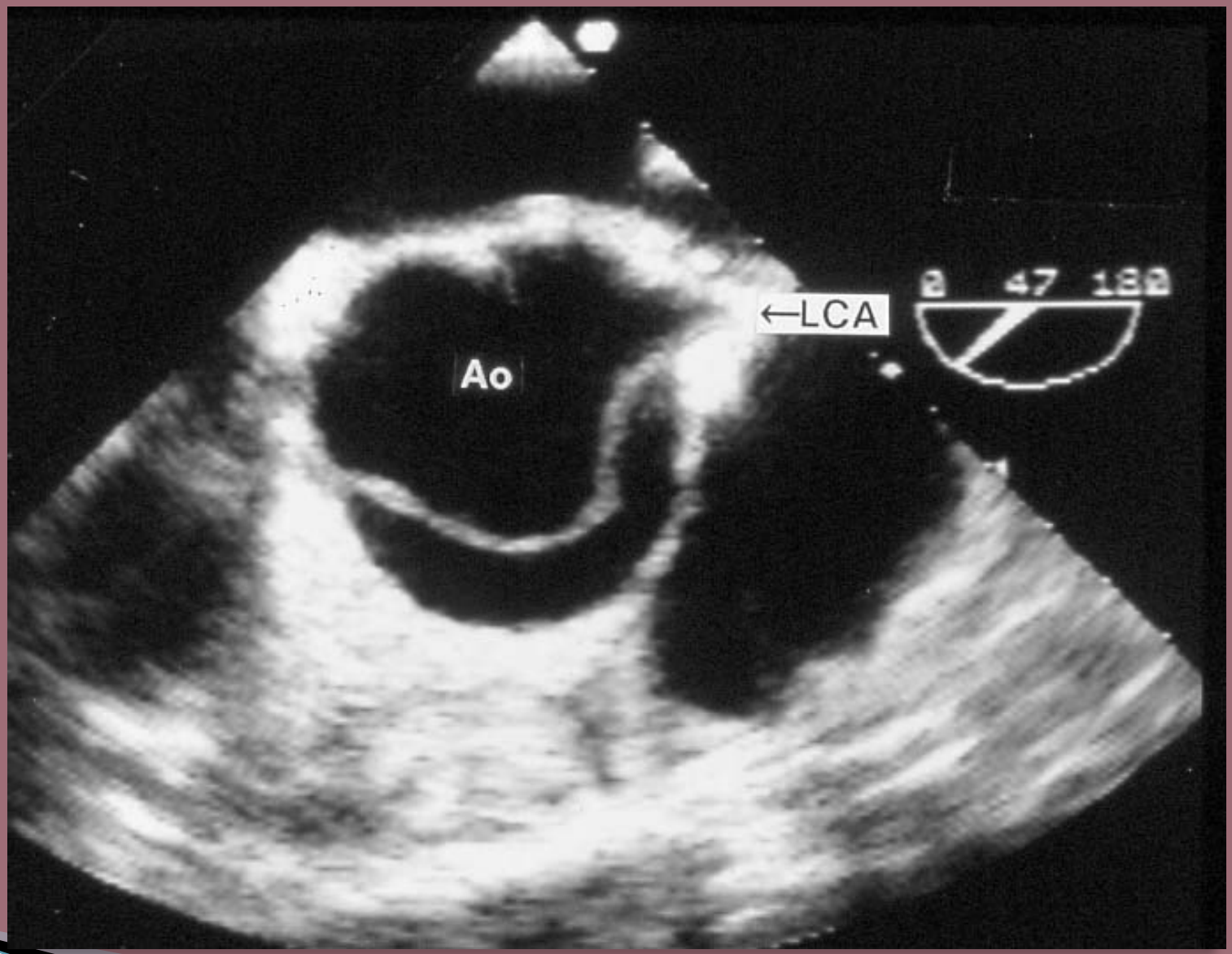

Comparison of Imaging Modalities for Imaging Aortic Dissection

n=1139, MGH database

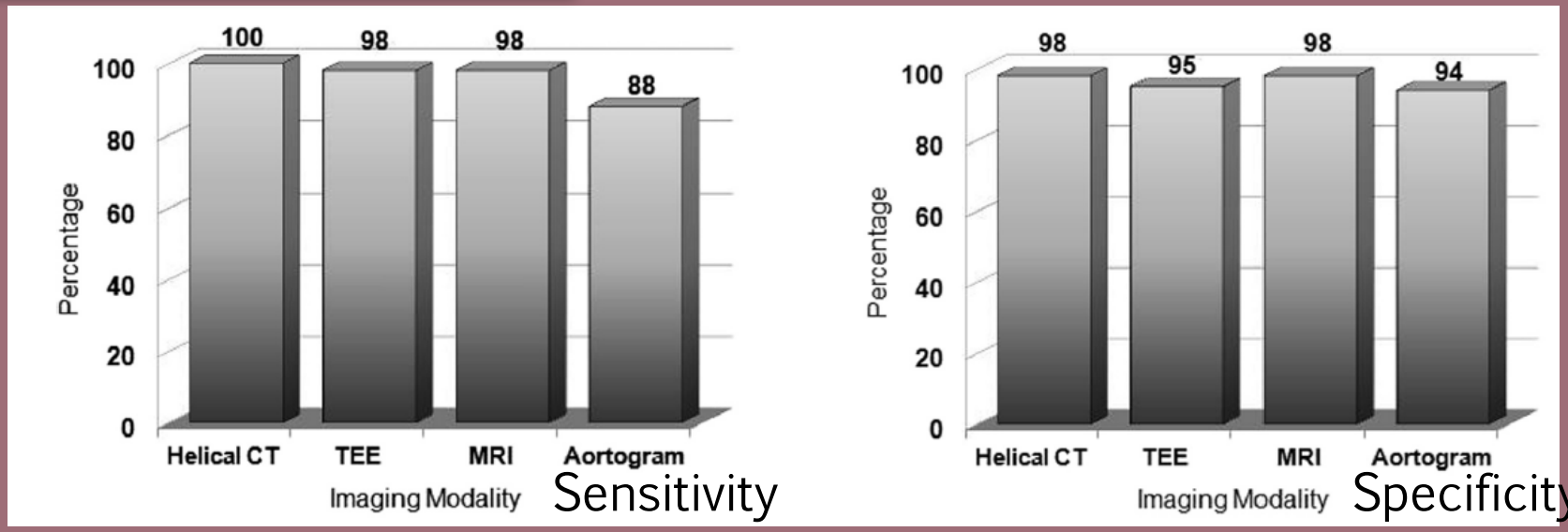

IRAD registry

real world

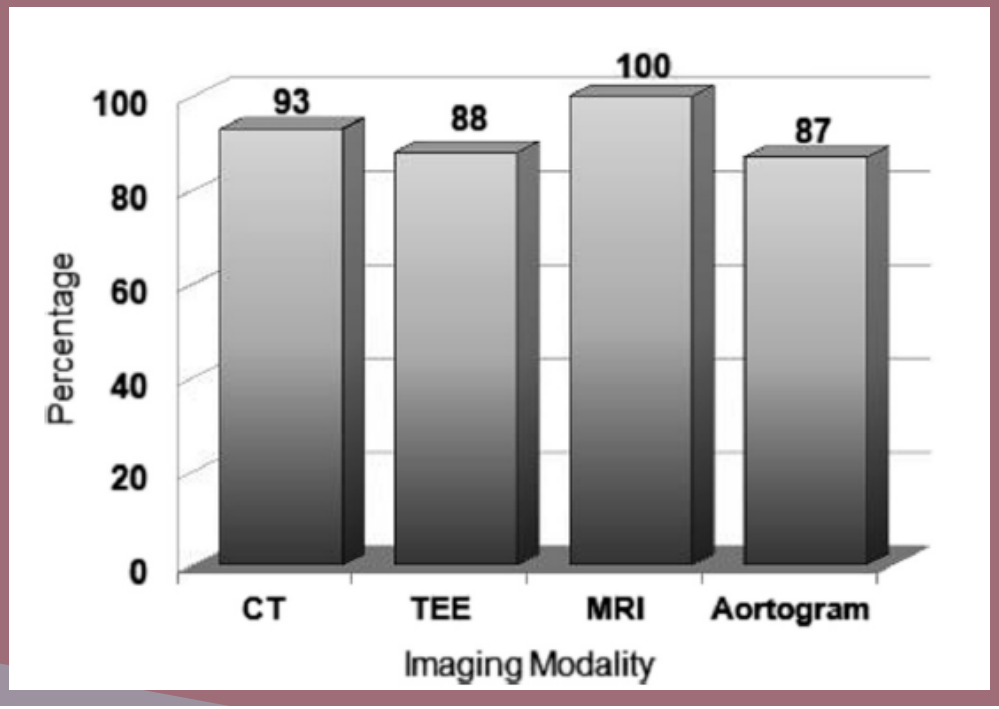

Comparative Strengths of Modalities for Acute Aortic Syndrome

Advantages of modality	CTA	TTE	TEE	MRA	Angiography
Readily available	+++	+++	++	+	+
Quickly performed	+++	+++	++	+	+
Performed at bedside	–	+++	+++	–	–
Noninvasive	+++	+++	+	+++	–
No iodinated contrast	–	+++	+++	+++	–
No ionizing radiation	–	+++	+++	+++	–
Cost	++	+	++	++	+++

Diagnostic performance	CTA	TTE	TEE	MRA	Angiography
Sensitivity	+++	++	+++	+++	++
Specificity	+++	++	+++	+++	+++
Ability to detect IMH	+++	+	++	+++	–
Site of intimal tear	+++	–	++	+++	++
Presence of AR	–	+++	+++	++	+++
Coronary artery involvement	+	–	++	+	+++
Presence of pericardial effusion	++	+++	+++	++	–
Branch vessel involvement	++	–	+	++	+++

Ciggarora et al
Isselbacher et al

All that Glitters in Not A Flap on Echo

- Not every line in the Aorta is dissection!
- Reverberation artifacts are very common in the Aorta (40%).
- Usually from the posterior wall of the ascending aorta or the posterior wall of the right pulmonary artery.
- Clues to differentiate:

1- Color Doppler

2- moving in parallel with the reverberating structures

3-Double the distance from the probe

Pseudo Dissection Flaps

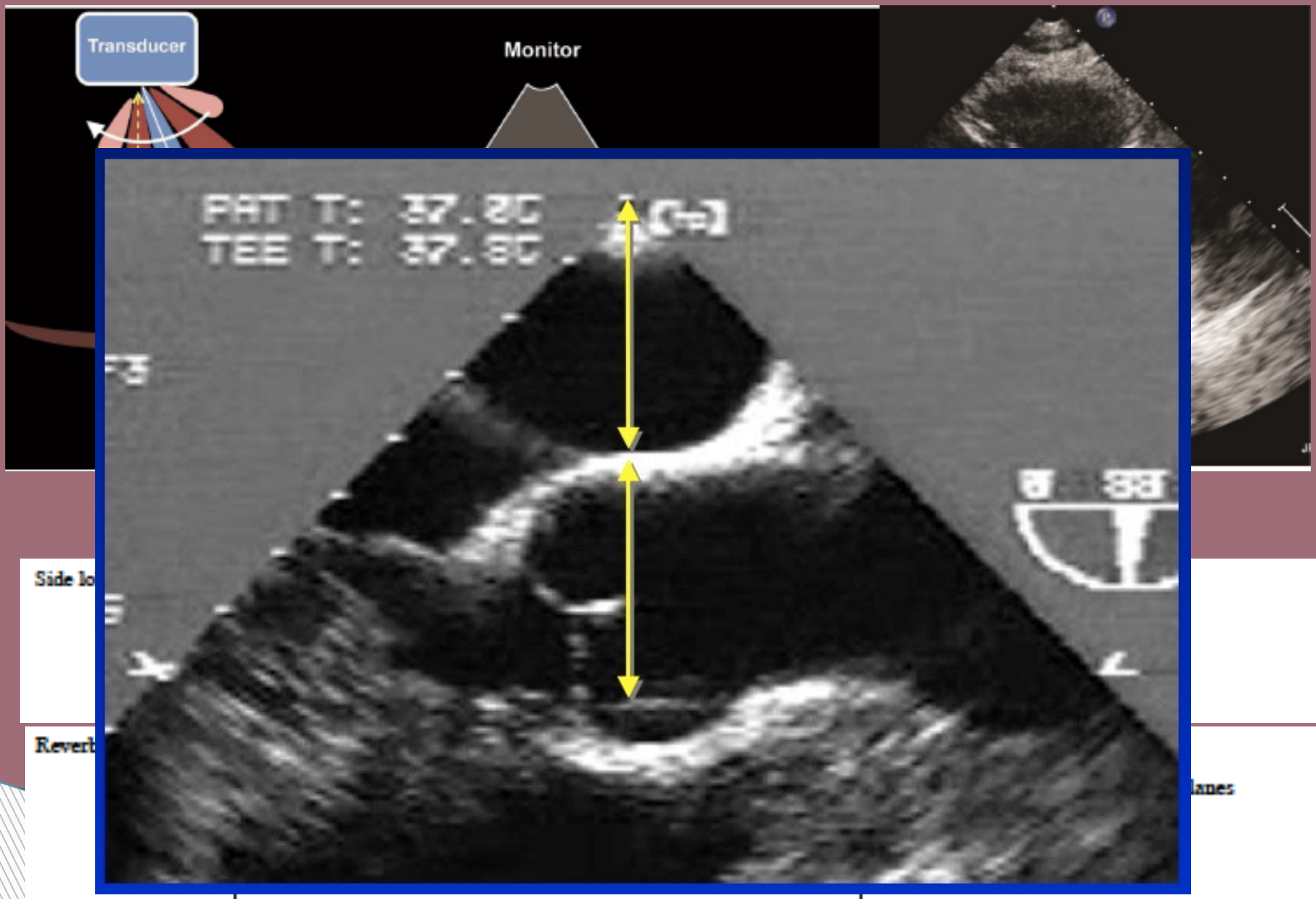

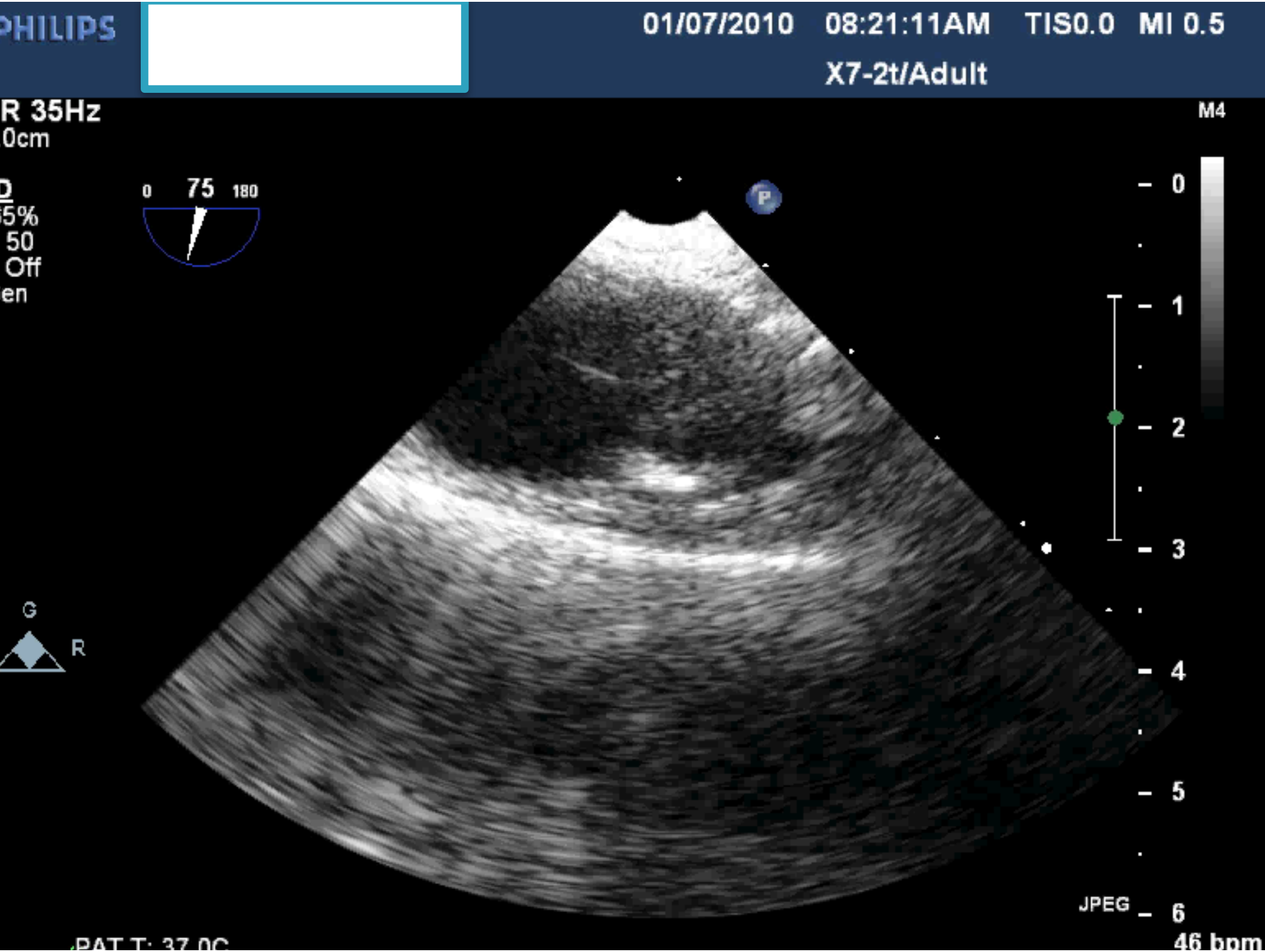
PHILIPS
01/07/2010 08:21:11AM TIS0.0 MI 0.5
X7-2t/Adult
R 35Hz
0cm
D
5%
50
Off
en
0 75 180
M4
0
1
2
3
4
5
6
G
R
JPEG
46 bpm

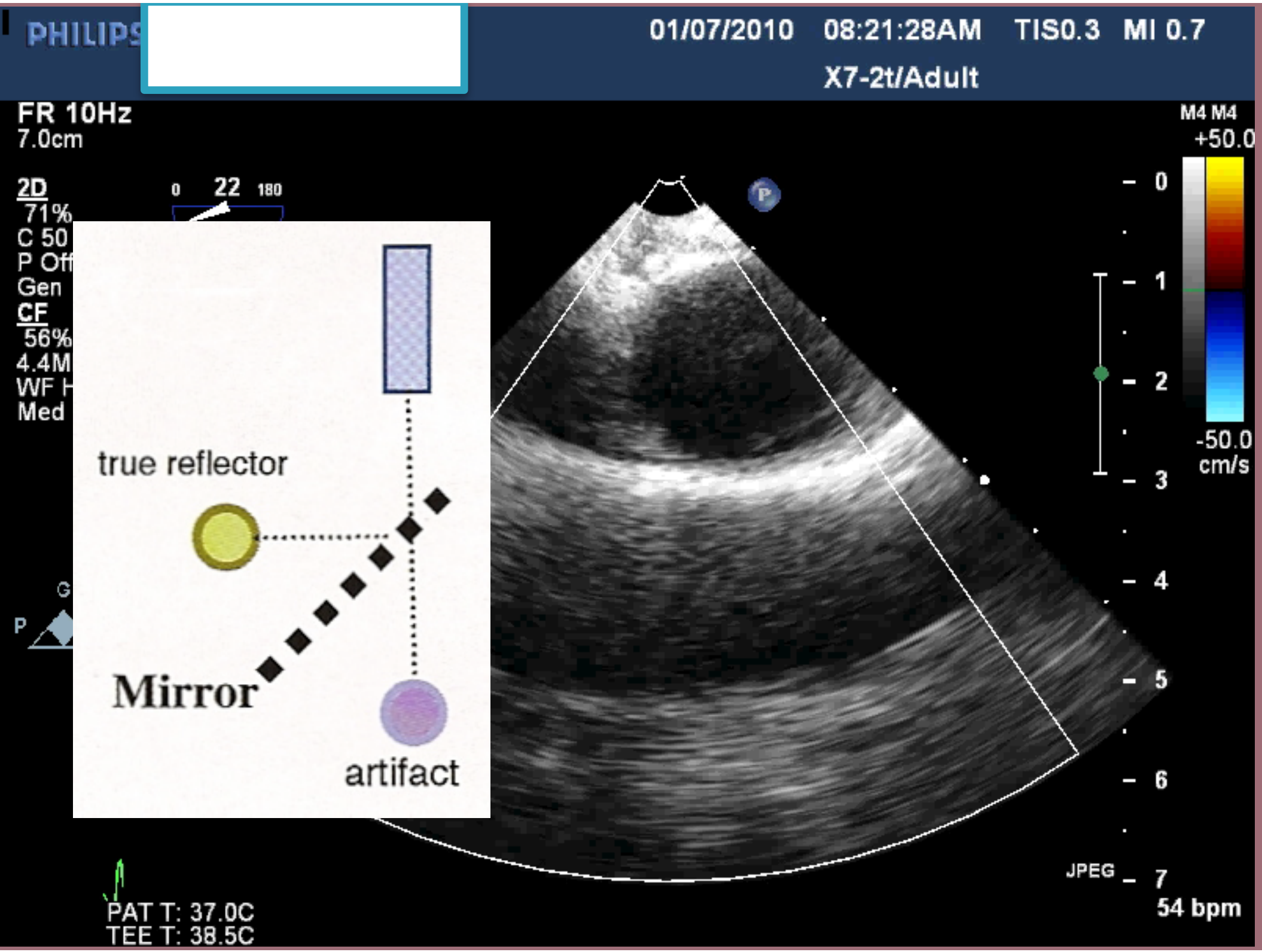
PHILIPS
01/07/2010 08:21:28AM TIS0.3 MI 0.7
X7-2t/Adult
FR 10Hz
7.0cm
2D
71%
C 50
P Off
Gen
CF
56%
4.4M
WF H
Med
0 22 180
M4 M4
+50.0
-50.0
cm/s
0
1
2
3
4
5
6
7
JPEG
54 bpm
PAT T: 37.0C
TEE T: 38.5C
true reflector
Mirror
artifact

Intra Mural Hematoma (IMH)

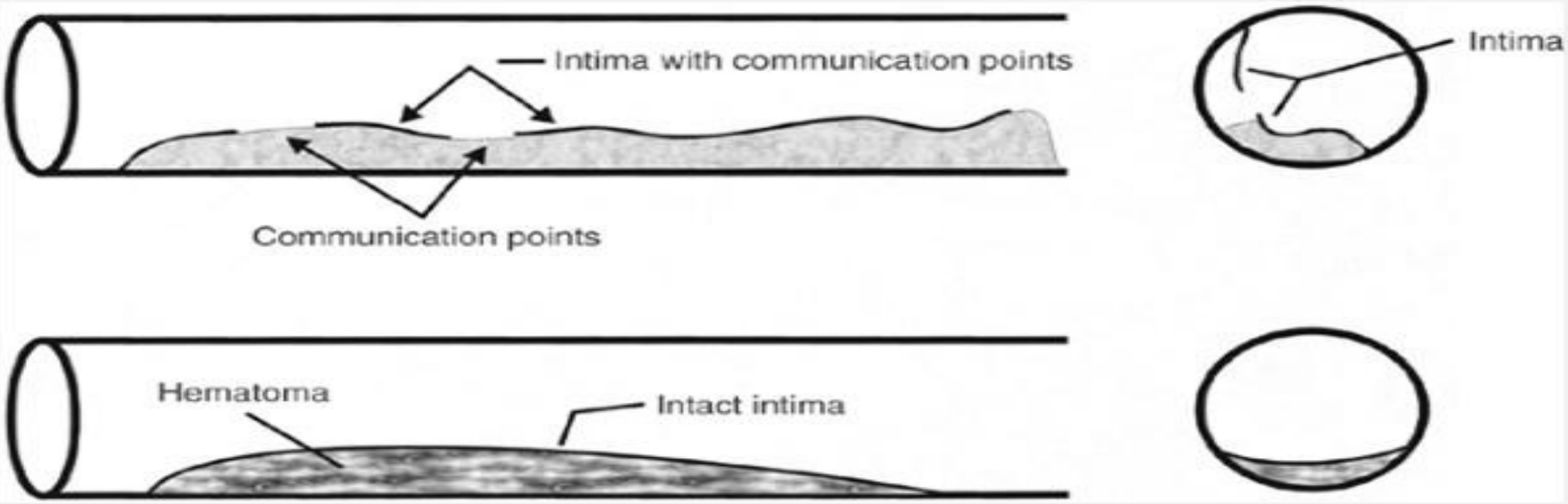

-Variant of Aortic dissection, usually result from rupture of vasa vasorum, resulting in hematoma in the medial space BUT no communication with the Lumen.

-16% will progress to AD.

-Clinical presentation, prognosis and treatment is the same as AD.

Intra Mural Hematoma (IMH)

Localized thickening of aortic wall
- Usually crescentic
- Occasionally circumferential
- Echo-lucent spaces common

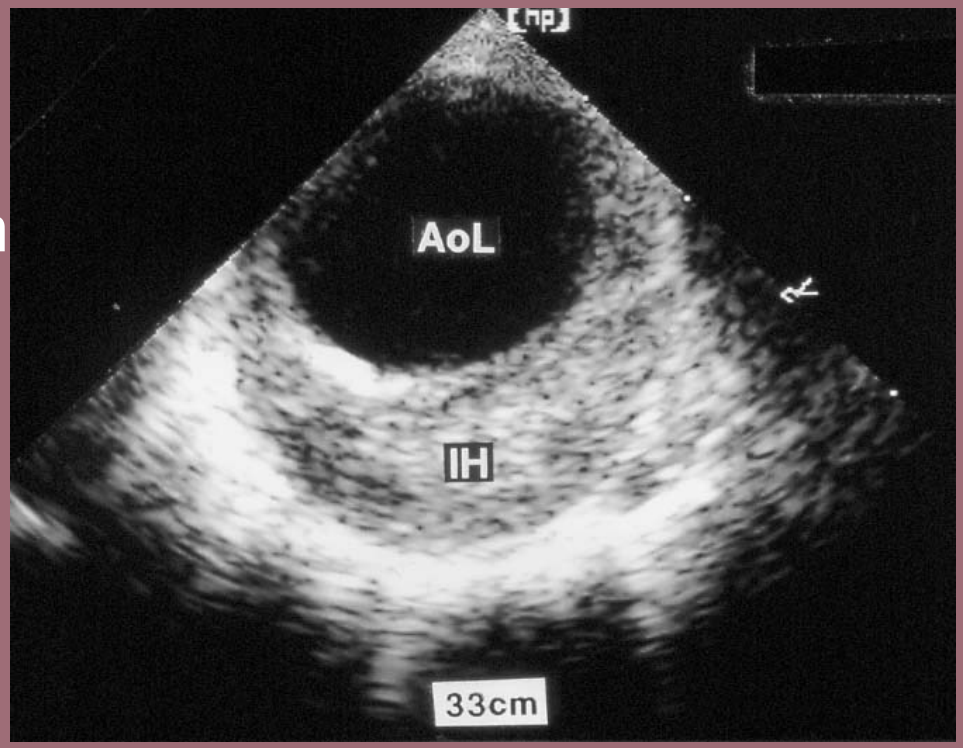

Relatively smooth luminal surface

Absence of dissection flap

Maintenance of circular lumen

Marfan Syndrome

- It usually begins with dilatation of the aortic sinuses which progresses into the s
ultimately into the aortic a

- Compared with atheroscle
aortic aneurysms in Marfar
in younger patients and er

- Main mechanism for AI is

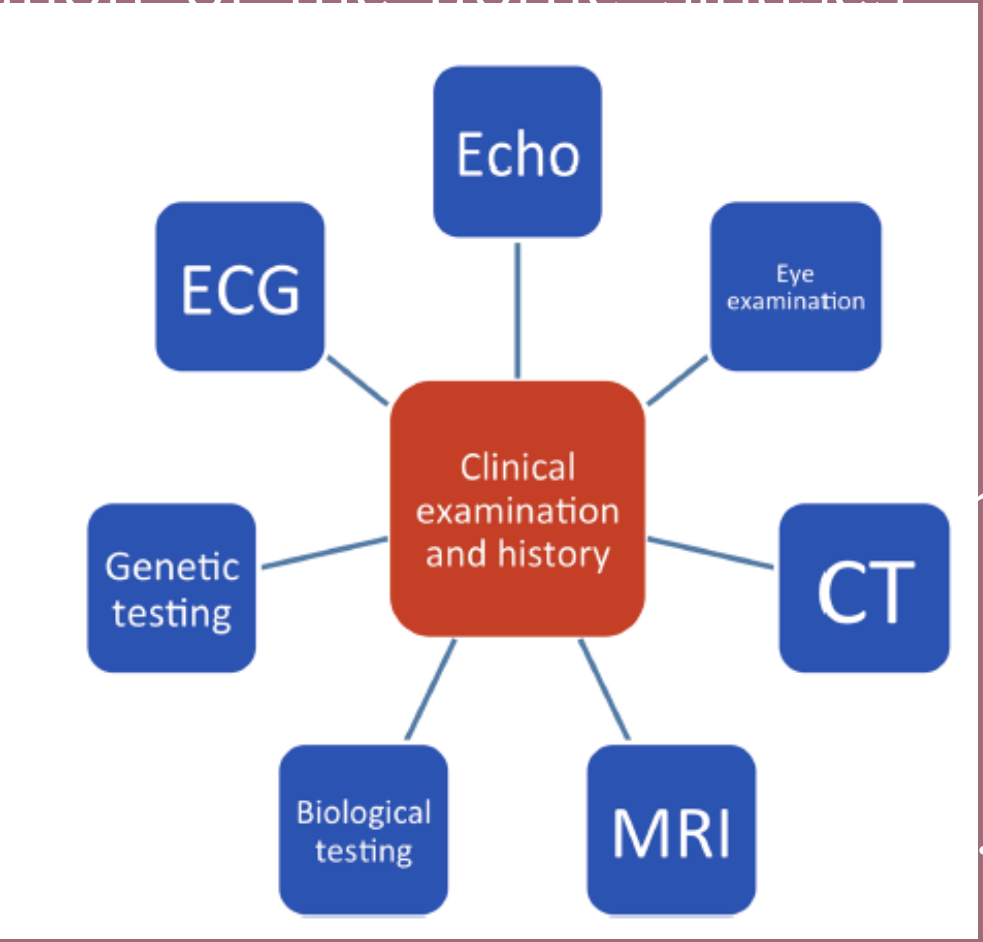

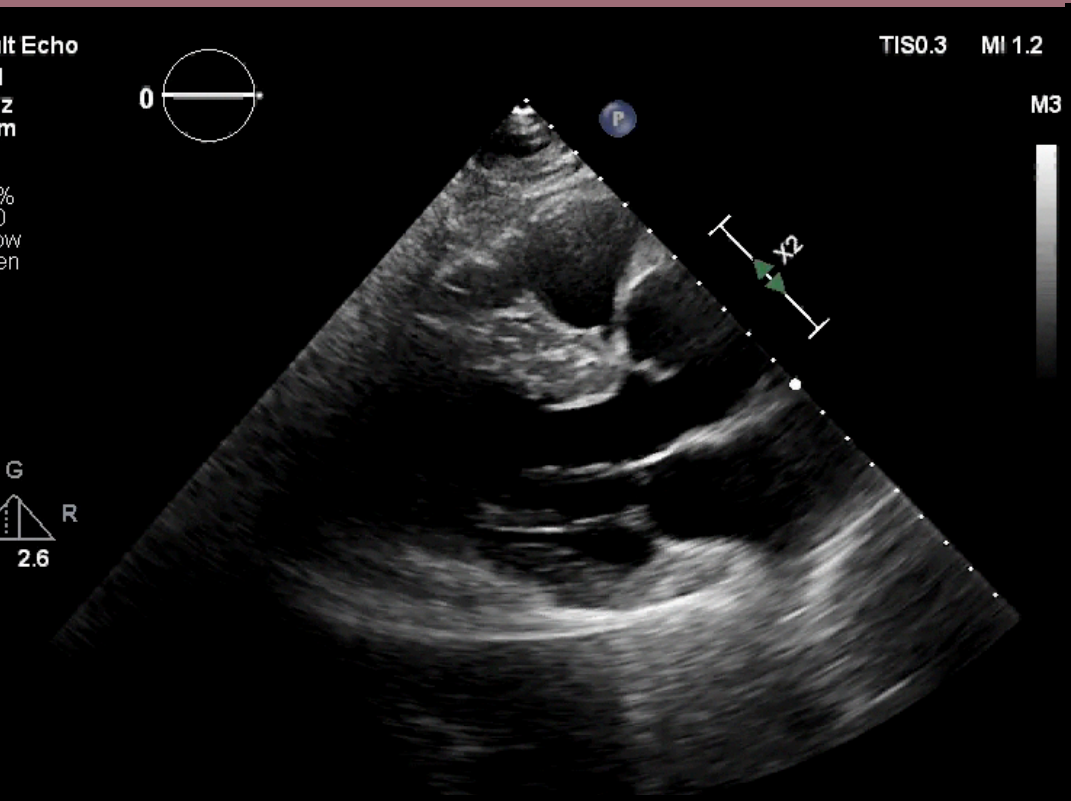
TIS0.3 MI 1.2
M3
X2
G
R
2.6

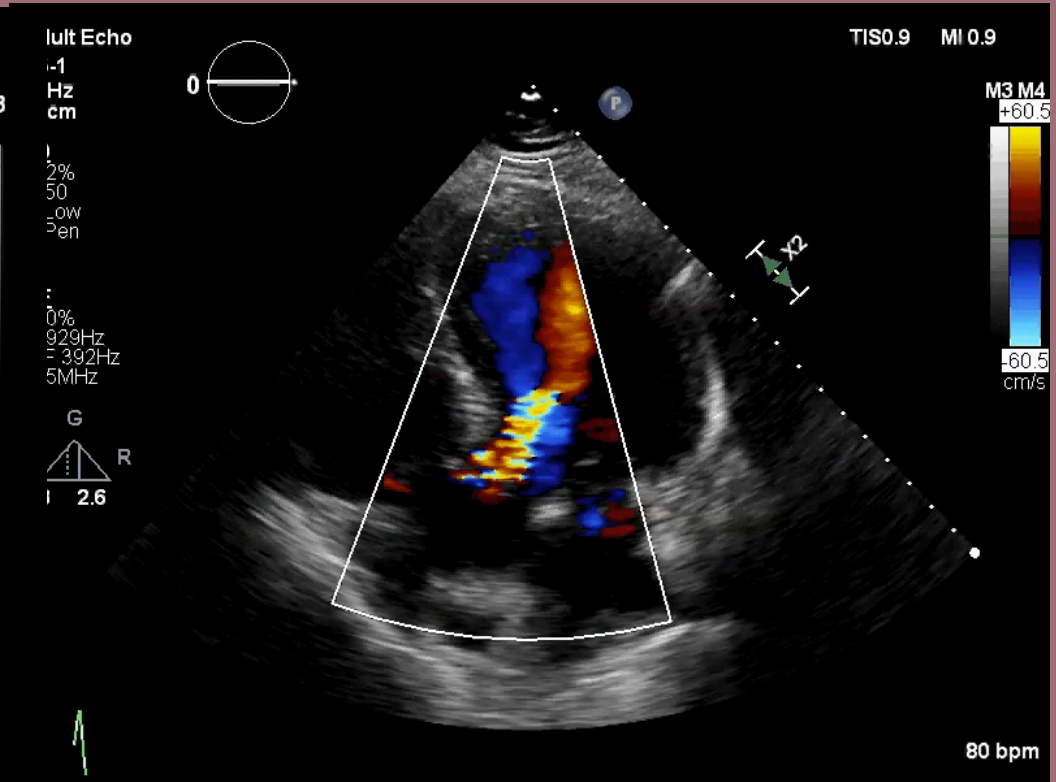
TIS0.9 MI 0.9
M3 M4
+60.5
-60.5
cm/s
X2
G
R
2.6
80 bpm

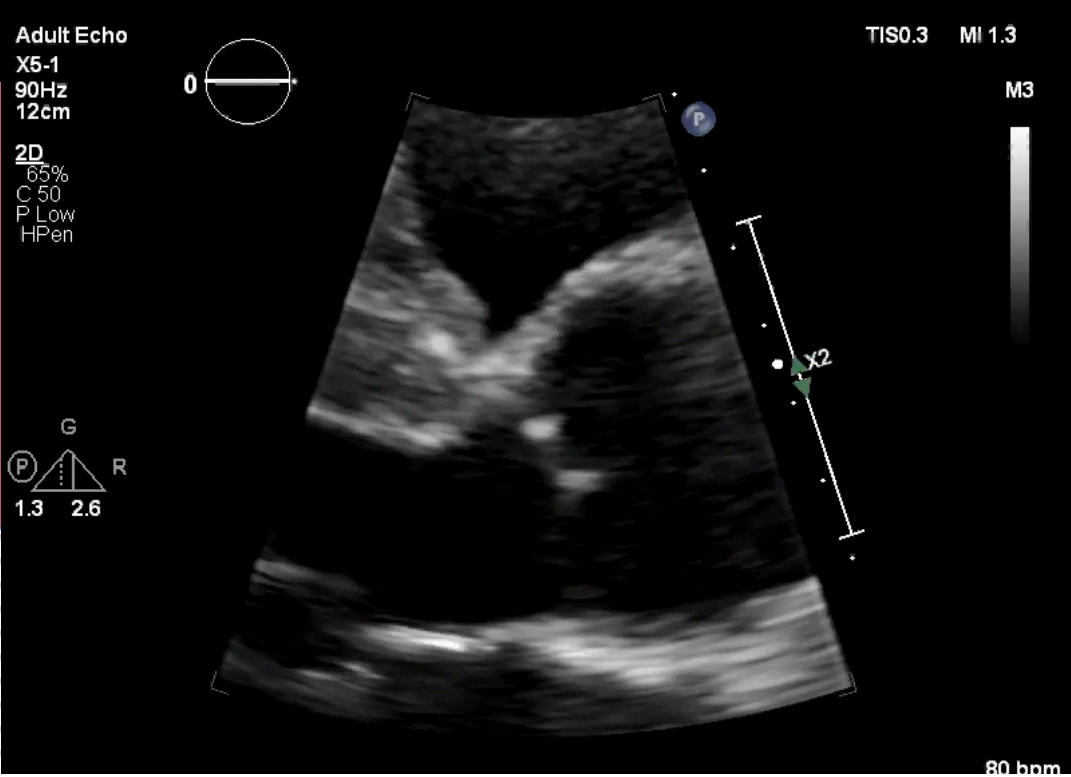
Adult Echo
X5-1
90Hz
12cm
2D
65%
C 50
P Low
HPen
TIS0.3 MI 1.3
M3
X2
G
R
1.3 2.6
80 bpm

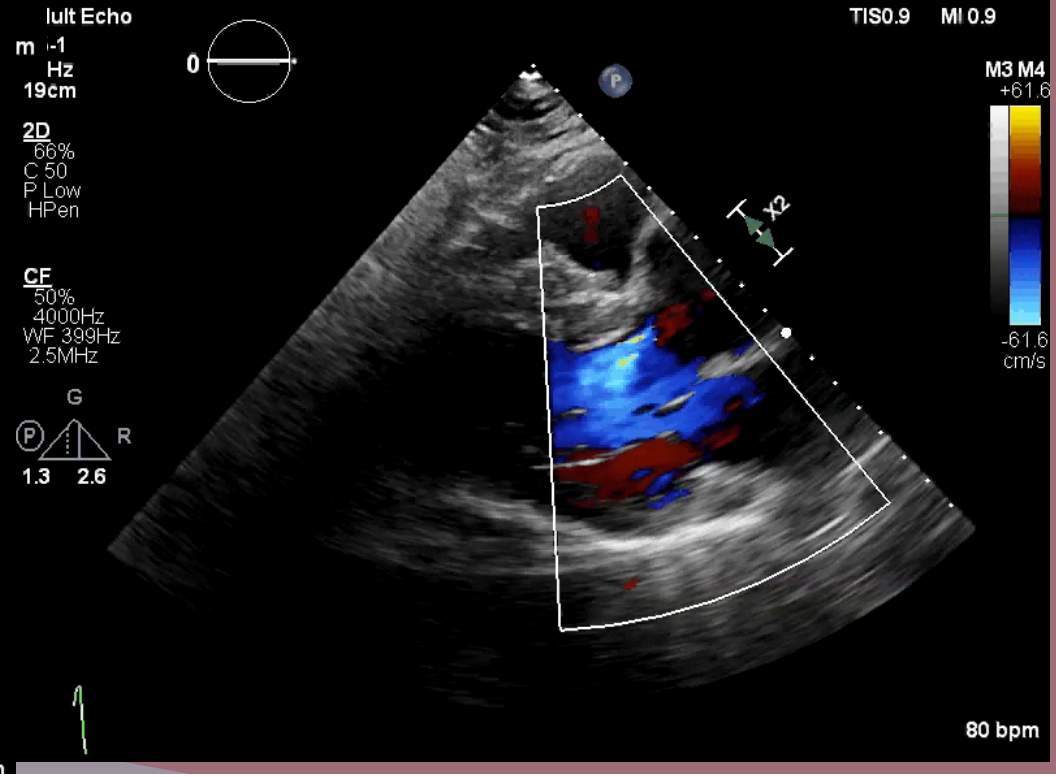
2D
66%
C 50
P Low
HPen
CF
50%
4000Hz
WF 399Hz
2.5MHz
TIS0.9 MI 0.9
M3 M4
+61.6
-61.6
cm/s
X2
G
R
1.3 2.6
80 bpm

Marfan Syndrome Aorta Surveillance

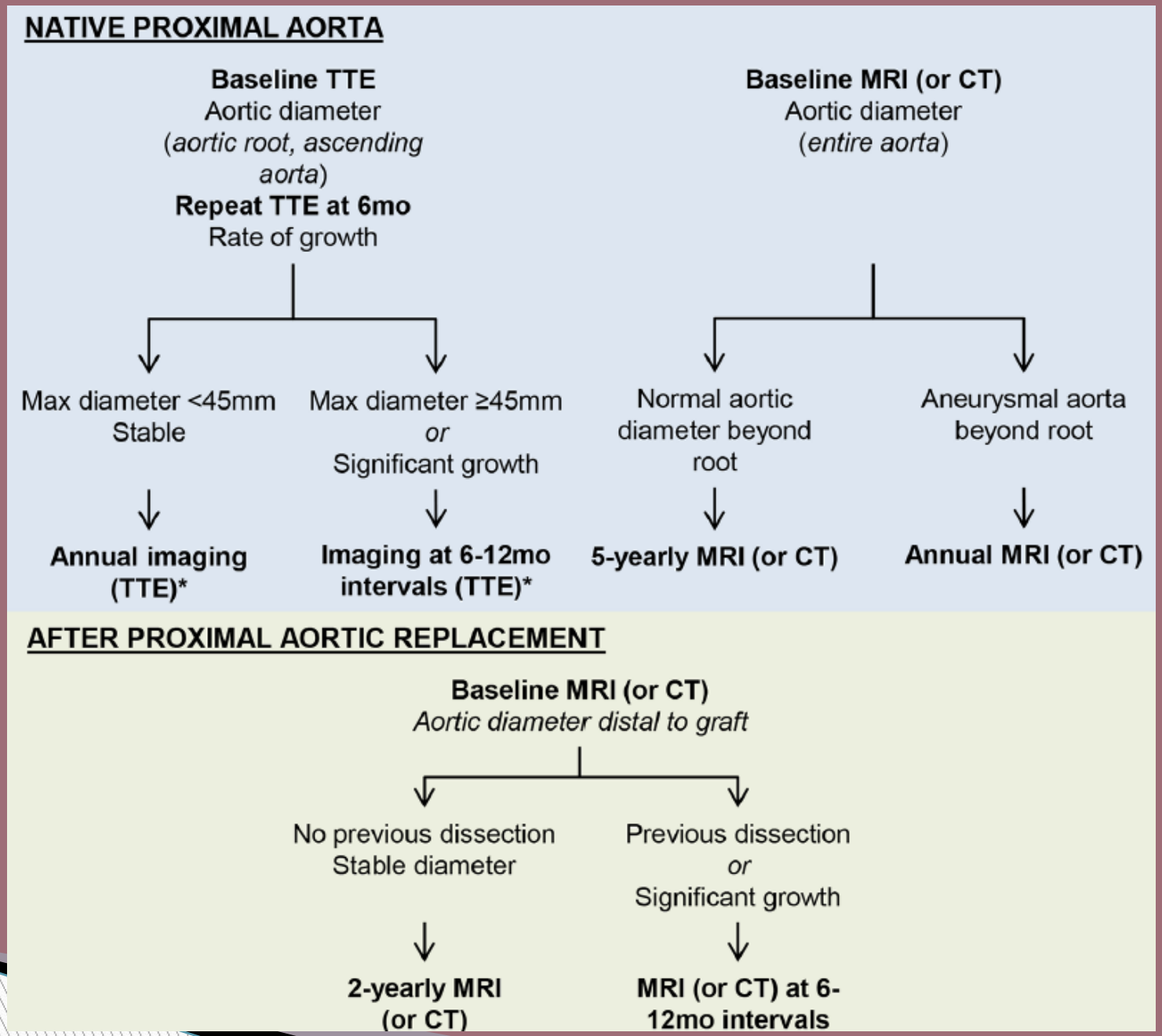

Loeys-Dietz Syndrome

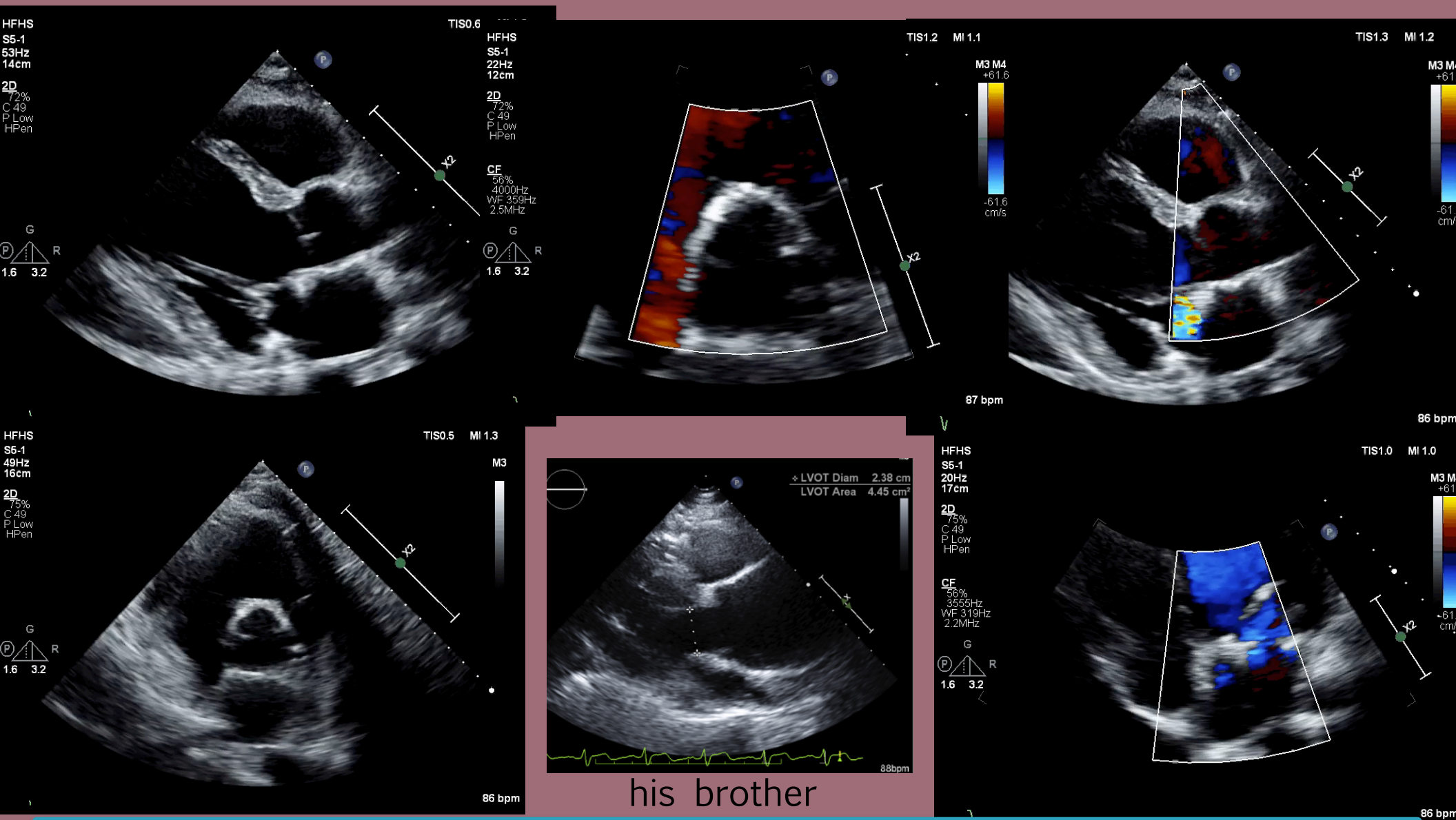

27 year old male with Loeys Dietz Syndrome, SMADD3 mutation and severe MVPS MR s/p MV replacement for followup for MR

MRI surveillance

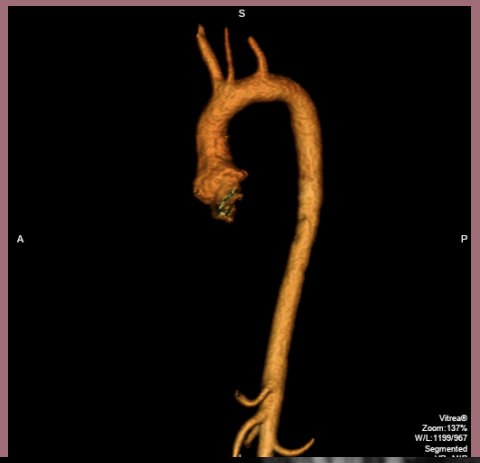

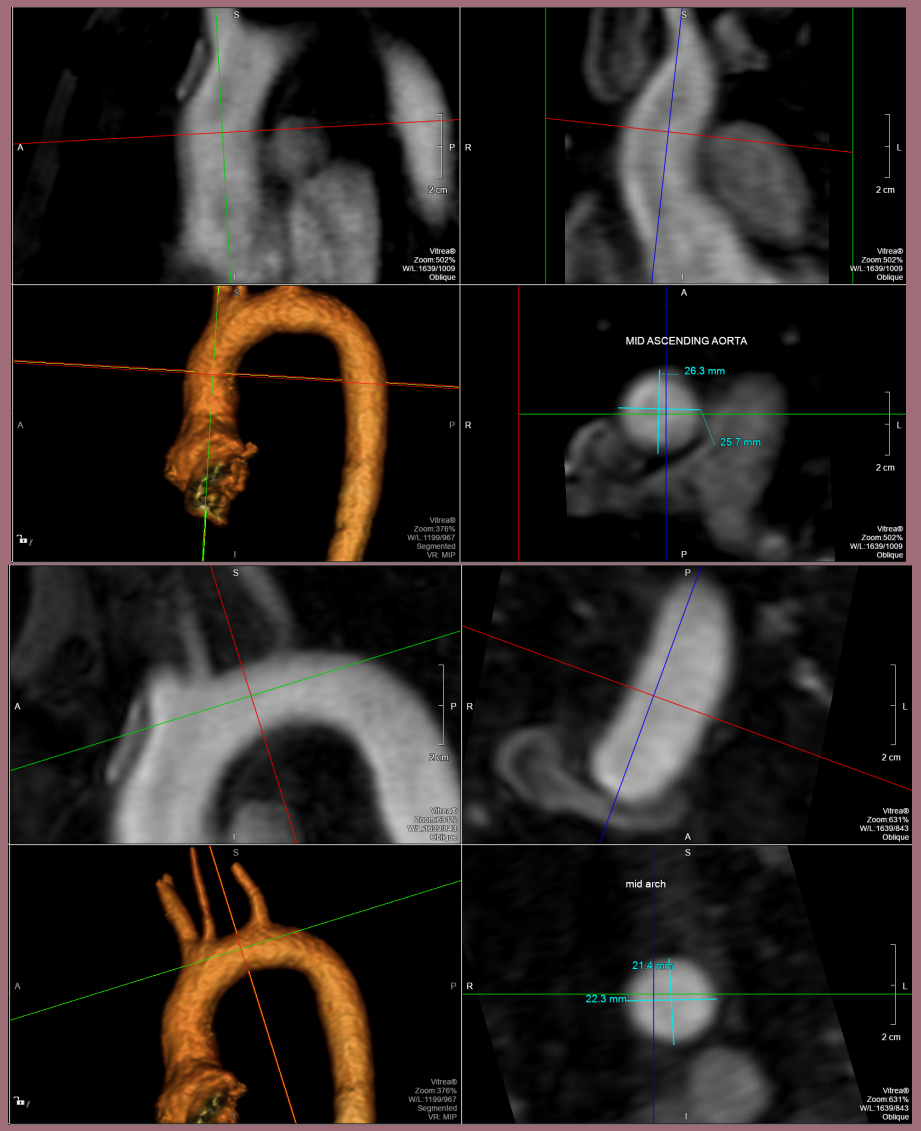

Intense and Close Surveillance in LDS is Needed

Imaging recommendations	Annual CTA or MRA performed from head to at least the pelvis [19, 32]
	Run-off studies may be considered to evaluate for iliac aneurysms [30, 32]
	3- to 6-month serial echocardiograms to evaluate valvular disease and aortic root dilation if initial measurements are abnormal; echo at 6 months and then annually if initial measurements are normal with minimal progression [5, 32]
	Serial echocardiograms every 3 months for 1 year after aortic root grafting, then every 6–12 months thereafter if warranted based on severity of phenotype [32]
	Cervical spine plain films with flexion and extension views to assess for instability, particularly prior to general anesthesia and/or surgery [3, 32]
	Thoracolumbar spinal imaging to assess for scoliosis and spondylolisthesis [3]
	DEXA scan to assess for osteopenia
Surgical recommendations	*Children:* if clinical phenotype is severe, surgery once ascending aorta exceeds 99th percentile and annulus is at least 1.8 cm, or rapid expansion (>0.5 cm/year); timing depends on presence of TGFBR mutation, family history and ability to place graft of sufficient size to permit growth, among other factors [5, 32]
	Adolescents and adults: 4.0-cm threshold for aortic root grafting, or rapid expansion (>0.5 cm/year) [17, 19]; some data to suggest 5.0-cm threshold in adult patients with less severe clinical phenotype [57]
	Pregnancy: Elective early cesarean section may be recommended, with referral to high-risk OB/GYN clinic and prenatal diagnosis if disease-causing mutation is known [2]

Bicuspid Aortic Valve and Aortopathy

BAV is most common congenital disorder 0.5-1.5% of population

sporadic AD transmission : M: F = 3: 1

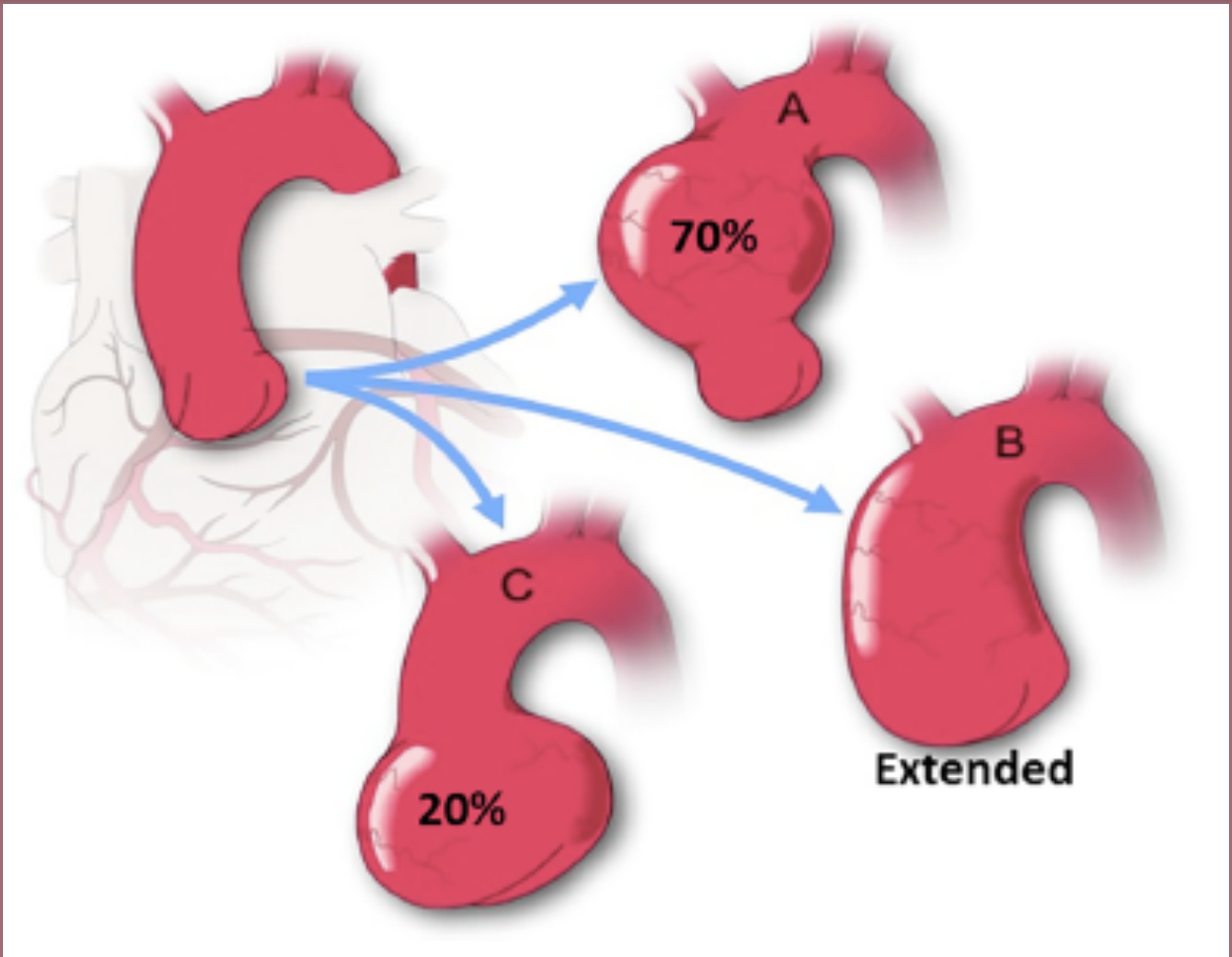

H.I. Michelena et al. / Progress in Cardiovascular Diseases 63 (2020) 419–424

Types of BAV fusion

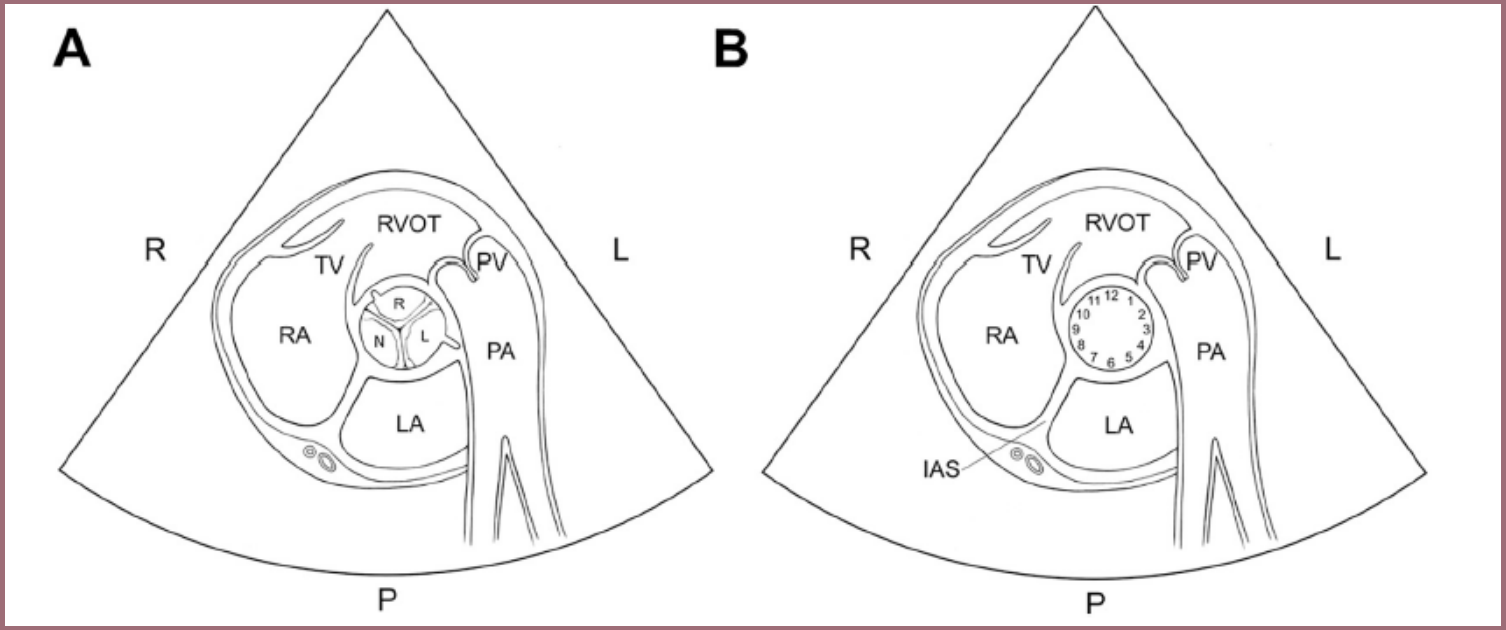

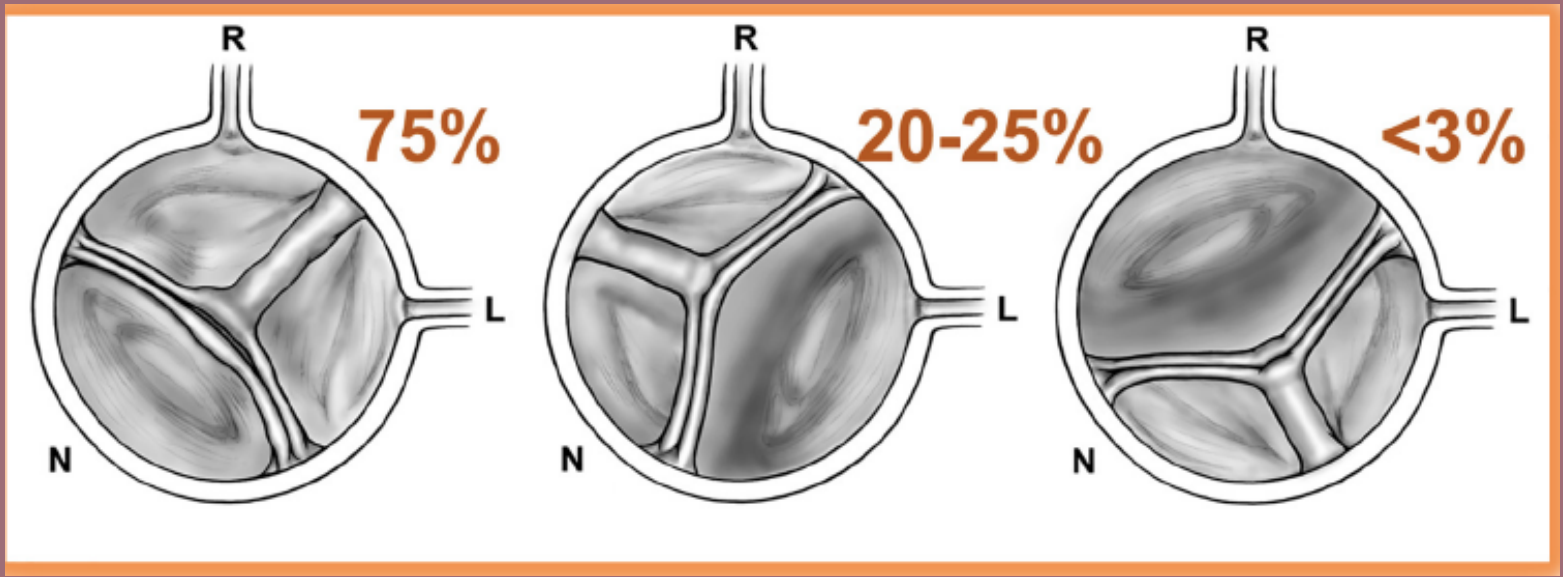

Aorta issues in BAV

- At autopsy upto 35% reported to have aortic involvement
- Can occur at any level mainly unto ascending aorta
- AS does not need to be present for aorta enlargement
- Intrinsic wall abnormalities (elastin fragmentation, fibrillin issues,cellular apoptosis, MMP over expression , location of the outflow jet hitting aortic wall all contribute)

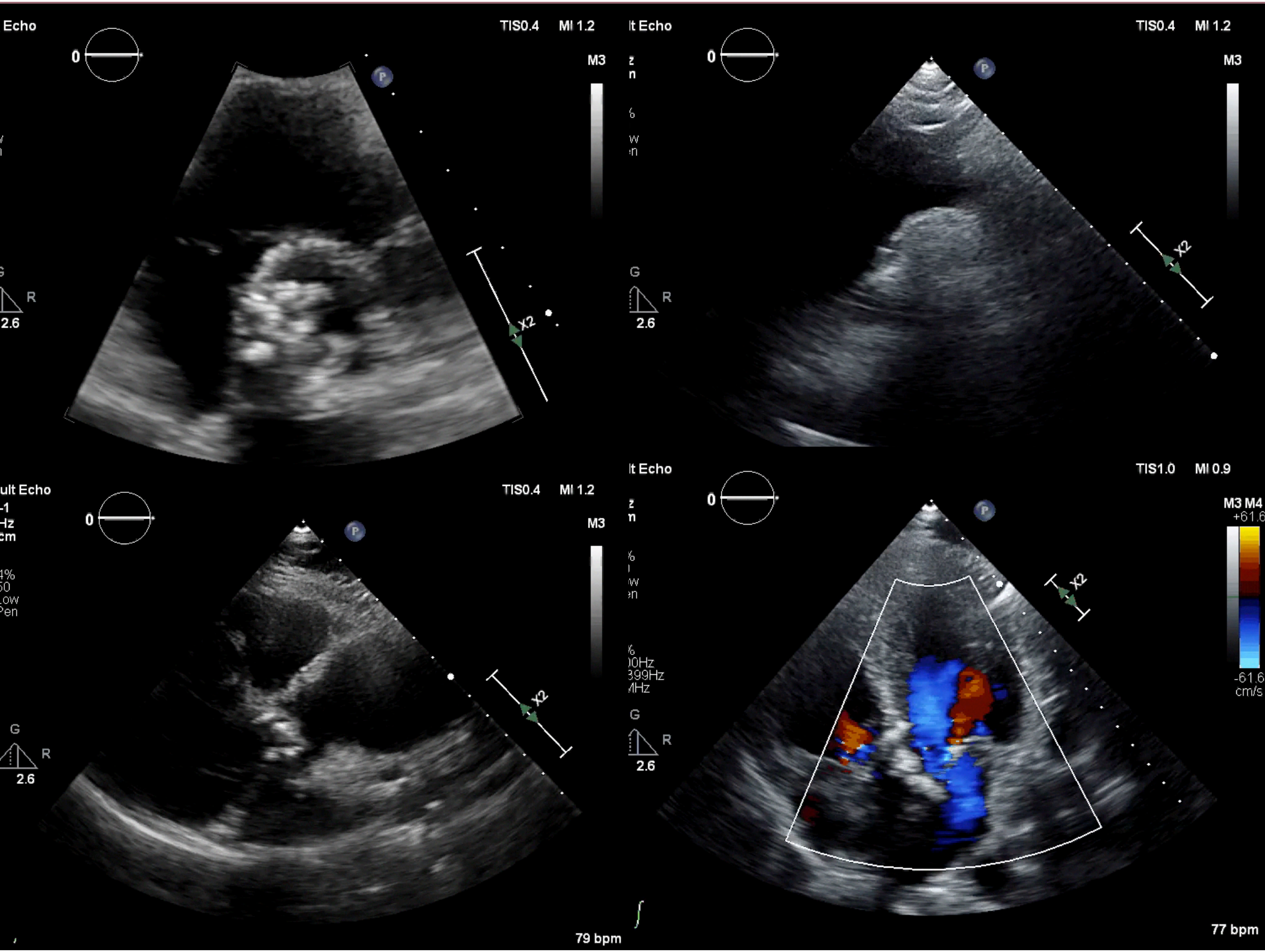
Echo
TIS0.4 MI 1.2
M3
X2
R
2.6
TIS0.4 MI 1.2
M3
X2
R
2.6
ult Echo
TIS0.4 MI 1.2
M3
X2
G
R
2.6
79 bpm
TIS1.0 MI 0.9
M3 M4
+61.6
-61.6
cm/s
X2
77 bpm

BAV -Aorta surveillance

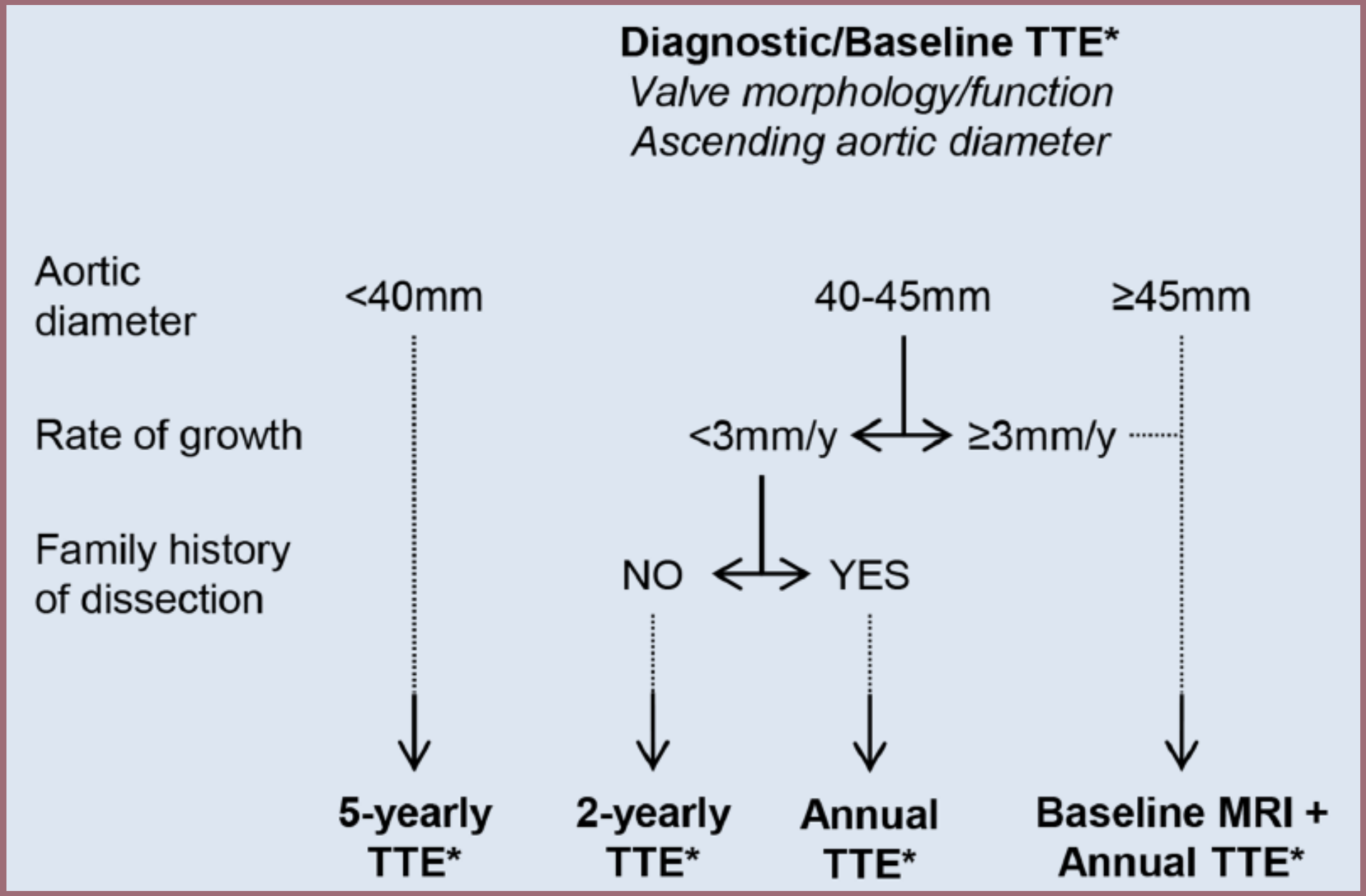

BAV/Aortopathy

Shones complex

Williams syndrome

Turner syndrome

9% prevalence of BAV in 1st degree relatives
ACC guidelines recommend echo screening in all first degree relatives
1/3 of first degree relatives of BAV patients have aorta dilation despite trileaflet valves

40 year old male with HTN and with family history of bicuspid aortic valve and heart murmur

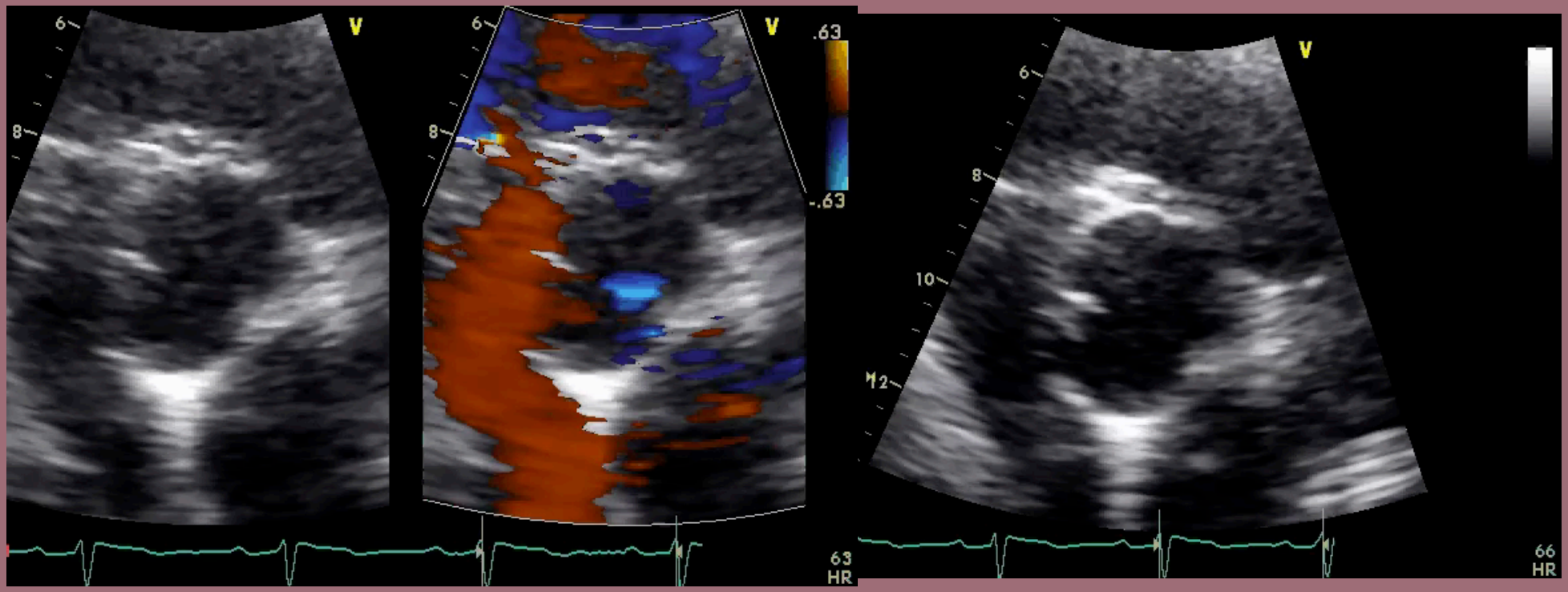

50-70% of Coarctation cases have associated BAV
< 10% of cases of BAV have associated Coarctation
Remember Shone complex association /Turner syndrome

Mild Coarctation

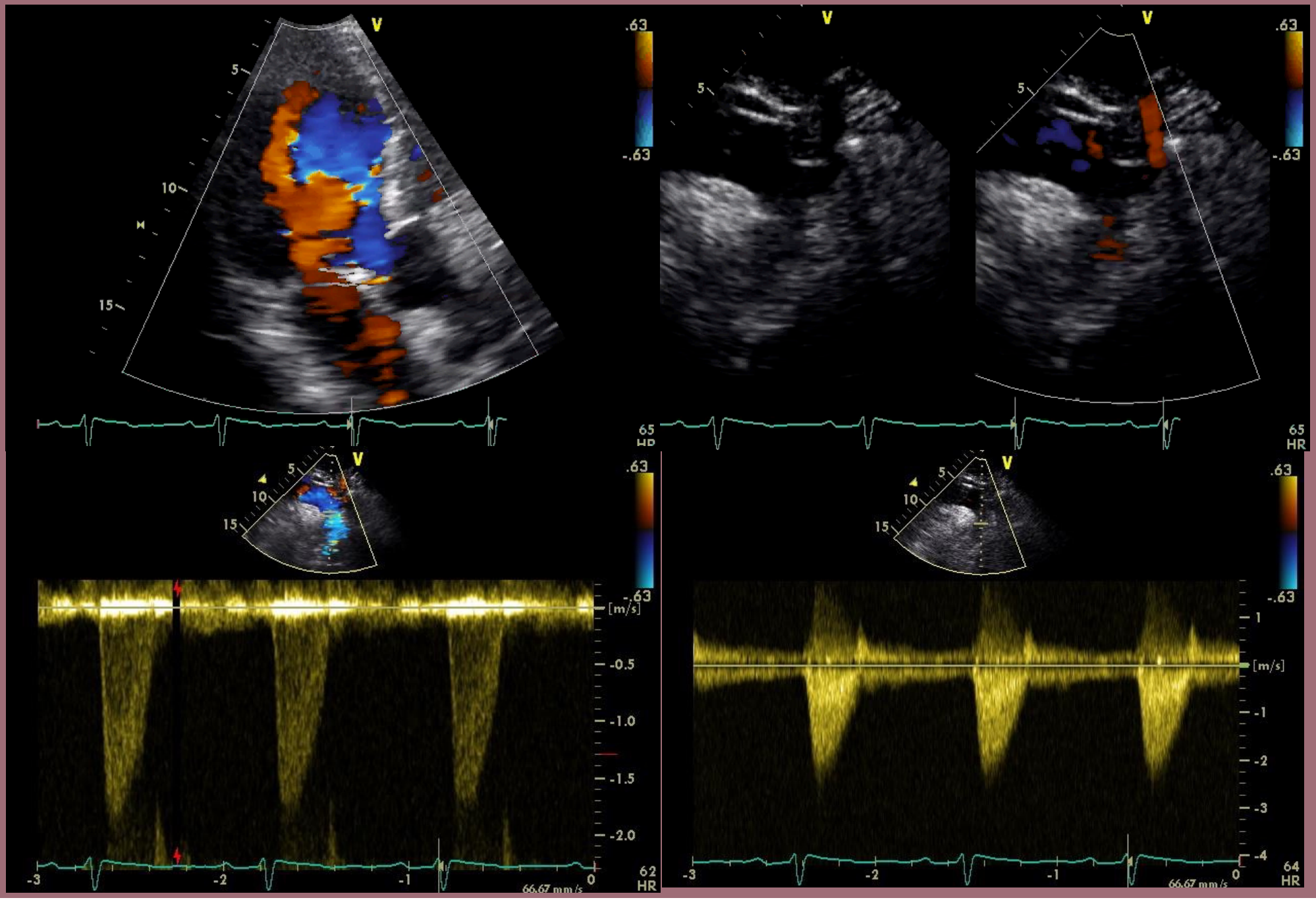

Coarctation of the Aorta

- Usually just distal to the Left SC artery (Preductal or post ductal).
- Best seen on suprasternal windows.
- Doppler:

-Peak gradient can be obtained,

-Look for persistent diastolic flow.

- Account for Proximal velocity if >1.5 m/s.
- Peak gradient calculation (remember prox velocity) as part of Bernoulli equation

Severe Coarctation

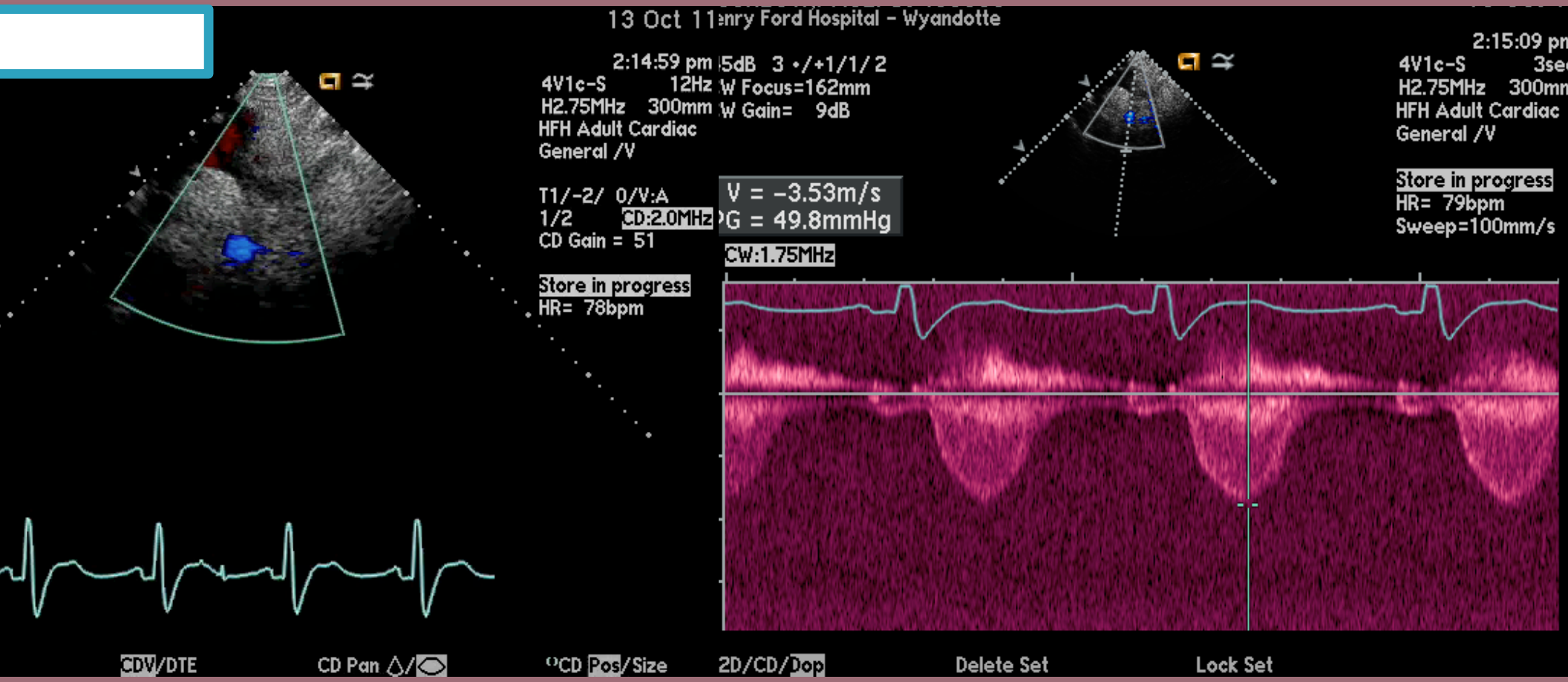

Sinus of Vasalva ANEURYSM

- most often arise from the right sinus.
- highly variable in size and by definition communicate with the sinus by a relatively wide mouth.
- typically protrude down into the right atrium
- rupture typically causes acute decompensation
- continuous murmur

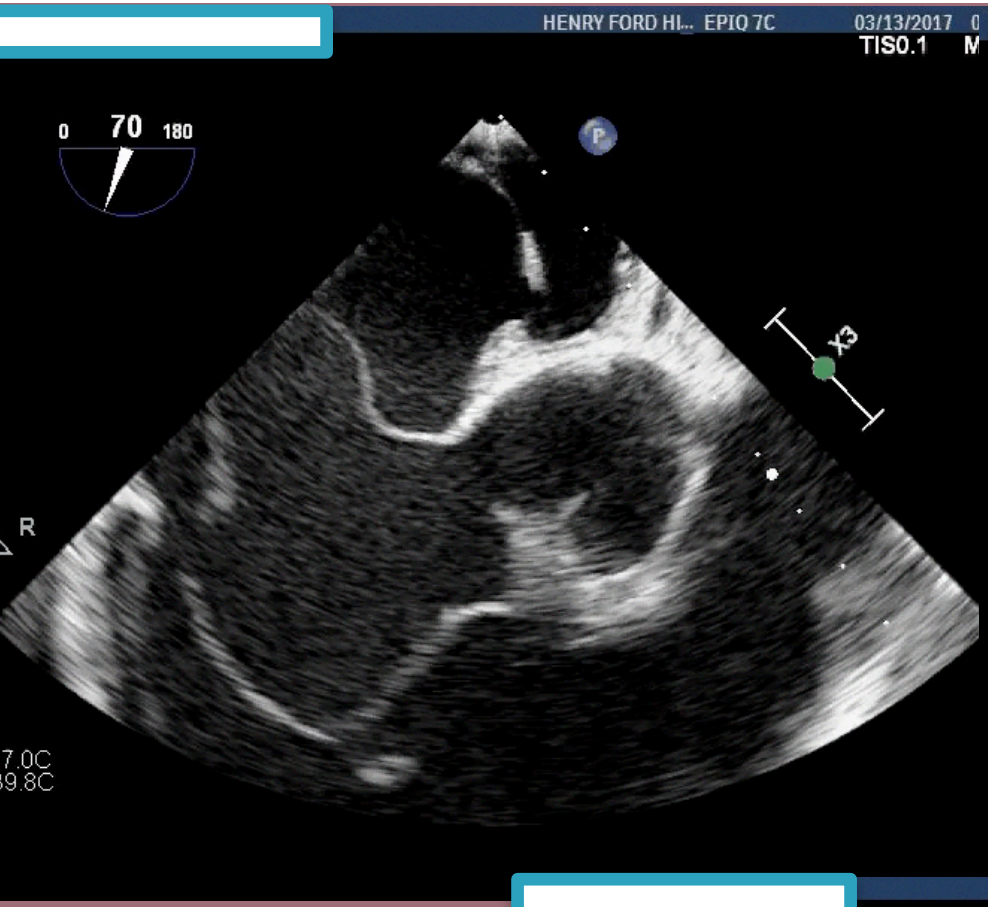
HENRY FORD HI... EPIQ 7C
03/13/2017
TIS0.1
0
70
180
X3
R
7.0C
39.8C

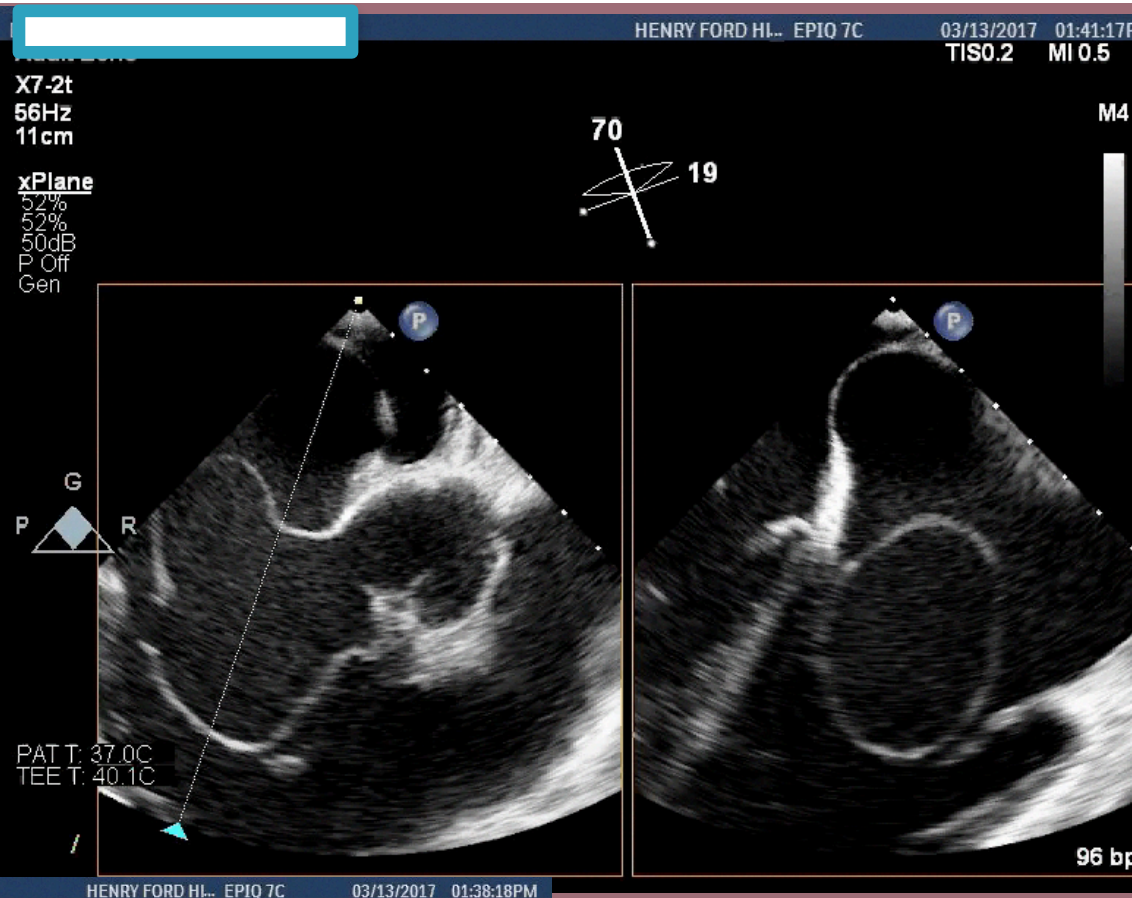
HENRY FORD HI... EPIQ 7C
03/13/2017
TIS0.2
MI 0.5
X7-2t
56Hz
11cm
xPlane
52%
52%
50dB
P Off
Gen
70
19
M4
G
P
R
PAT T: 37.0C
TEE T: 40.1C
96 bp

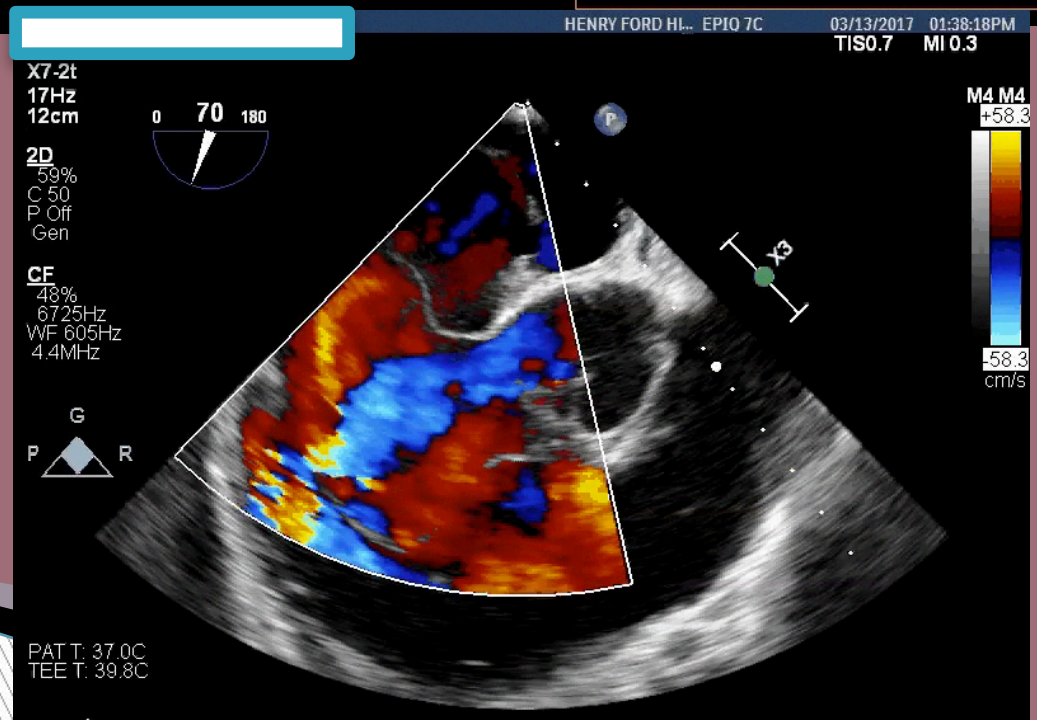
HENRY FORD HI... EPIQ 7C
03/13/2017
01:38:18PM
TIS0.7
MI 0.3
X7-2t
17Hz
12cm
0
70
180
2D
59%
C 50
P Off
Gen
CF
48%
6725Hz
WF 605Hz
4.4MHz
G
P
R
X3
M4 M4
+58.3
-58.3
cm/s
PAT T: 37.0C
TEE T: 39.8C

Aortic Atheroma

- DA>Arch>Aao.
- The morphology of atheromatous plaques is dynamic, with frequent formation and resolution of mobile components.
- Highly prevalent (51% of the population over 45 years)
- Simple vs Complex

Aortic Atheromas

Simple Atheromas

Protruding

< 4 mm

No mobile debris

No surface ulceration

Complex Atheroma

Protruding

> 4 mm

Mobile debris

> 2mm ulceration

Grading of aortic atheroma

Grade	Description	Percentage of incidence of stroke (%)
1	Normal aorta	0
2	Extensive intimal thickening <3 mm	0
3	Protrudes <5 mm into aortic lumen	5
4	Protrudes >5 mm into aortic lumen	10.5
5	Mobile atheroma	46.5

Katz et al JACC 1992

Complex Atheroma

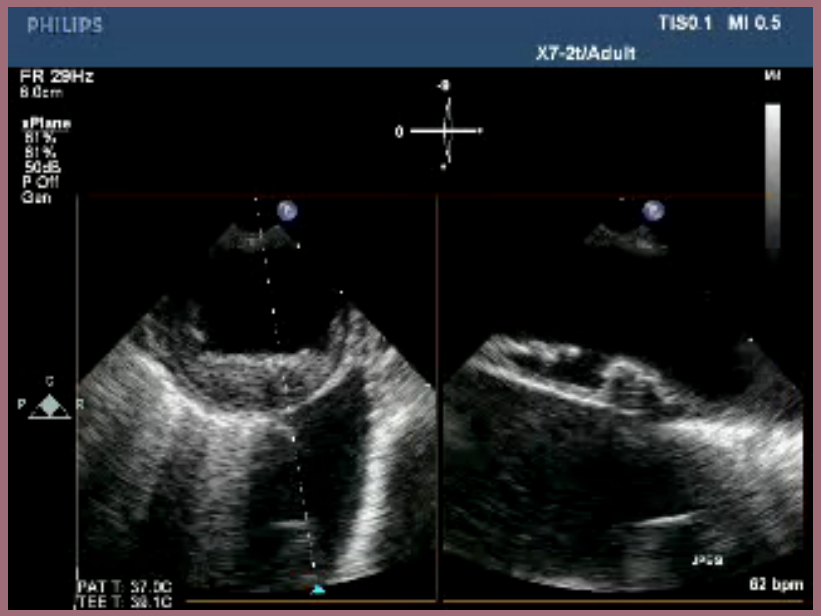

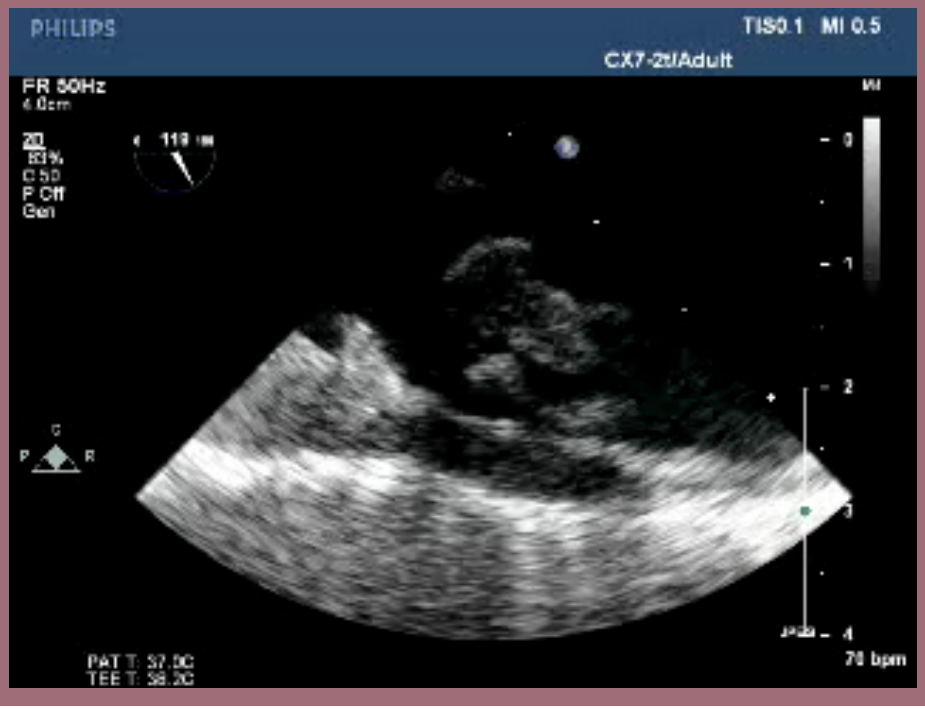

Pregnancy In Aortopathies

- **PREGNANCY (WISH)**
- **Counselling**
  - Women with aortic dilatation and/or genetic aortopathy contemplating pregnancy should be counselled about the risk for aortic dissection and the hereditary nature of the disease. Pregnancy should be discouraged if aortic diameter has reached the threshold for prophylactic surgery (table 3). Prepregnancy aortic surgery should be considered*
- **Pharmacological treatment**
  - Strict blood-pressure control is indicated
  - Start β-blocker therapy in women with genetic aortopathy syndrome, aortic dilatation and/or (history of) type B aortic dissection
  - Angiotensin receptor blockers/ACE inhibitors are contraindicated: switch to β-blockers as soon as contraceptives are stopped
- **Imaging**
- *Prepregnancy*
  - MRI (or CT) imaging of the entire aorta advisable
- *During pregnancy*
  - Aortic root/ascending aortic dilatation and/or genetic aortopathy syndrome: transthoracic echocardiography per 4–8 weeks
  - Dilatation beyond distal ascending aorta: MRI (without gadolinium)

Heart 2017;**103**:952–966

Pregnancy and Surgery Recs In Aortopathies

- *During pregnancy*
  - Indications: type A dissection; type B dissection, if complicated by malperfusion or aortic rupture (otherwise, medical treatment with MRI monitoring); prophylactic, aortic diameter =50 mm with rapid growth
  - First/second trimester (=28 weeks), fetus not viable: aortic repair with intensive fetal monitoring
  - Third trimester (=29 weeks), fetus viable: urgent caesarean section directly followed by aortic surgery
- **DELIVERY**
- **At centre where cardiothoracic surgery is available**
- **Mode of delivery**
  - Aortic root/ascending aortic diameter <40 mm: vaginal delivery favoured
  - Aortic root/ascending aortic diameter 40–45 mm: consider vaginal delivery with epidural anaesthesia and expedited second stage (eg, forceps, vacuum delivery) or caesarean delivery
  - Aortic root/ascending aortic diameter >45mm: consider caesarean delivery
- **Timing**
  - Consider elective caesarean delivery in Loeys-Dietz syndrome, vEDS or non-syndromic familial thoracic aortic aneurysms and dissections and aortic dilatation

Heart 2017;**103**:952–966

Sports in Aortopathies

Conditions
Marfan syndr
All patients
No risk-increas
Risk-increasing
- Aortic root/as
Moderate mitra
- Chronic disse
dissection/sudc
Vascular Ehle
All patients
Bicuspid aorti
Ascending aort
Ascending aort
Ascending aort

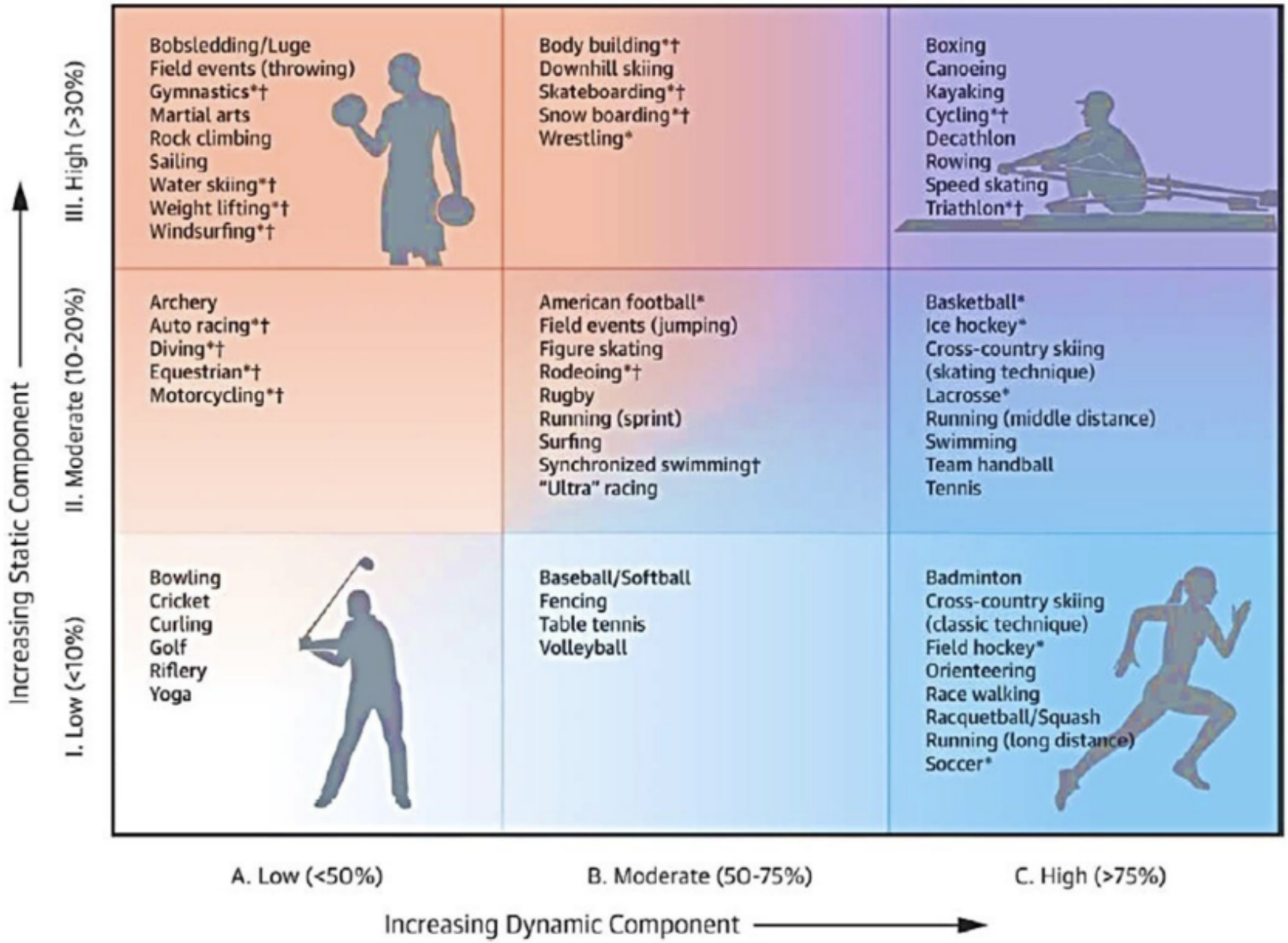

Circulation 2015;132

Thresholds for surgical referral: Thoracic Aneurysms

Recommendations for Surgical Repair of Thoracic Aortic Aneurysms

Etiology	Size Threshold for Repair
Symptomatic aneurysm (regardless of etiology)	Any size causing symptoms (dissection, pain, compression)
Degenerative	5.5 cm
BAV	5-5.5 cm; aortic area/height >10 cm^2/m
Marfan	4-5 cm; aortic area/height >10 cm^2/m
Loeys-Dietz	4.2-4.6 cm
Turner	2.5 cm/m^2
Requiring other cardiac surgery	4.5 cm

Question 1

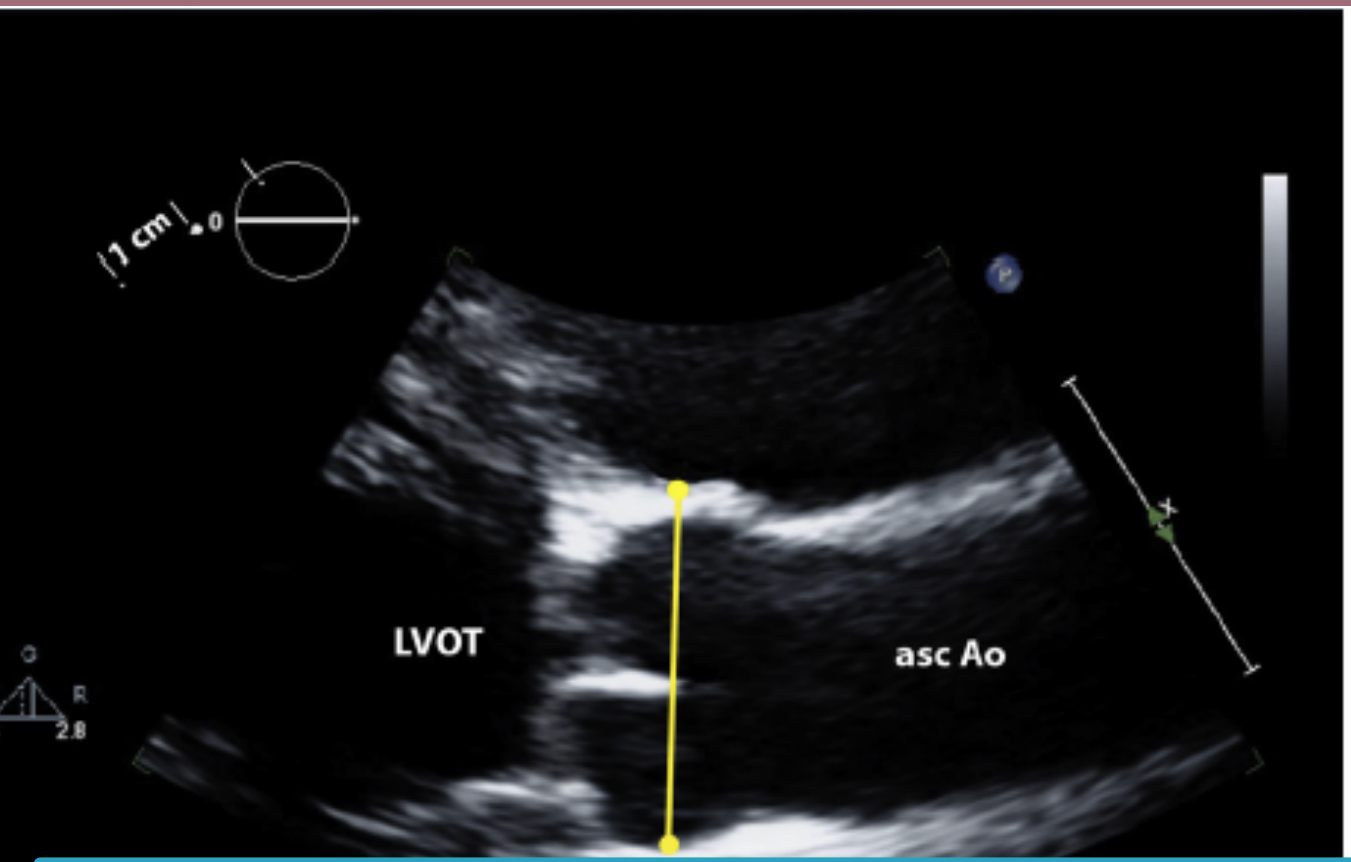

The following measurement of the aortic root on 2D TTE follows ASE guidelines

a **true**
b false

Measurement tips
should be made perpendicular to long axis of aorta
largest diameter from right coronary sinus to non coronary sinus
leading edge to leading edge ; preferable in diastole
Contrast that with LVOT measurement : mid systole / inner edge to inner edge

Question 2

normal suprasternal view
arch dissection
arch aneurysm
anomalous venous drainage

?

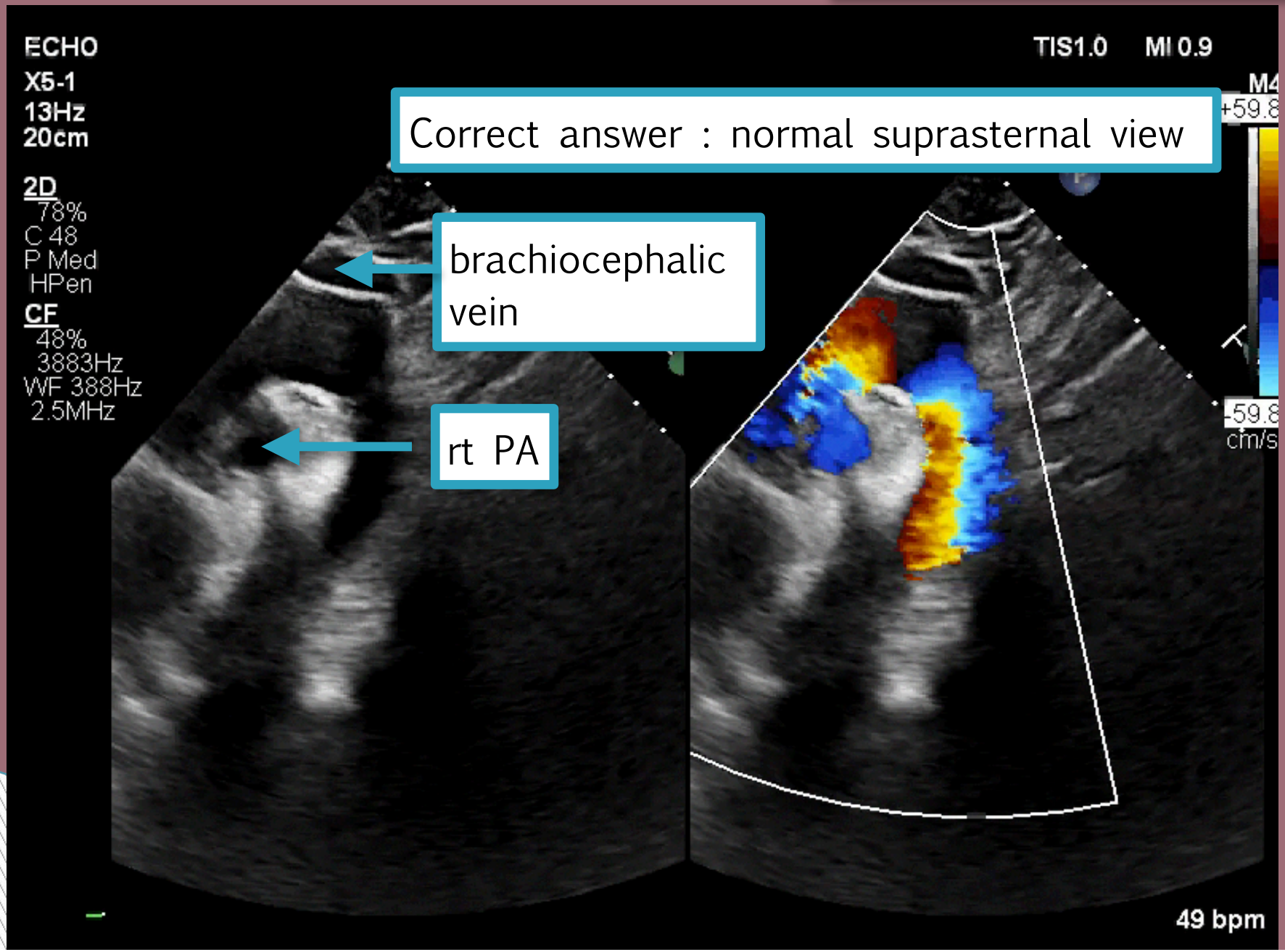

Correct answer : normal suprasternal view

brachiocephalic vein

rt PA

Question 3

Which of the following conditions associated with aortic aneurysms is caused by TGF-Beta or SMADD 3 mutation with systemic connective tissue involvement ?

a. Bicuspid Aortopathy
b. **Loey Dietz syndrome**
c. Marfan syndrome
d. Ehlers-Dalos syndrome

Surveillance

annual or biannual echocardiograms

annual computed tomography angiography (CTA) or magnetic resonance angiography (MRA) brain to pelvis

cervical spine X-rays

Question 4

Which of the following characteristics is true for identifying a false lumen (FL) from true lumen (TL) in aortic dissection ?

1. FL is smaller in size than true
2. Systolic compression is usually seen with FL
3. Color flow can be seen from FL to TL
4. Flow is brisk in FL

Thank you