Ultrasound Physics

Fundamentals of 2D, Color and Spectral Doppler
Pitfalls and Artifacts

Iowa Chapter of the ACC & FIT Council
Echo Board Preparation Lecture Series
April 2021

Stephanie Ellingson, MS, RDMS, RDCS, RVT
Director, Diagnostic Medical Sonography Education
Carver College of Medicine – Radiation Sciences

THE UNIVERSITY OF IOWA

Disclosures:

I have no disclosures

Objectives

Upon completion of this lesson the student will:

1. Identify how the 2D image is created, potential imaging pitfalls and artifacts, and changes required for image optimization
2. Identify ways the color image is created, potential imaging pitfalls and artifacts, and changes required for image optimization
3. Identify how the PW Doppler is used, advantages, disadvantages, pitfalls and artifacts
4. Identify when CW Doppler is used, advantages, disadvantages, pitfalls and artifacts

How is this image created?

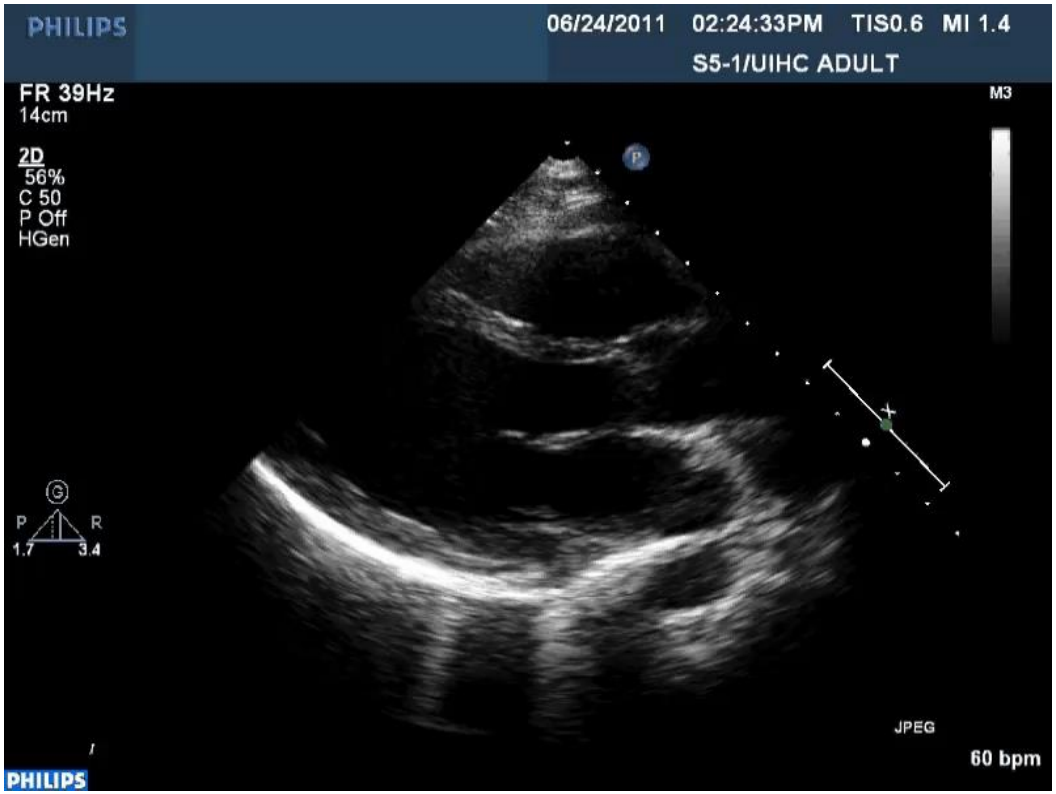

We create an image from reflections that are placed horizontally and vertically based on physics, instrumentation and assumptions

….so we need to talk about that a bit

Depth

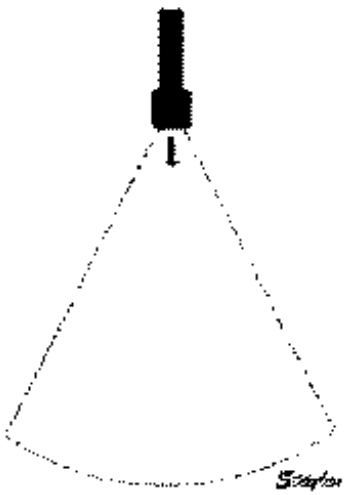

- Pulse-echo technique – US sent into body, reflects off structures and returns to the transducer
- Reflection return time determines depth
- Pulsing provides time/depth information – vertical axis

$$\text{Depth (mm)} = \frac{\text{C(mm/us) x Time (us)}}{2}$$

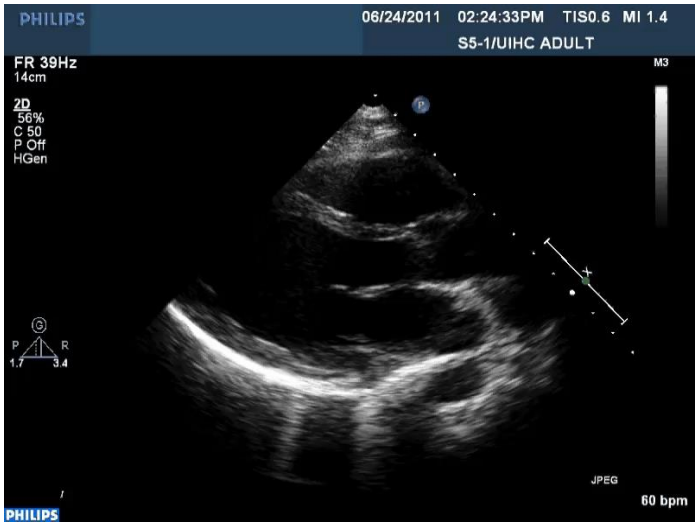

- *Pitfalls*
  - *Propagation speed error*
  - *Multipath*
  - *Reverberation*

Scan Lines

- The beam is moved through the body in a sweeping action producing real-time
- Displayed reflections
  - Horizonal locations corresponding to the direction of the beam sent out

- *Pitfalls*
  - *Grating lobes and side lobes*
  - *Refraction*

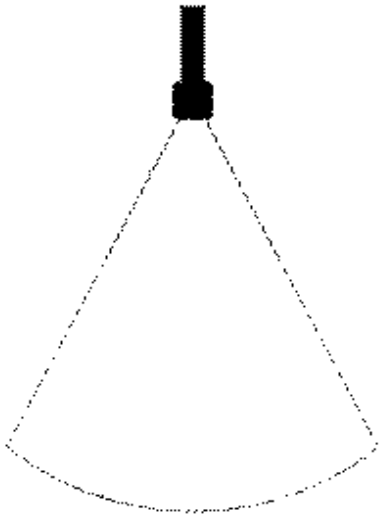

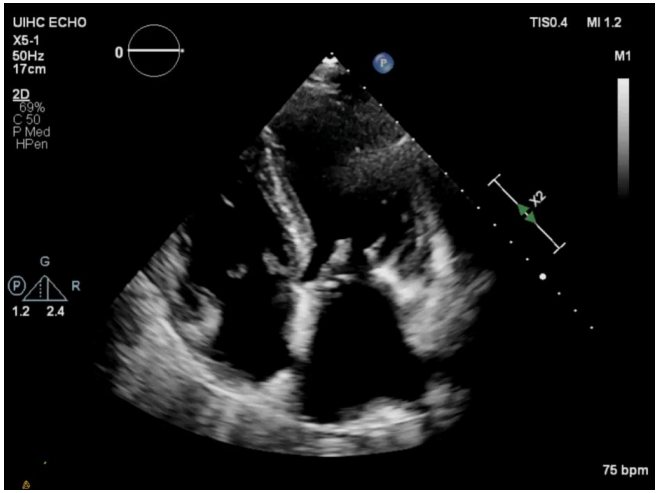

Brightness

- The reflection brightness is based on the amplitude of the reflect
  - Higher amplitude = brighter reflection

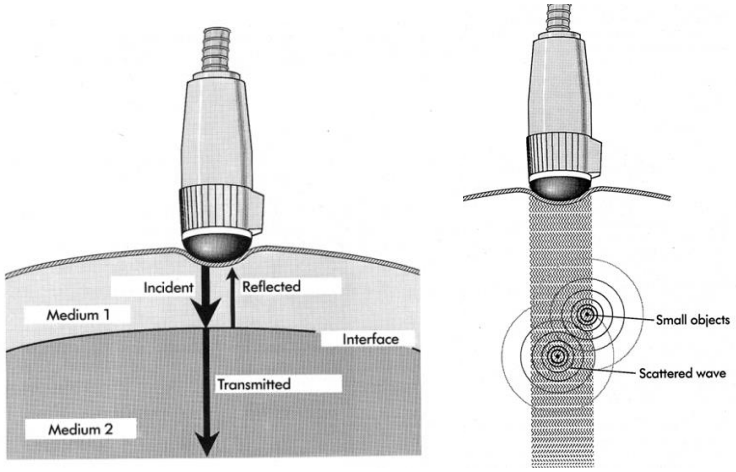

- *Pitfalls*
  - *Type of reflector*
  - *Angle of insonation*
  - *Attenuation*

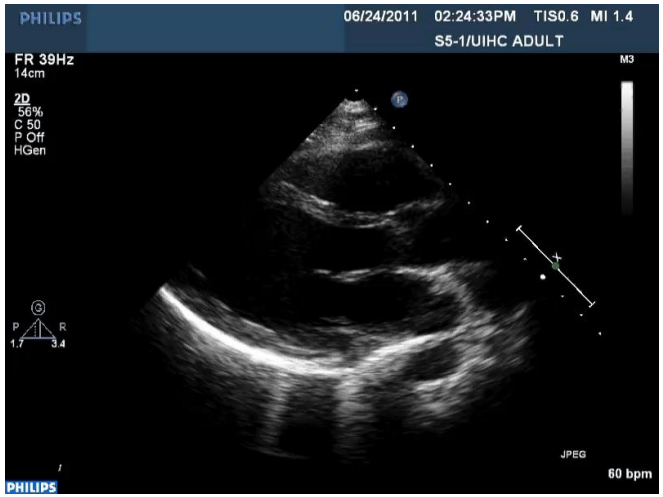

What does the instrument know?

- The instrument knows only 3 pieces of information about the reflection
  - Strength (amplitude)
  - Direction the beam was sent
  - Arrival time

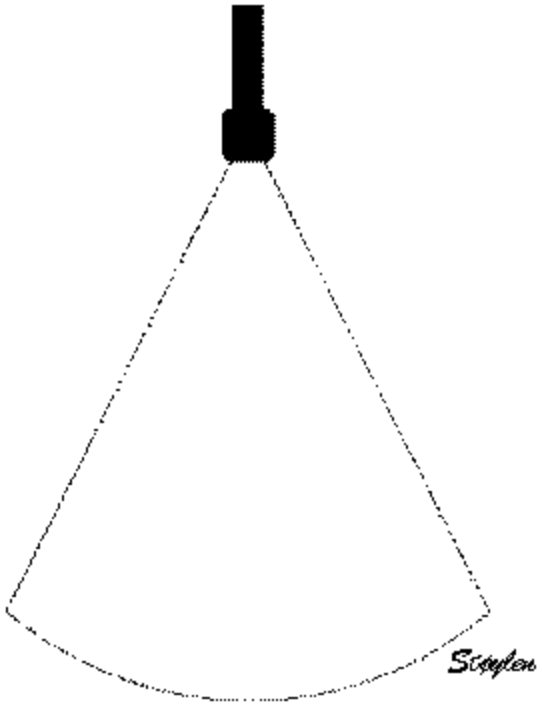

What does the instrument assume?

- From the 3 pieces of information it KNOWS it ASSUMES the following
  - Strength (amplitude)
    - Strength is related to the anatomy or interfaces
    - Pitfalls
      - Attenuation is assumed to be a constant, which it is not
      - Strength of the beam is assumed to be a constant which it is not
    - Results in shadow, enhancement, focal banding at focal zone

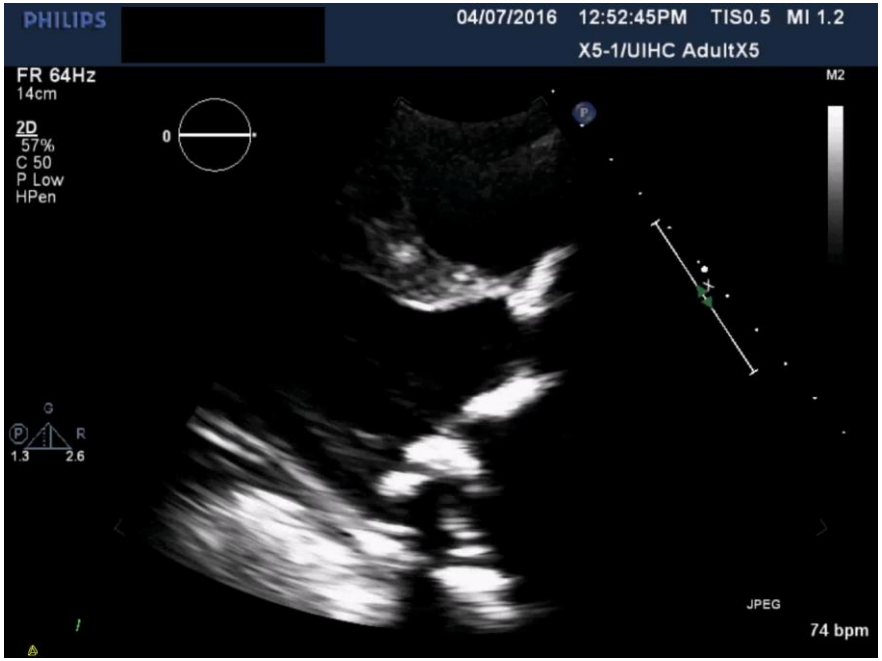

What does the instrument assume?

- Direction
  - Assumes the beam went straight down and back once, and all US energy is within the beam
  - Pitfalls
    - May not go straight (refraction)
    - Side lobes or grating lobes
  - Results in echoes in the wrong place horizontally or in the elevation plane

What does the instrument assume?

- Arrival time
  - Assumes the beam went straight down and back **once**, and traveled 1540 m/s
  - Pitfalls
    - May not go once (reverberation or multipath)
    - May not travel 1540 m/s
  - Results in echoes in the wrong place vertically (depth)

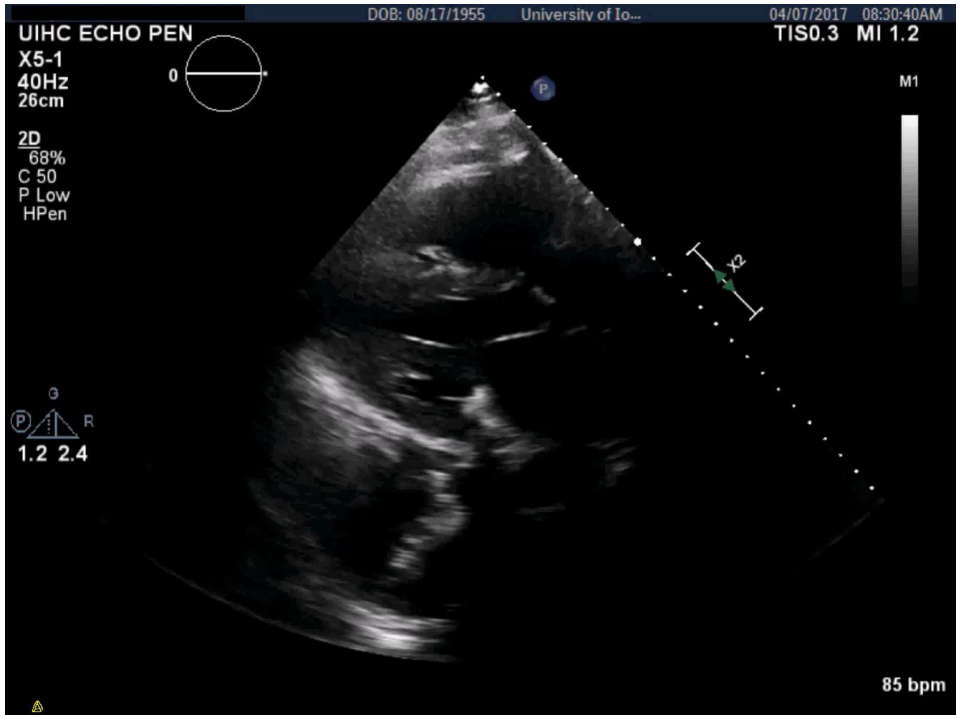

Echo Artifacts

Two outstanding resources for echo artifacts, including video examples, are:

1. Bertrand PB, Levine RA, et al. Fact or Artifact in Two-Dimensional Echocardiography: Avoiding Misdiagnosis and Missed Diagnosis. JASE, May 2016; Vol 29, Issue 5, p 381-391. DOI: https://doi.org/10.1016/j.echo.2016.01.009

2. Faletra FF, Ramamurthi A, et al. Artifacts in Three-Dimensional Transesophageal Echocardiography. JASE, May 2014; Vol 27, Issue 5, p 453-462. DOI: https://doi.org/10.1016/j.echo.2014.02.003

Case

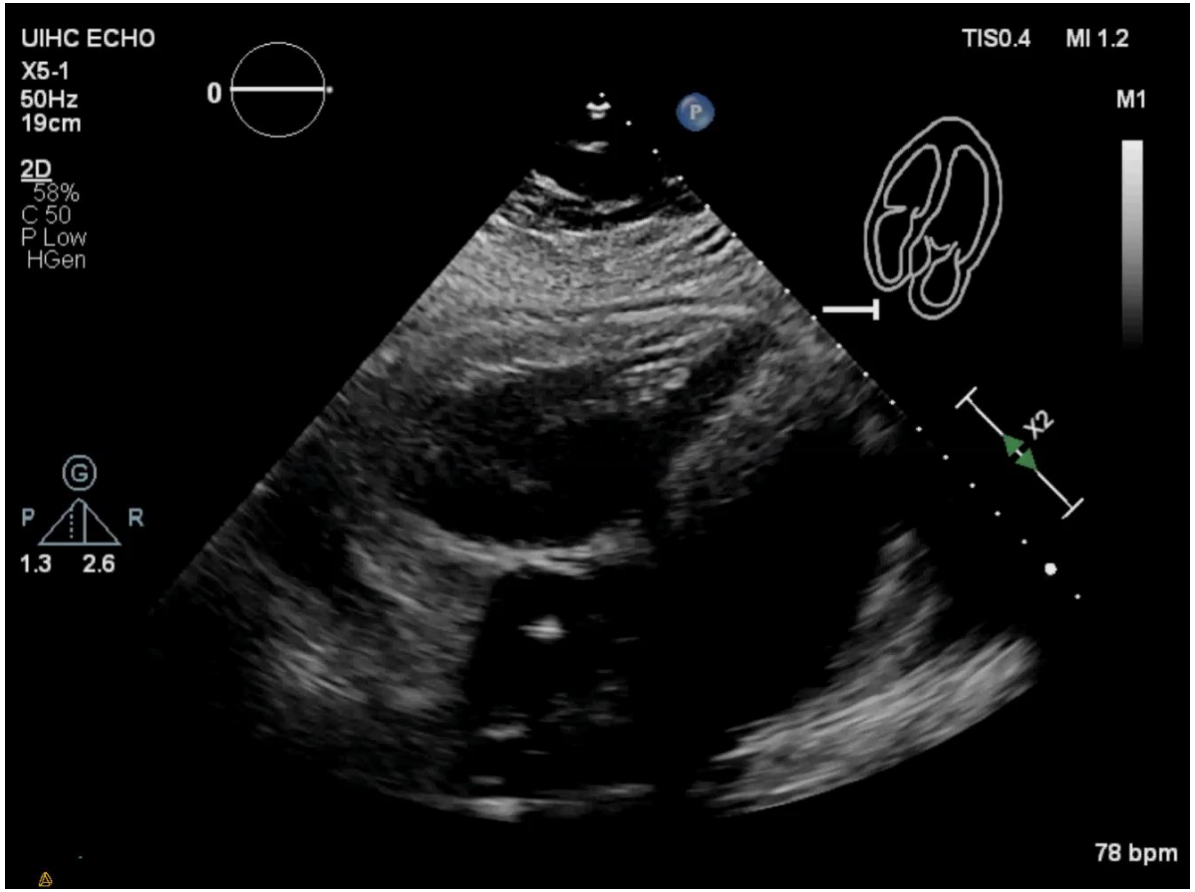

So many artifacts….☺

What about the one starting in the RV?

Shadow artifact – wrong amplitude/strength of reflector

Shadow Artifact

- Loss of image deep to a <u>highly attenuating</u> structure
  - Calcium
  - Catheter
  - Metal (prosthetic valve)

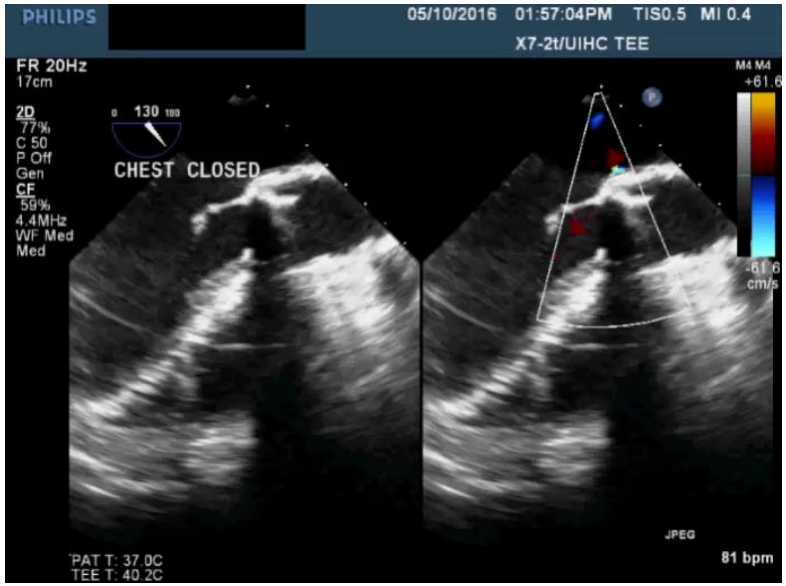

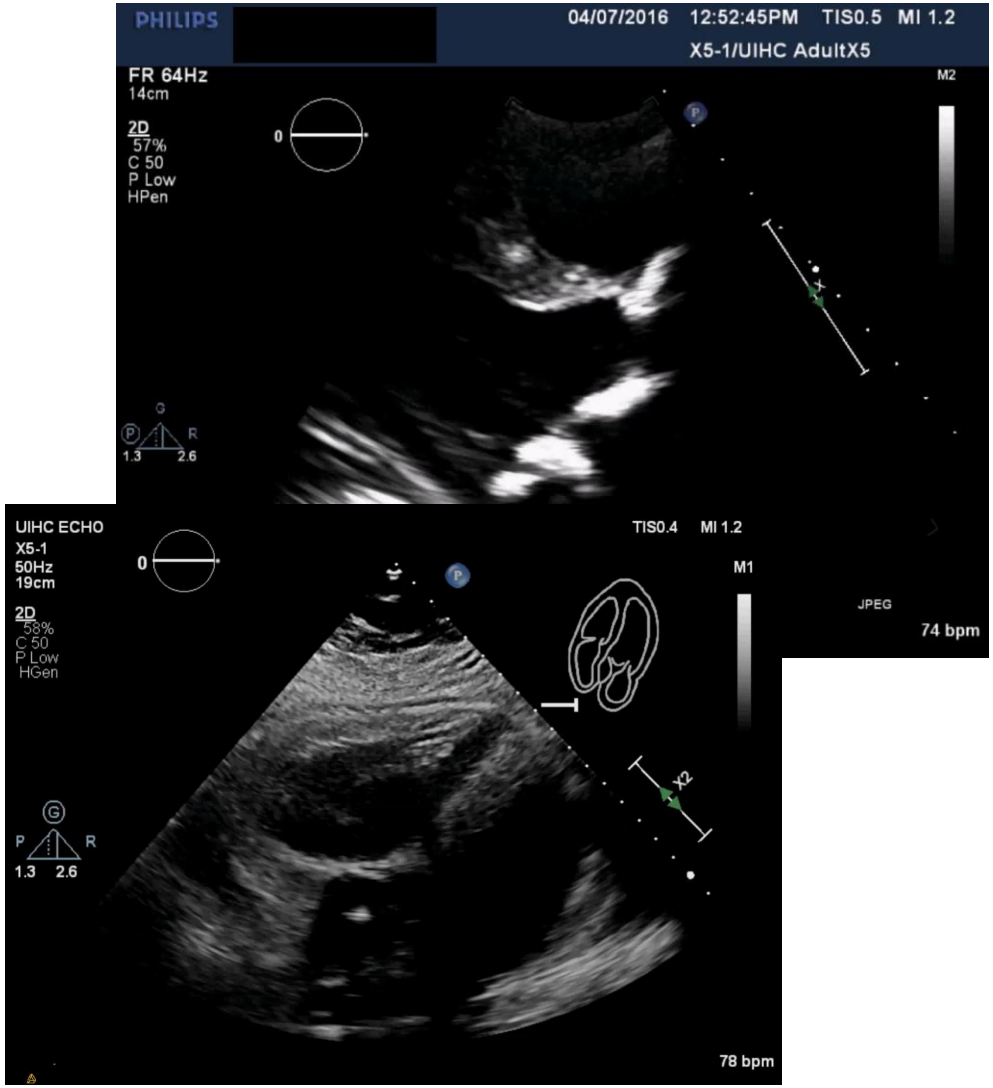

Shadow Artifact

- Remember color and spectral Doppler will shadow too

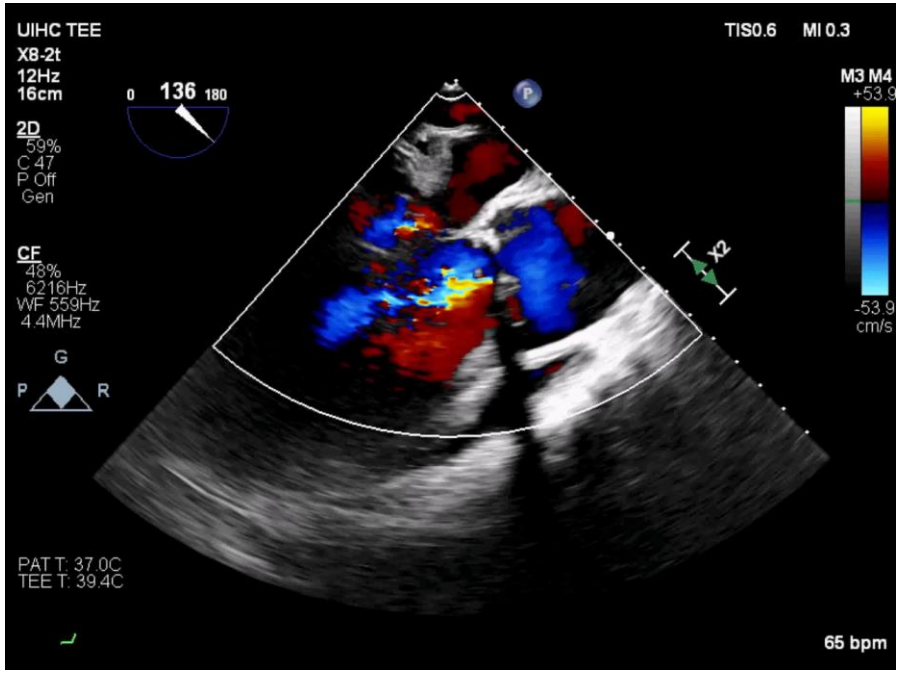

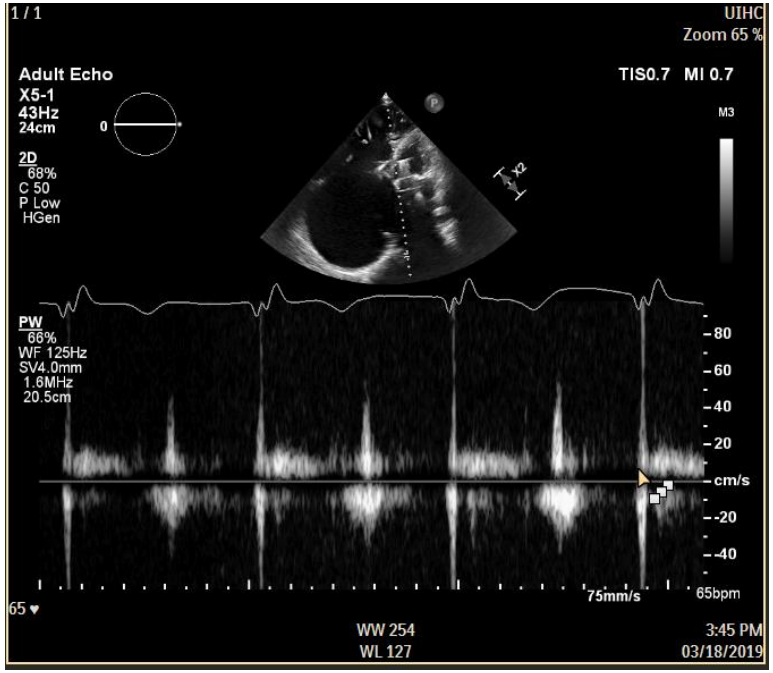

Mechanical prosthetic MV shadowing PW Doppler to Pulmonary Veins

Case

Is that pacer wire going through the RV free wall?

No
Grating lobe (aka side lobe) artifact

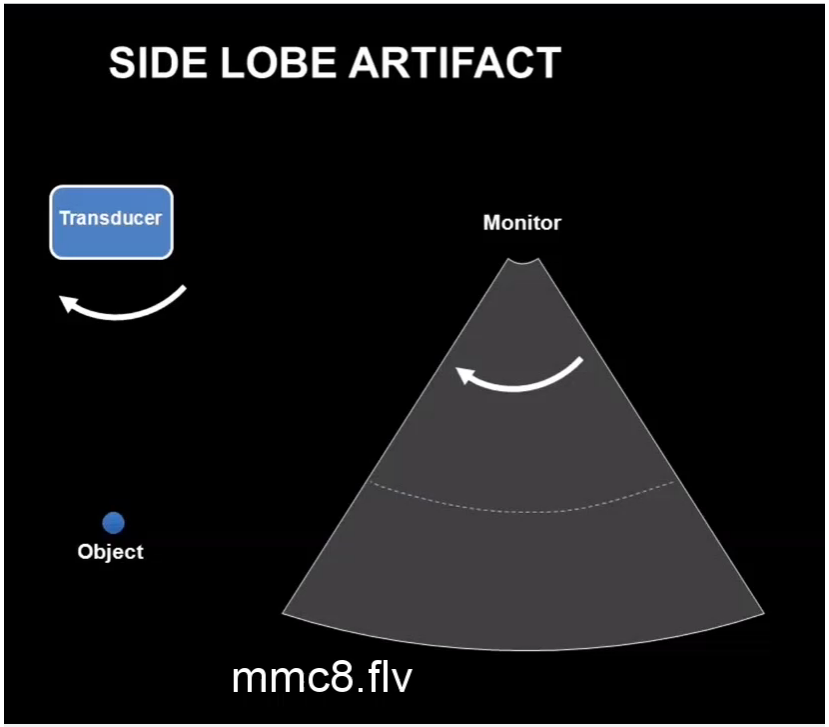

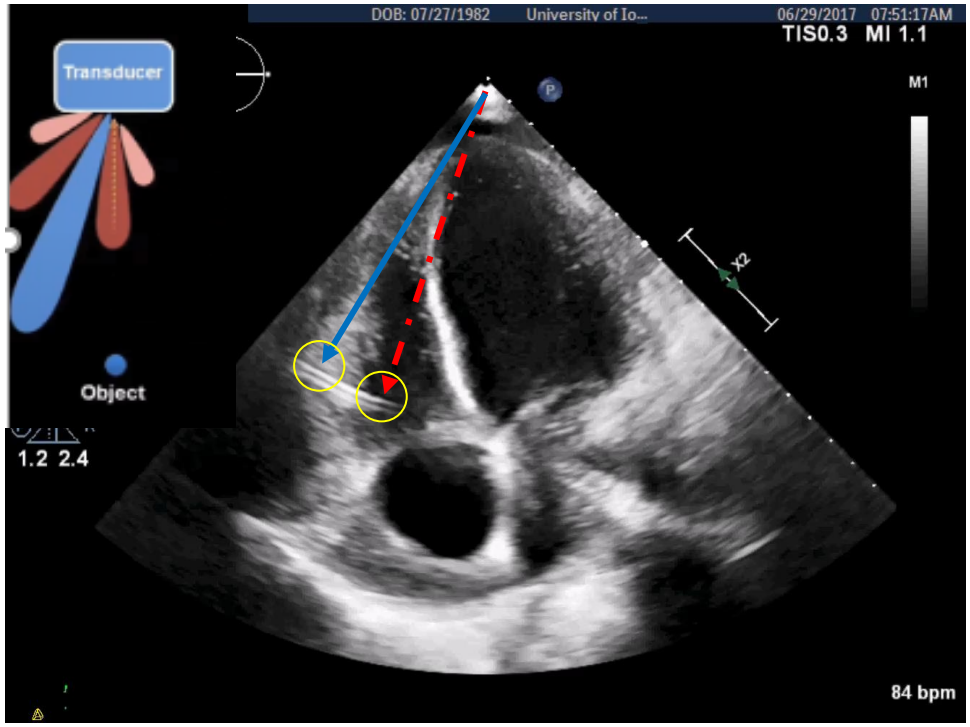

Bertrand et all, JASE, May 2016

Sound outside of the primary beam, taking a path other than what the instrument assumed

Duplicate echoes placed incorrectly horizontally

Grating/Side-Lobe

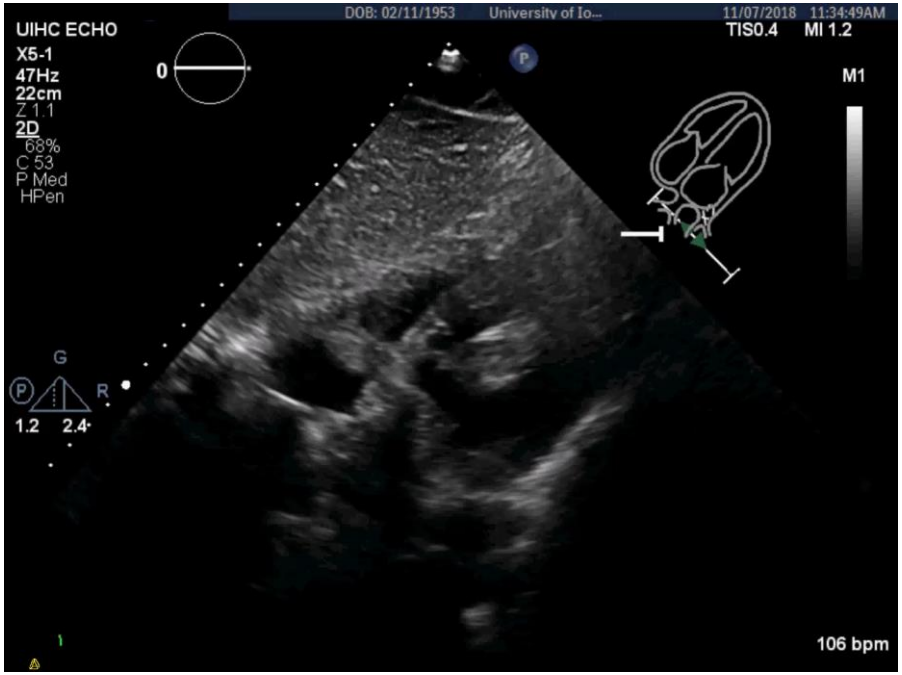

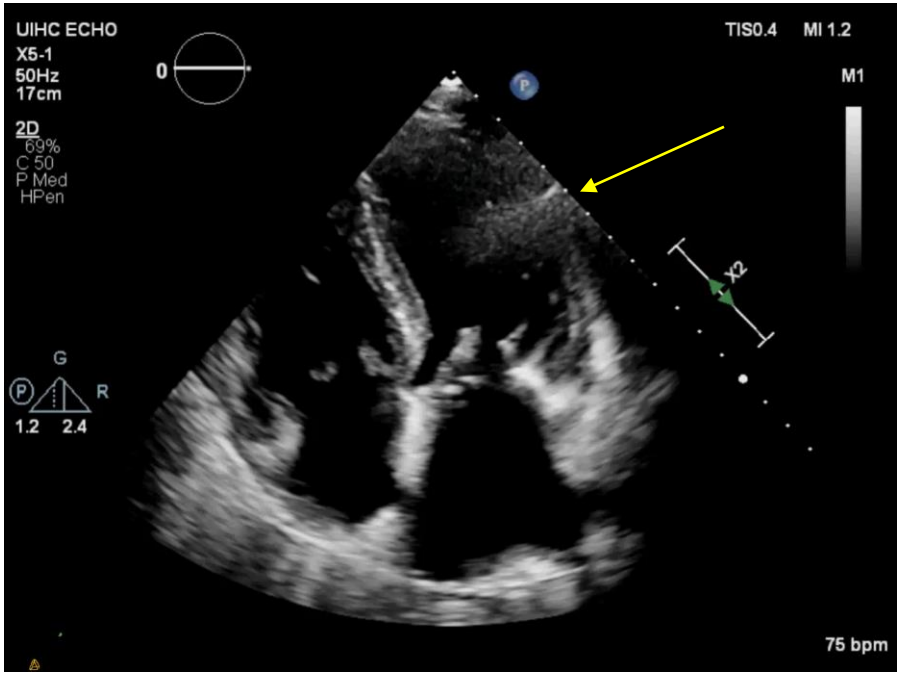

The ultrasound beam is 3 dimensional
Grating/Side lobe also come out in the elevation plane

Case

How many hearts?

Just 1

Mirror image artifact

Mirror Image

Bertrand et all, JASE, May 2016

Sound does NOT go straight down and straight back to the transducer as expected

Duplicate echoes in the wrong location, too deep

Resolved with Depth Correction

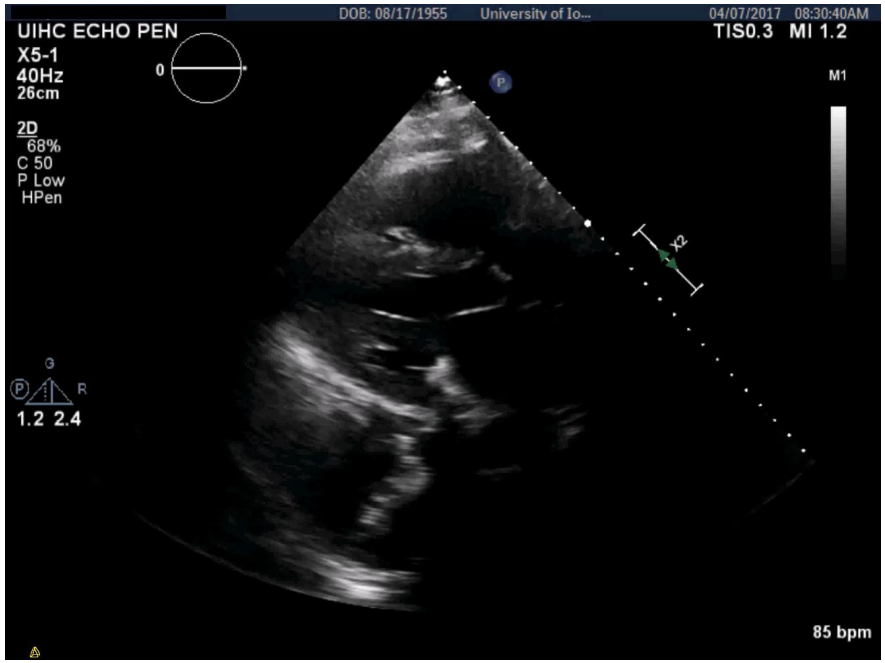

Mirror image with color Doppler

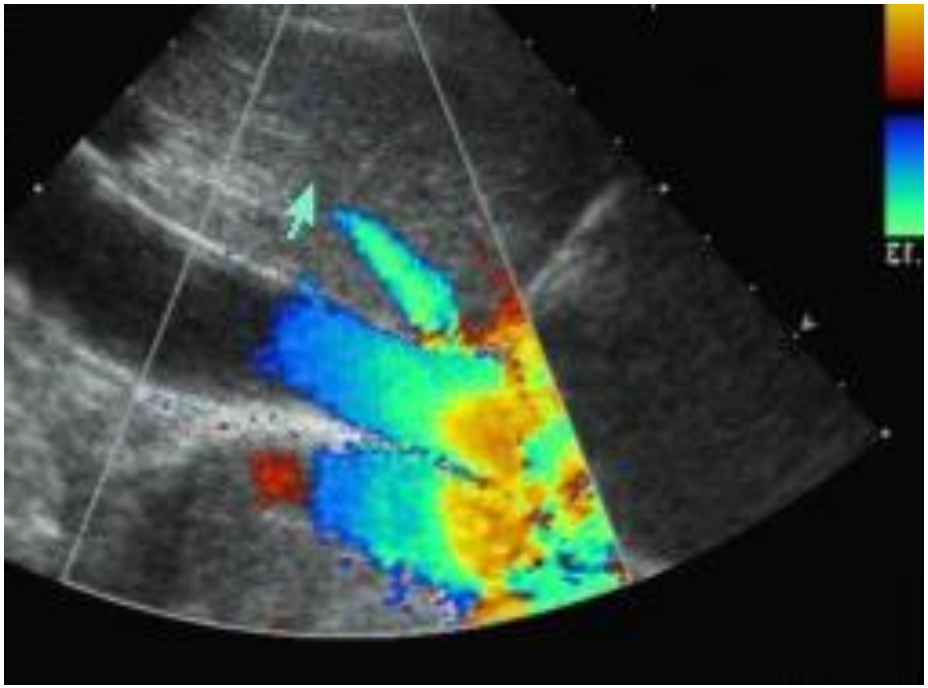

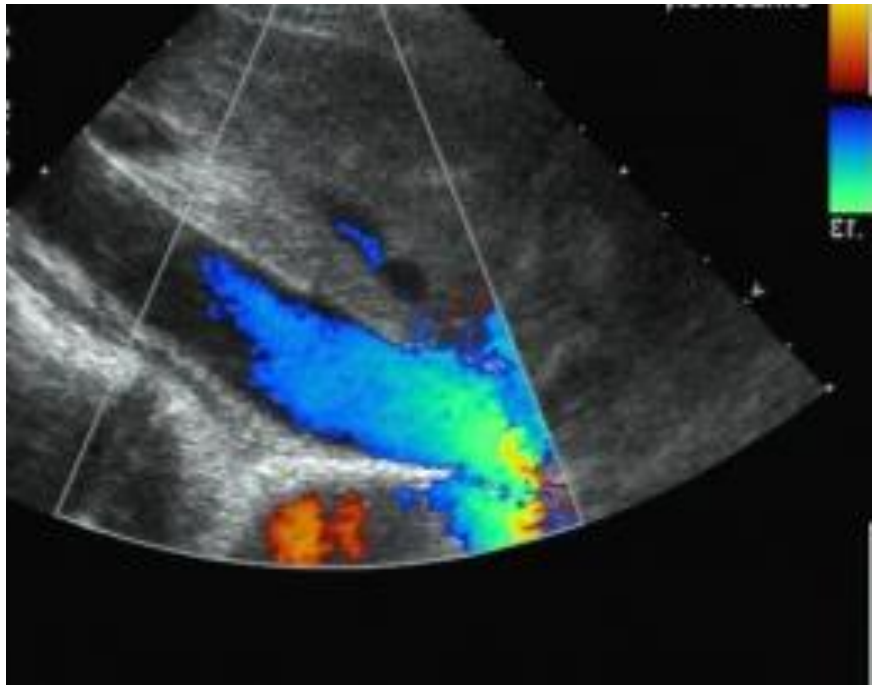

Slight angle change can improve the image and reduce the mirror image

Case

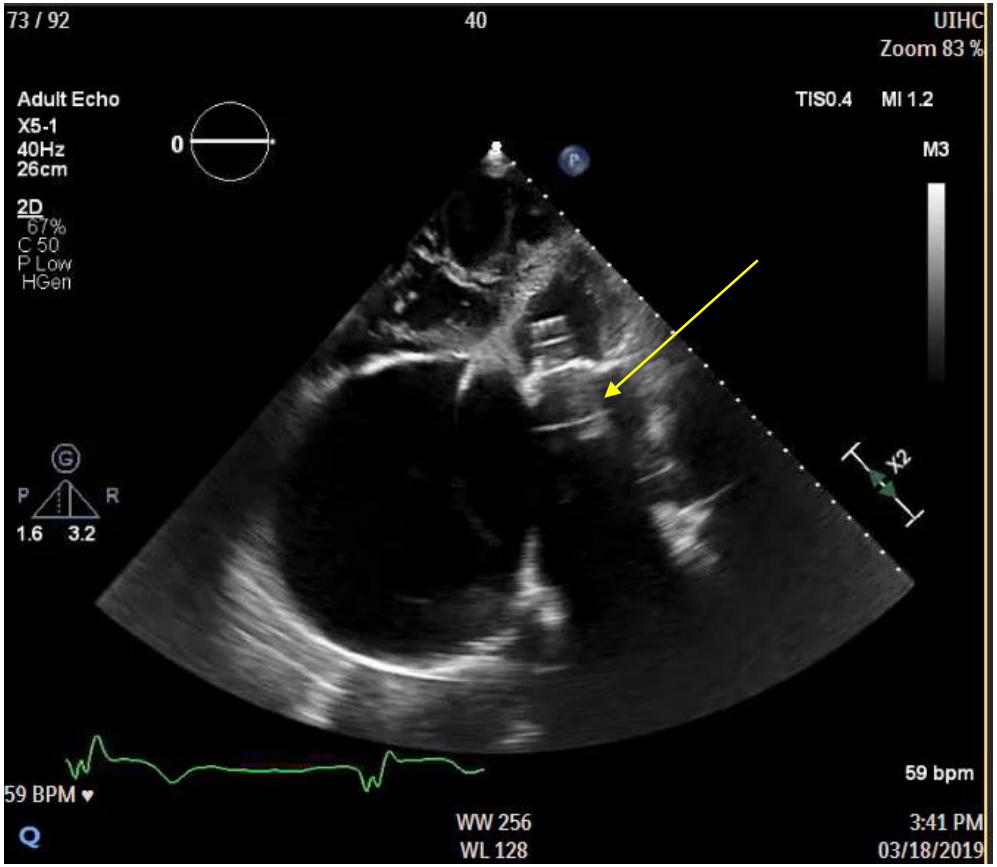

I know, there is a lot going on here…

This is an apical 4 chamber

This patient has a Starr-Edward (Ball in Cage) mitral valve placed in 1986.

The RV and RA are severely dilated

Identify the phenomenon identified by the yellow arrow

Reverberation artifact

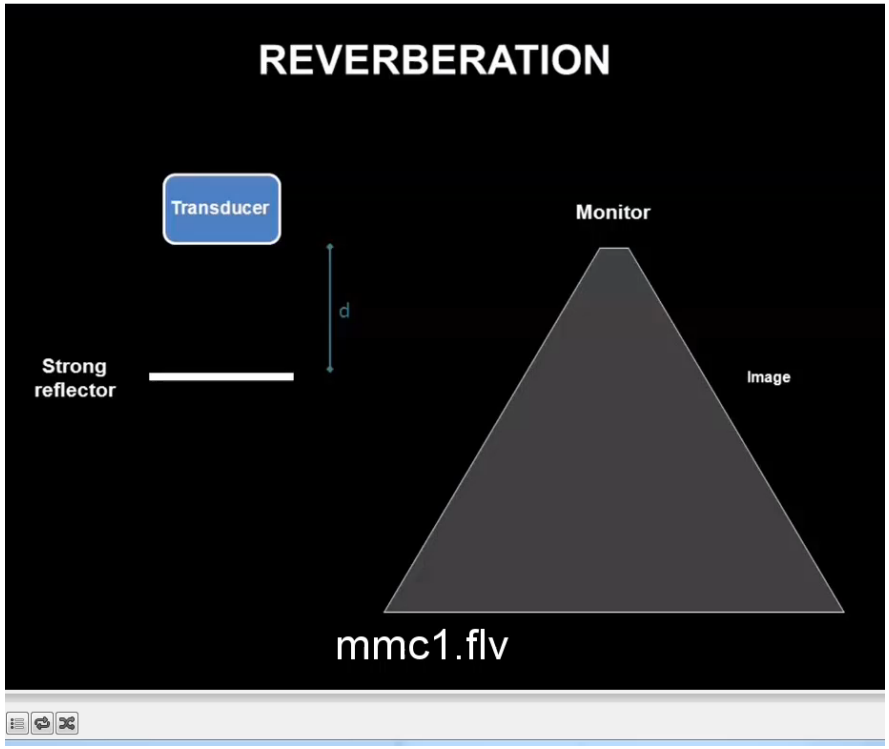

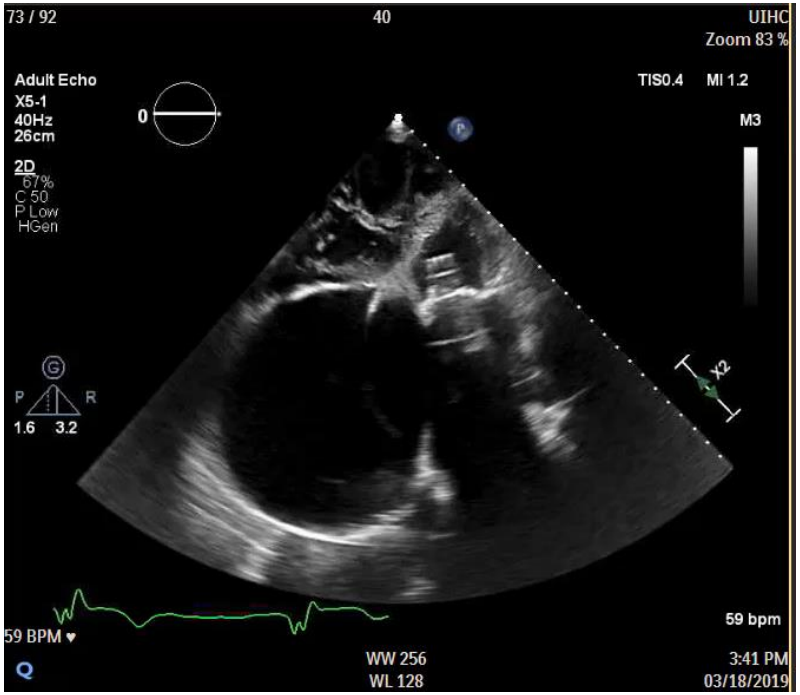

Bertrand et all, JASE, May 2016

Sound make the path to the reflector more than once, this take more time

Duplicate echoes

- Equally spaced
- Decreasing in amplitude
- Deep to the second reflector

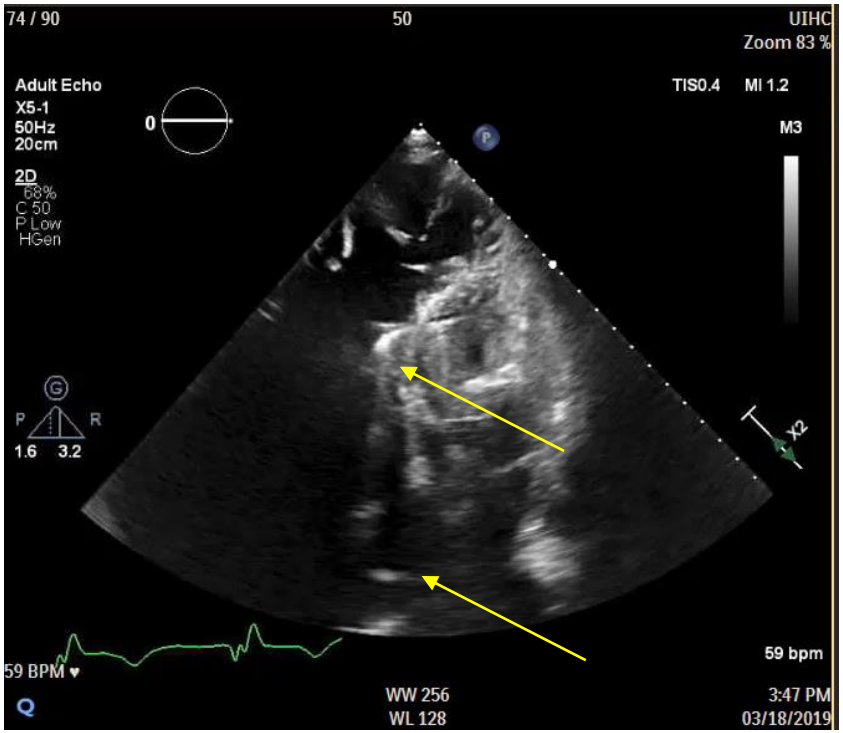

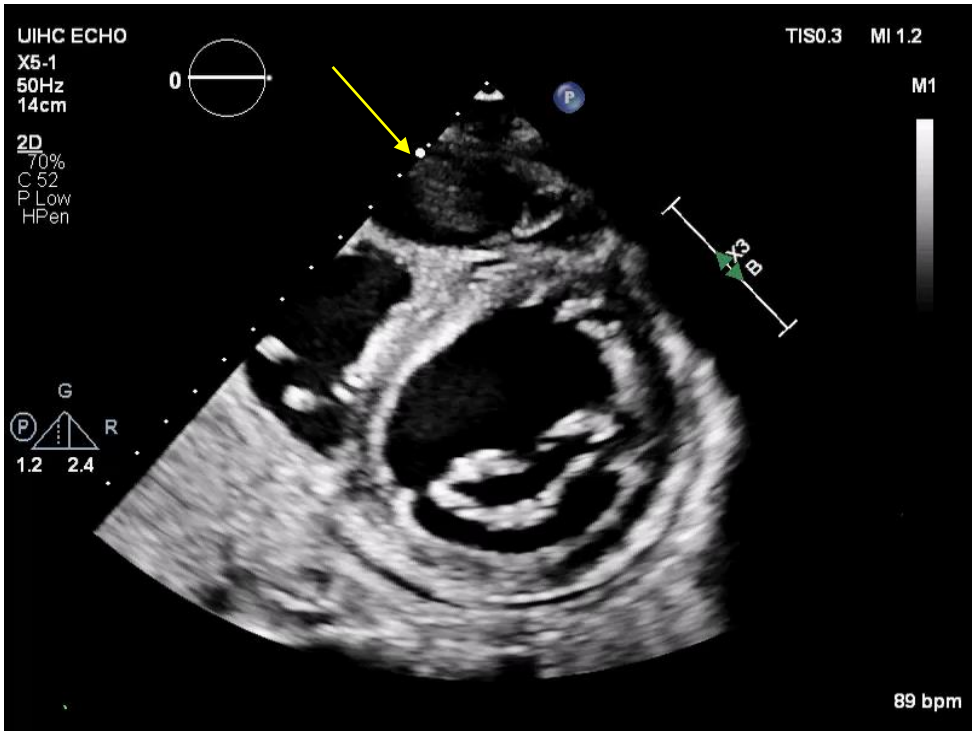

Reverberation on pacemaker wire

Reverberation in RV

Comet Tail

Comet tail (sometimes referred to as ringdown – inconsistent terminology) is a type of “short range reverberation.” Sound is bouncing between two closely spaced structures. Often seen at the lung/pleura interface and devices (pacemaker wires, MR clips, etc.)

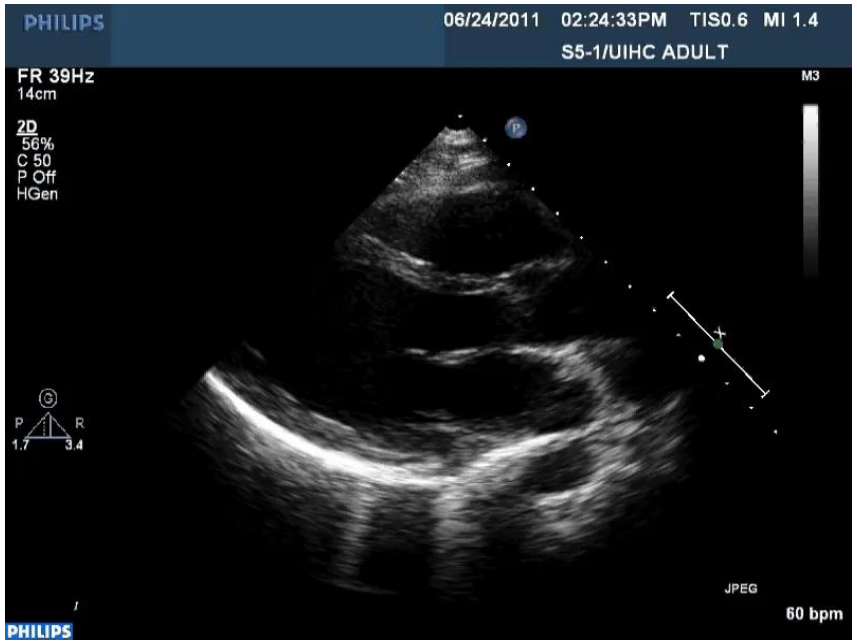

Mitraclip

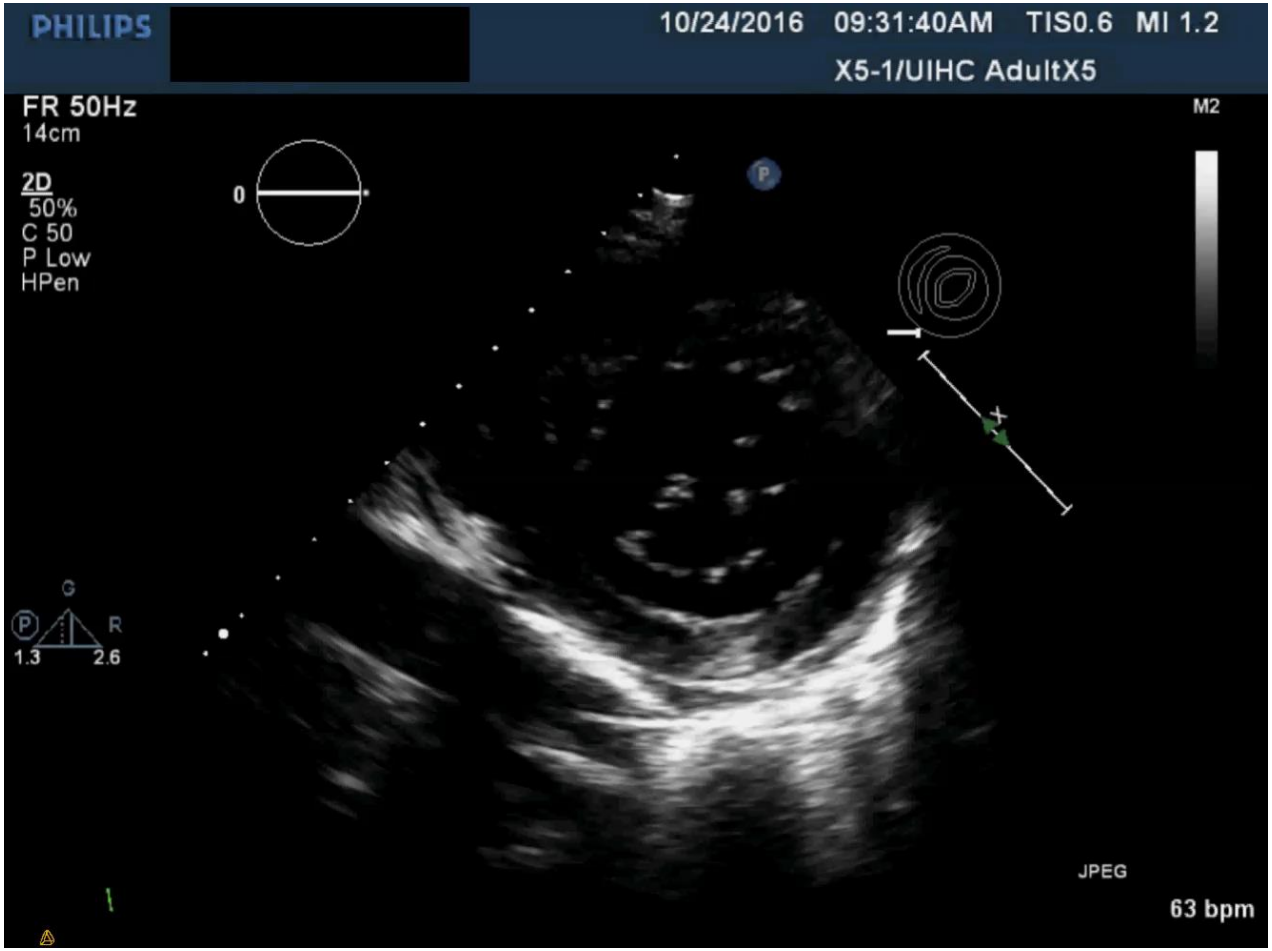
PHILIPS
[redacted]
10/24/2016 09:31:40AM TIS0.6 MI 1.2
X5-1/UIHC AdultX5
FR 50Hz
14cm
2D
50%
C 50
P Low
HPen
0
M2
G
P
R
1.3
2.6
JPEG
63 bpm

The consolidated lung results in no comet tail. Also you can see the lung.

Case

Continuing with the Starr Edwards MV case…

What phenomenon do you expect related to the Silone poppet of the valve?

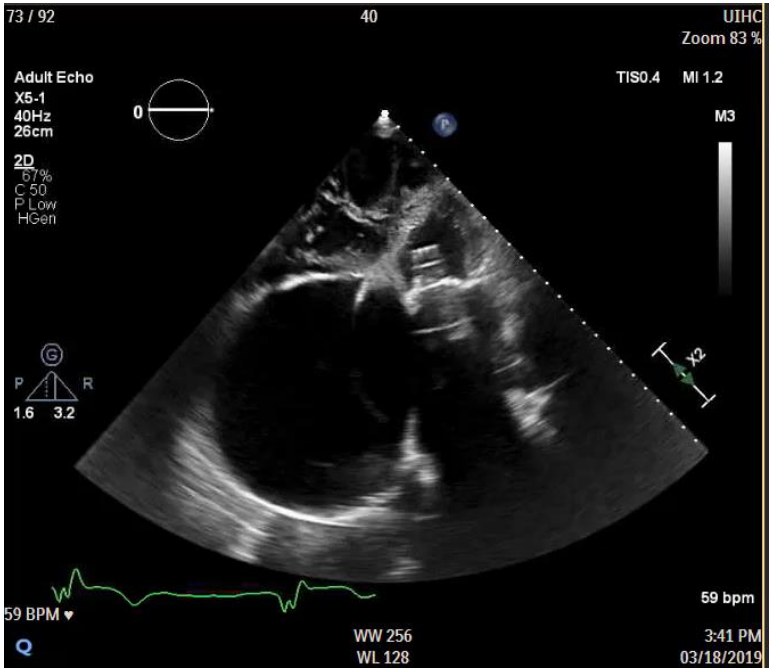

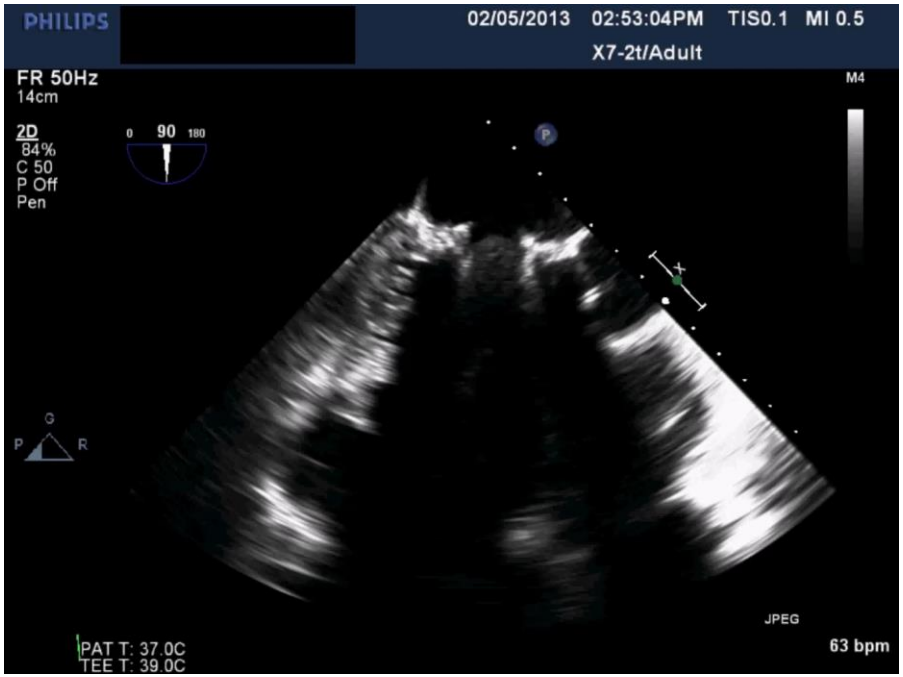

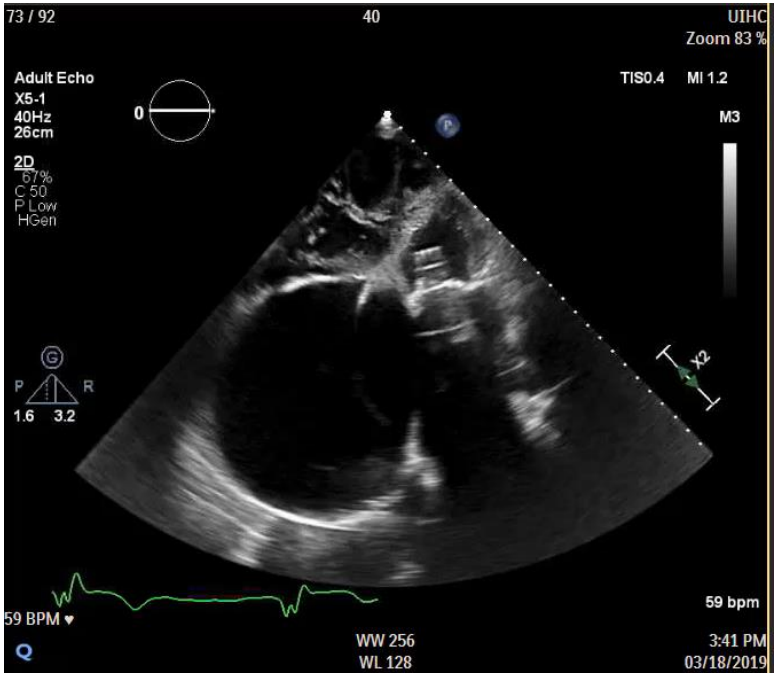

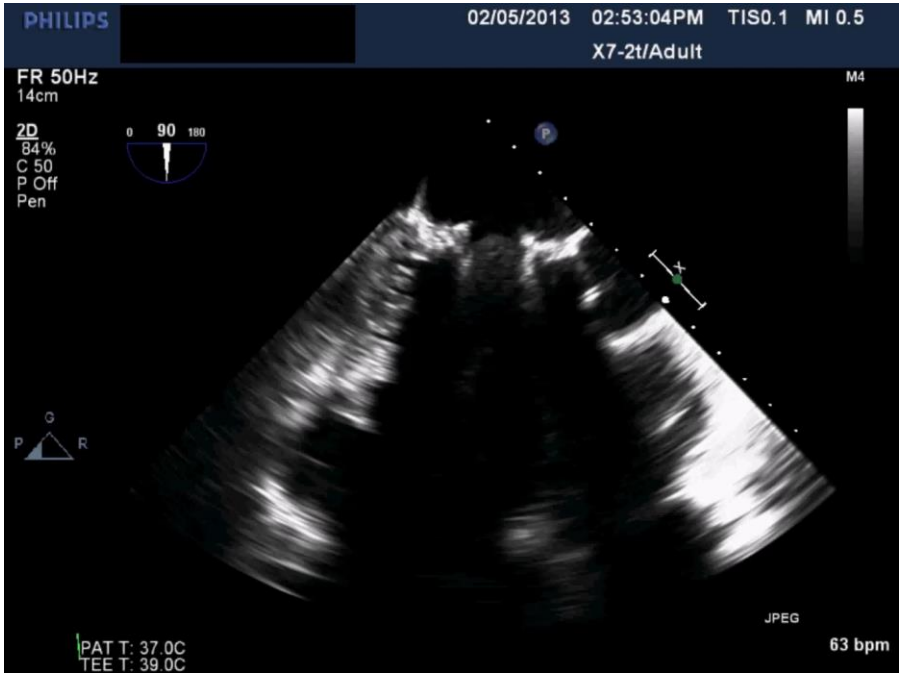

The propagation speed of the poppet is <1540 m/s

The poppet appears “oval” because the slow propagation speed displaced the deep side of the poppet further from the transducer

Can make the LA measure larger in A4ch

Case 5

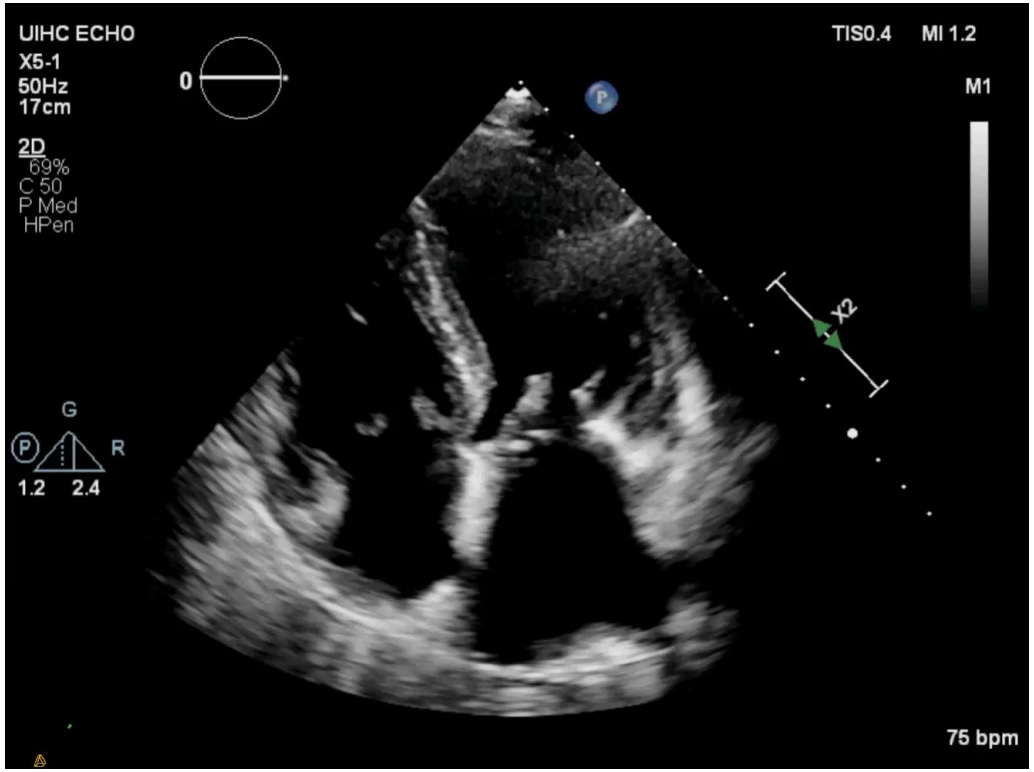

What is missing?

Artifacts can be when something is MISSING that you should see

Drop out artifact of the IAS

Must be perpendicular to see it well

Subcostal

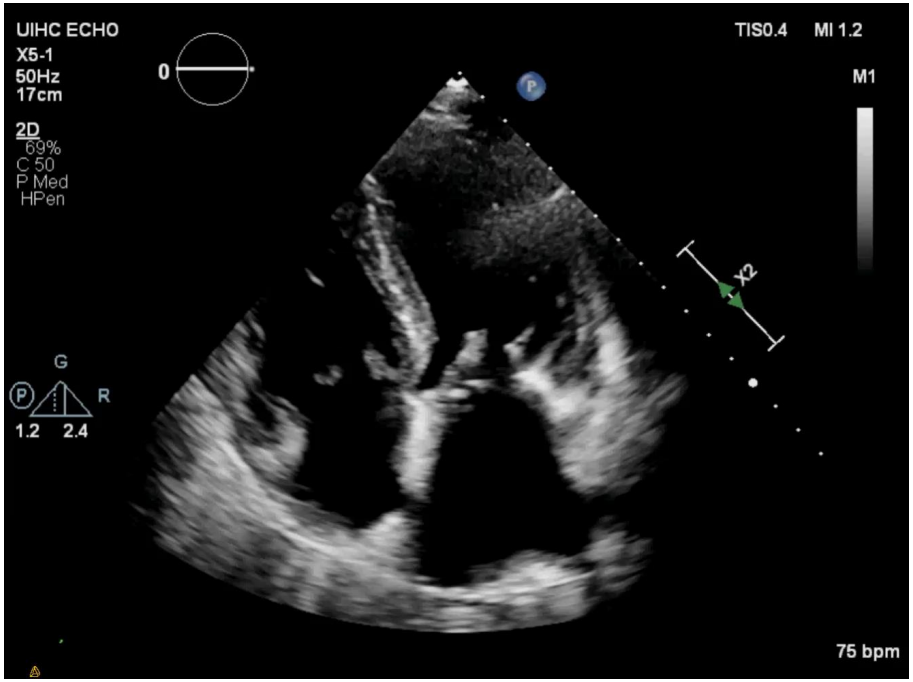

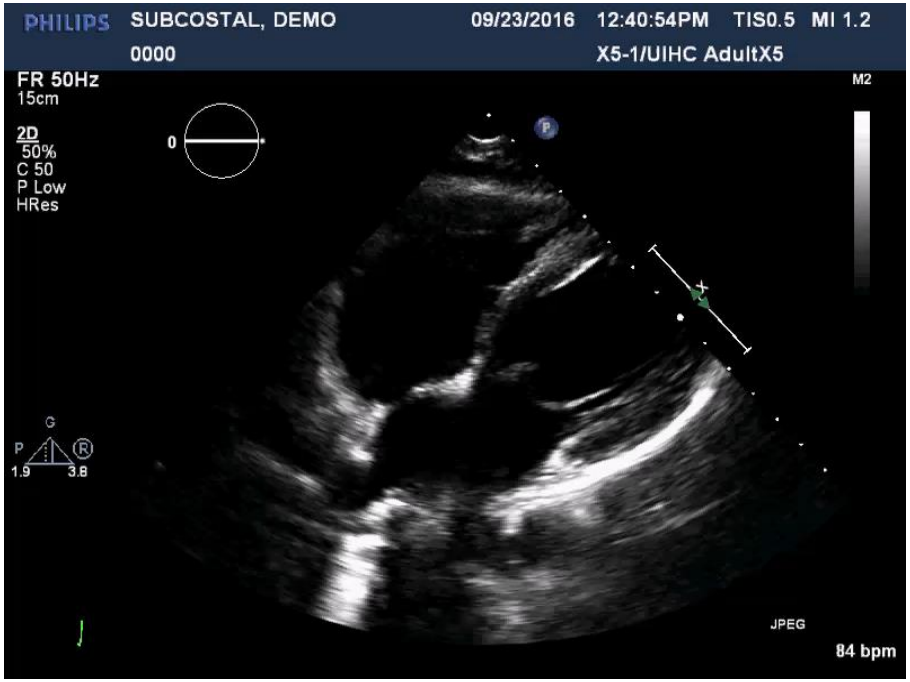

The IAS is a specular reflector
Specular reflectors need to be insonated at 90 degrees to be seen well

Types of Reflectors

- Specular reflector
  - Large, flat, smooth boundary
  - Valves, vessel walls, endocardium, pericardium

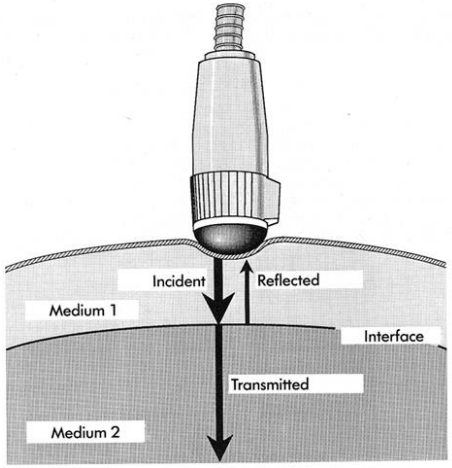

- Scatter (Diffuse, non-specular)
  - Diffusion or redirection of sound in several directions
  - Small boundaries
  - Rough surface
  - Myocardium
  - Liver

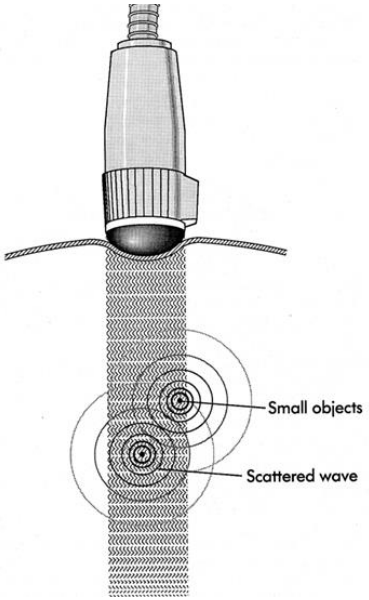

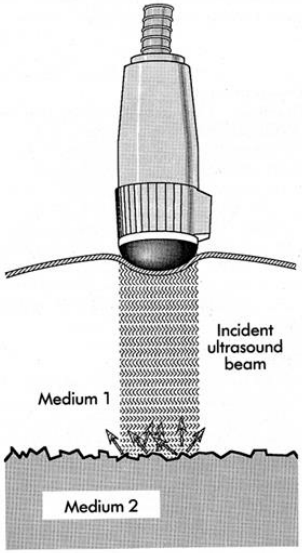

Refections

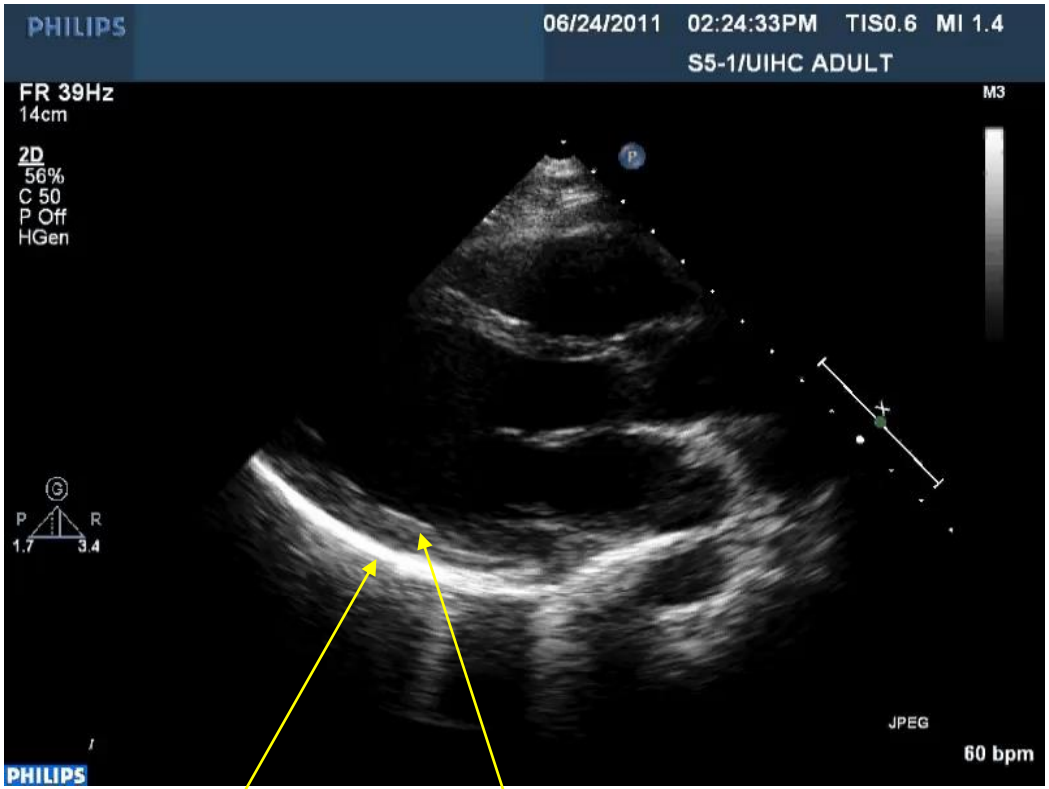

Specular Diffuse

Specular vs. Diffuse

- Specular
  - Perpendicular
  - Create artifacts
    - Missing reflections
    - Wrong location
    - Wrong amplitude
- Diffuse
  - Any angle

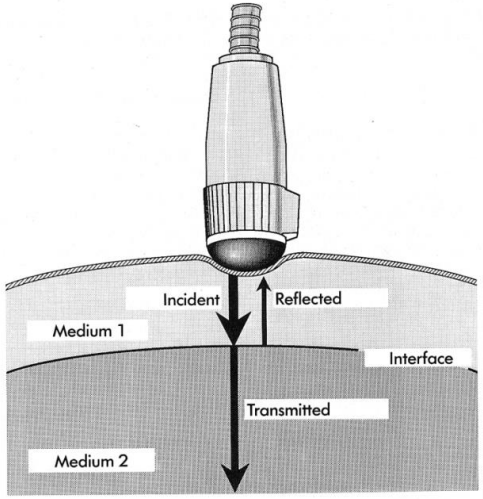

Fig. 6-8 Reflection and transmission of ultrasound beam at an interface.

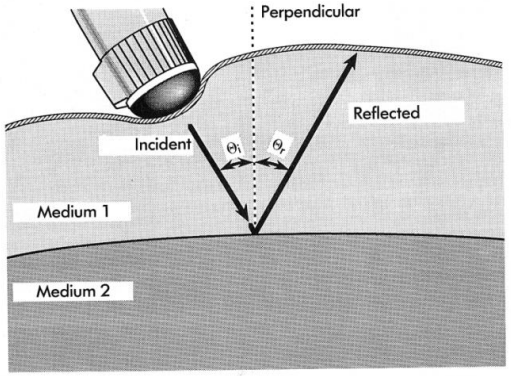

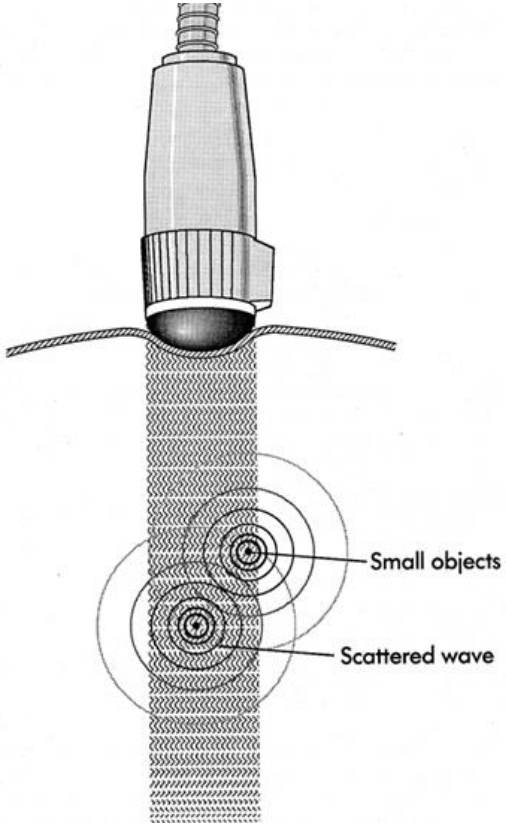

Refections

Brighter because it is at 90 degrees

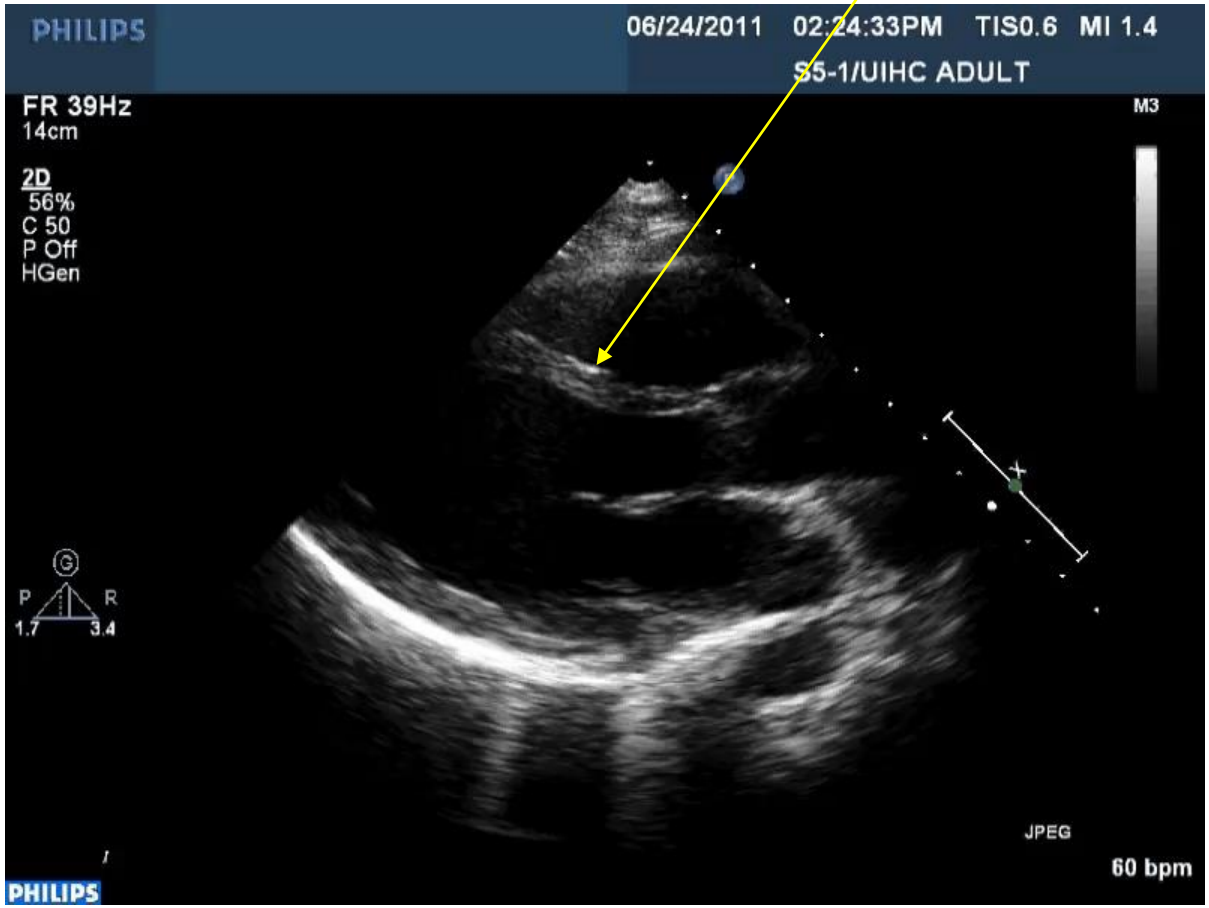

Linear measurement are done in the PLAX to be perpendicular to the wall interface (specular)

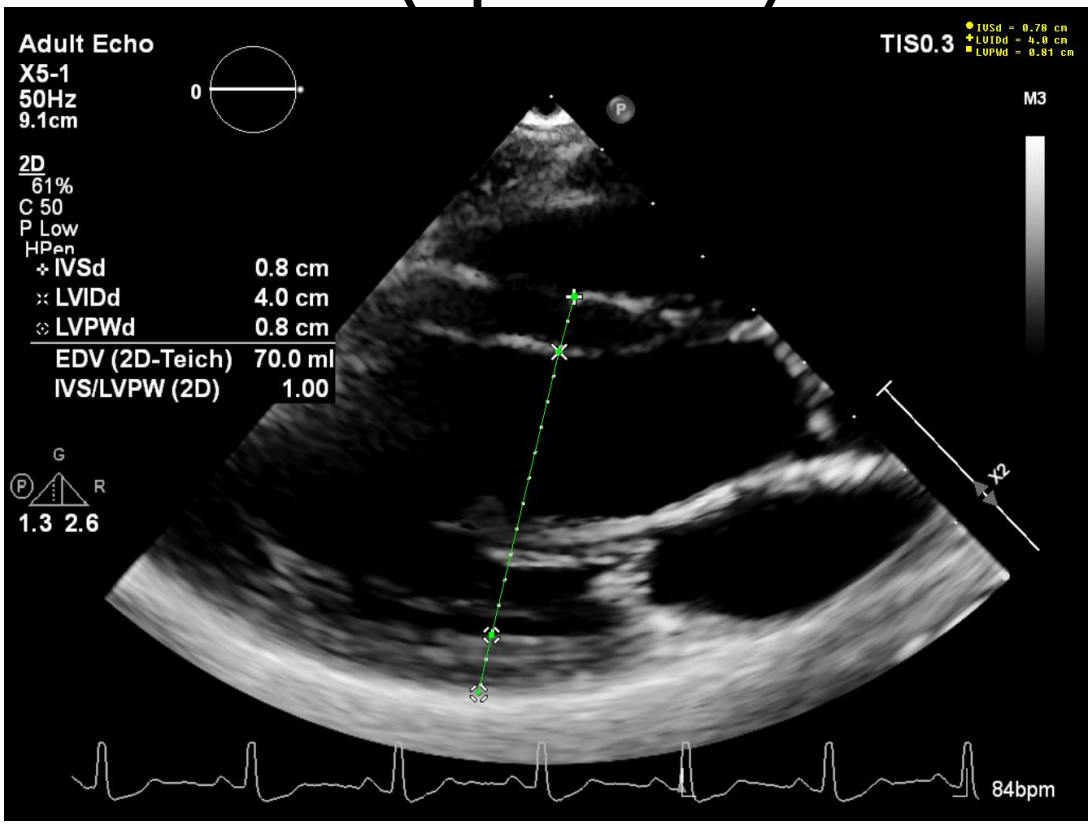

Linear measurement are done in the PLAX to be perpendicular to the wall interface (specular)

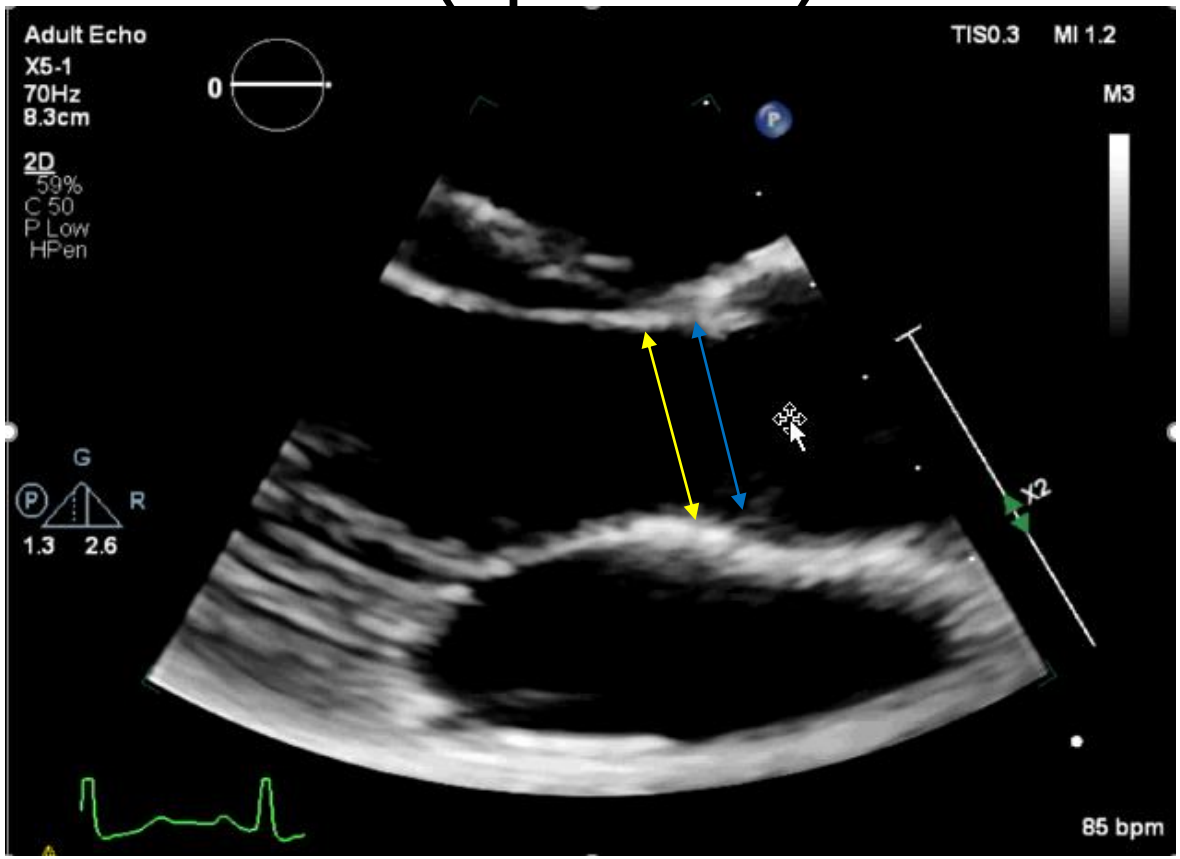

Doppler Technique

- Doppler technique is the opposite of 2D
- Doppler shift is maximum at 0 degrees
- Doppler shift is zero at 90 degrees
- To report an accurate **CALCULATED** velocity we must have an angle of less than 20 degrees
- Apical widow is most used for Doppler

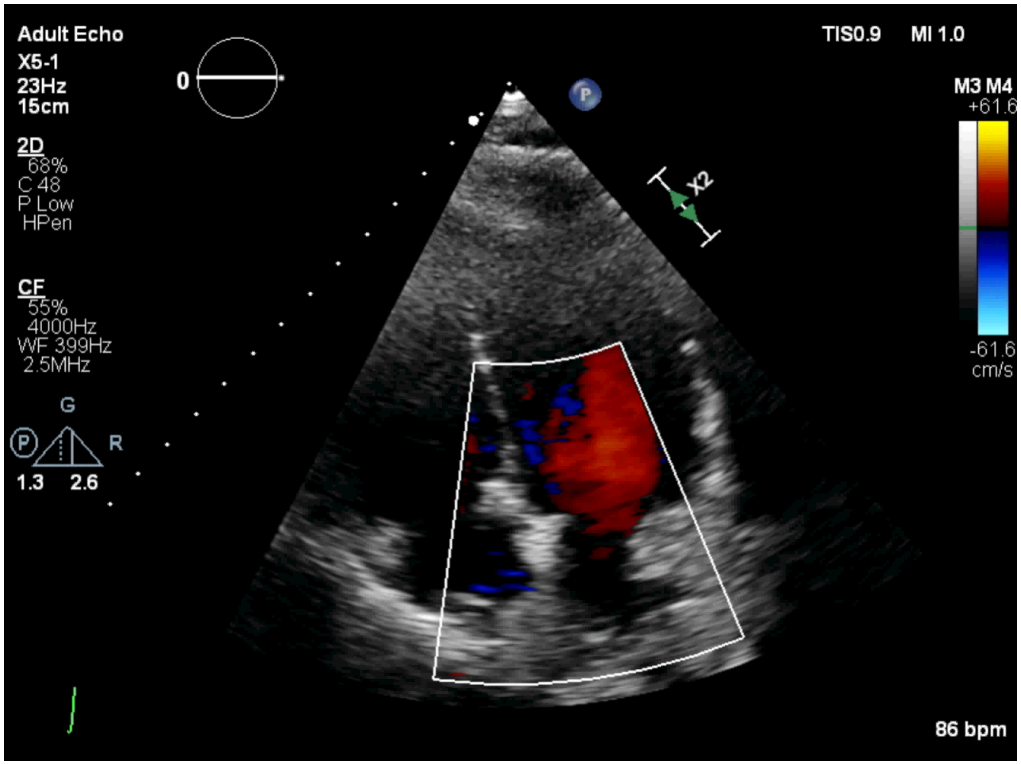

Doppler

- Change in reflected frequency compared to frequency sent out when there is motion between source and reflector

Doppler frequency = reflected frequency-transmitted frequency

$$\text{Doppler frequency} = \frac{(2 \times \text{transmitted frequency} \times \text{velocity} \times \text{Cos angle})}{\text{propagation speed}}$$

$$\textbf{Calculated Velocity} = \frac{\textbf{Doppler Shift} \times \textbf{propagation speed}}{\textbf{2} \times \textbf{transmitted frequency} \times \textbf{Cos angle}}$$

Doppler

- Amount of change dependent on velocity of reflector, transmitted frequency and angle between source and reflector
- **Doppler shift increases with:**
  - **Increase velocity of reflector**
  - **Increase frequency of transducer**
  - **Make angle closer to 0 degrees (parallel)**
- No Doppler shift at 90 degrees

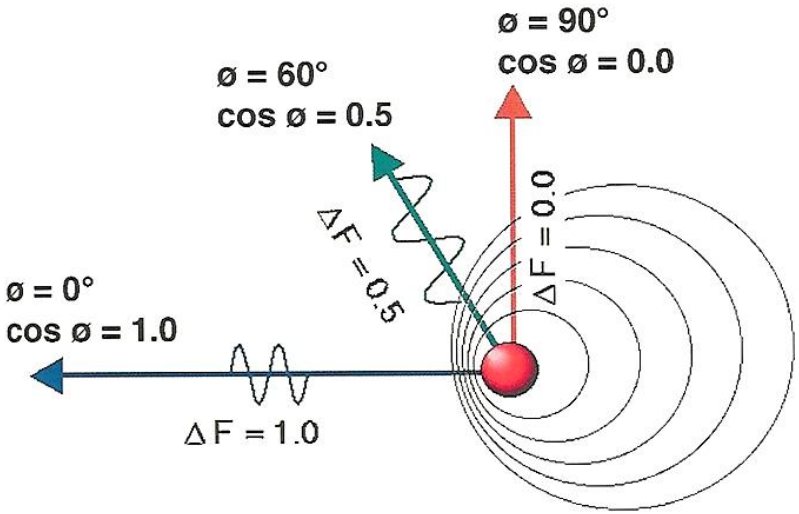

This is what happens if the angle is 0 degrees.
The DS is maximum, Cos of angle is 1 so no effect on velocity calculation, accurate and maximum calculated velocity

$$\text{Velocity (m/s)} = \frac{\text{DS(MHz)} \times \text{C(m/s)}}{2 \times \text{Transmitted Frequency (MHz)} \times \text{Cos}}$$

(1)

This is what happen if you do NOT angle correct.
The DS decreased, no adjustment for Cos of angle, so calculated velocity

$$\text{Velocity (m/s)} = \frac{\text{DS(MHz)} \times \text{C(m/s)}}{2 \times \text{Transmitted Frequency (MHz)} \times \cancel{\text{Cos}}}$$

In Echo we keep the angle <20° to minimize this effect

FYI – other vascular imaging requires angle correction

This is what happens if the angle is 60 degrees and you angle correct. The DS is decreased, Cos of the angle is .5 to adjust for the DS reduction, so the calculated velocity increased (from what is would have been without angle correction) to a more accurate calculated velocity

$$\text{Velocity (m/s)} = \frac{\text{DS(MHz)} \times \text{C(m/s)}}{2 \times \text{Transmitted Frequency (MHz)} \times \underset{(.5)}{\text{Cos}}}$$

Think of this as off-setting functions. The DS decreased the calculated velocity; the Cos of the angle increased the calculated velocity. So you're left with a balanced equation with an accurate velocity.

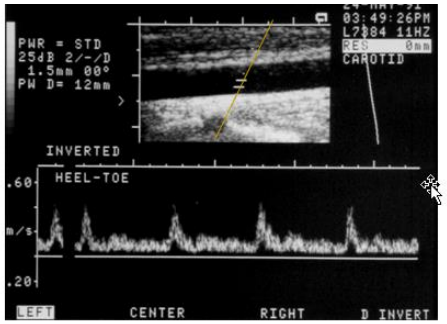

No angle correction

Displayed "velocity" approximately .5 m/s

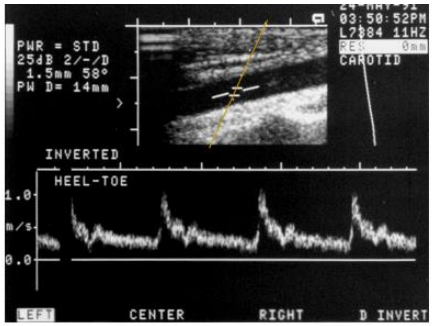

With angle correction

Calculated velocity is approximately 1 m/s

LOVT with Color – same scale

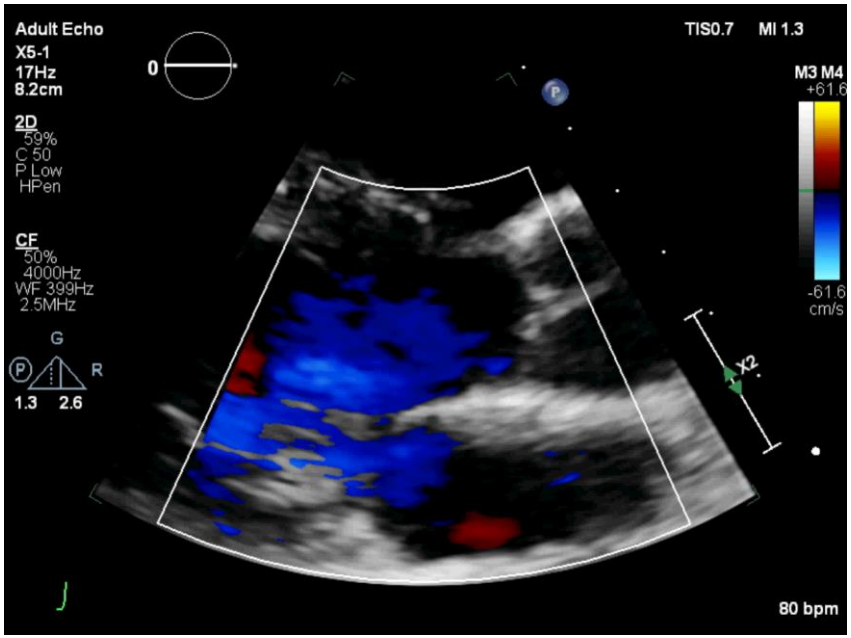

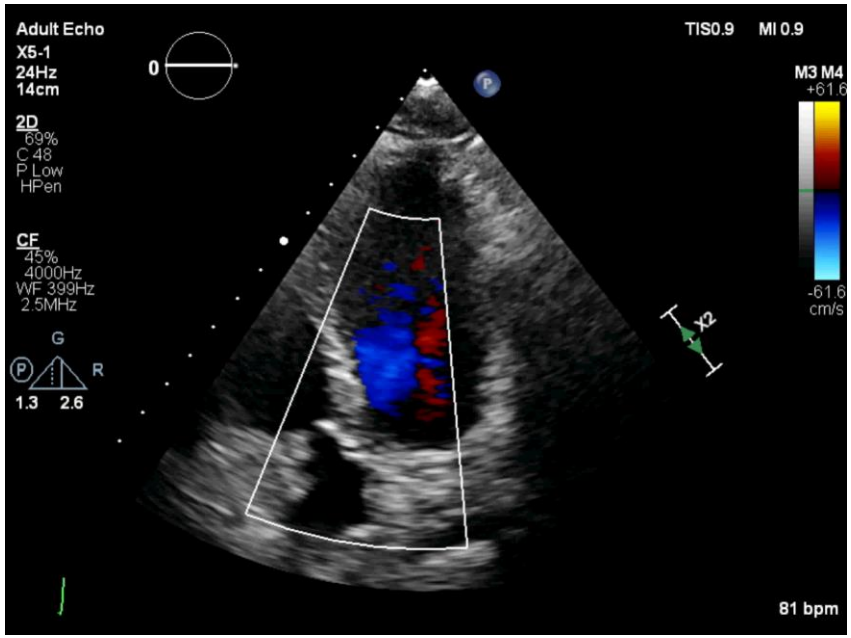

PLAX is 90 degree
Less Doppler shift
No aliasing

A5ch is close to 0 degree
More Doppler shift
Aliasing

Doppler Angle – Velocity Vector

- If direction of reflector is not parallel to direction of sound the DS will be reduced
- This will reduce the calculated velocity, underestimating pressure gradients
- We use different windows to get angles of <20 degrees to minimize this effect
- Angle of 60 degrees will result in 50% reduction in velocity calculation
- Angle of 45 degrees is roughly a 30% deduction

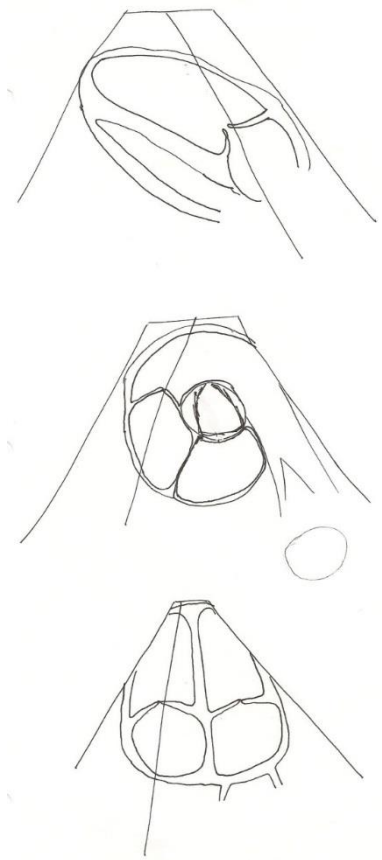

TR from 3 windows

Use only the highest velocity to calculate the PG.

Velocity Error due to Angle

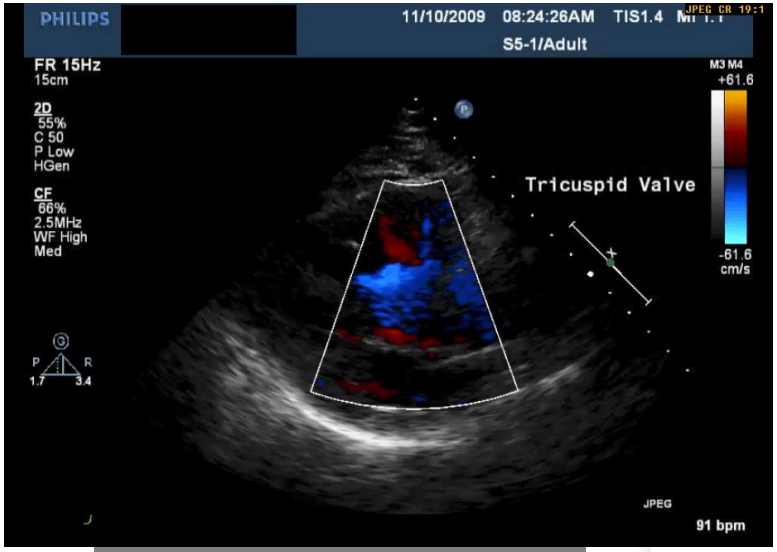

PLAX RV inflow is best angle

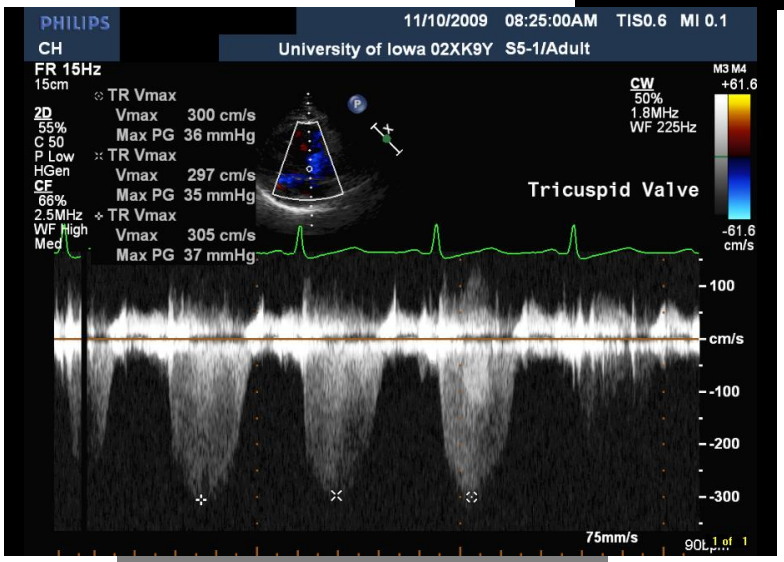

PLAXRV inflow is highest velocity

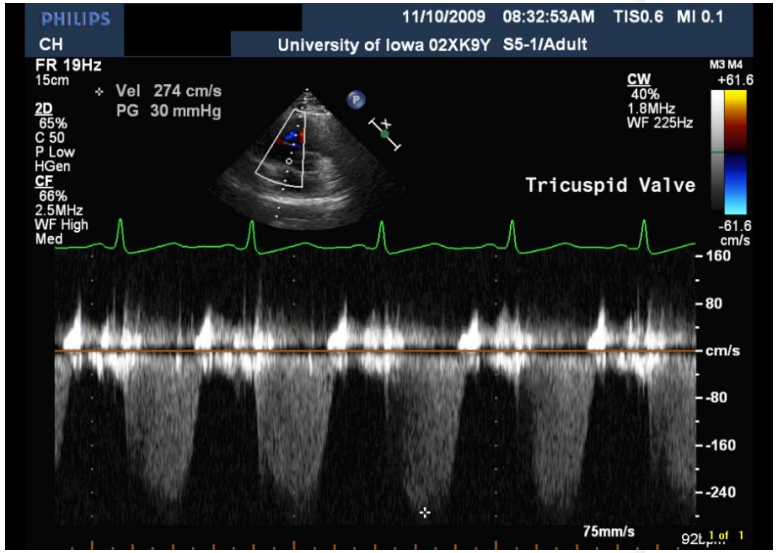

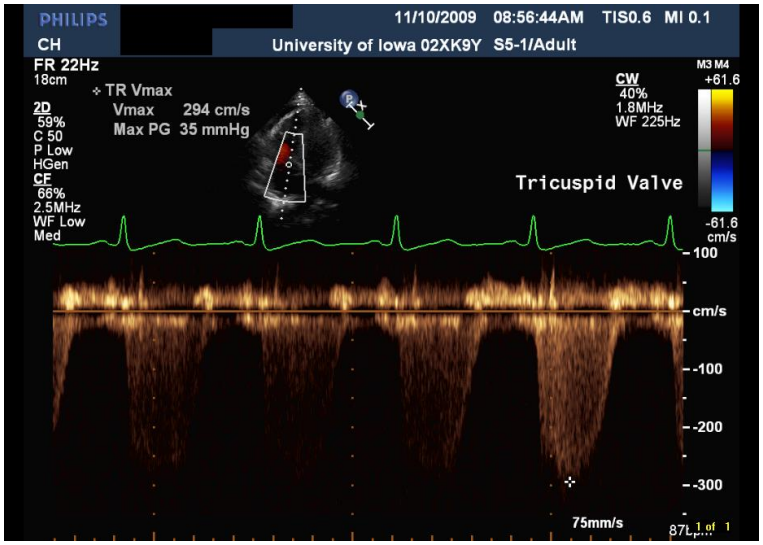

What is another scenario that we assess velocity from multiple windows?

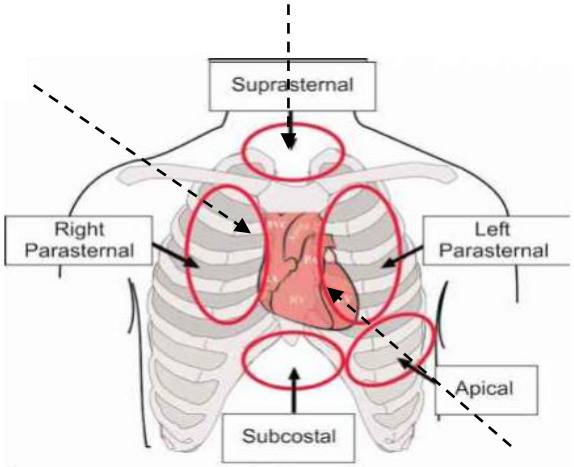

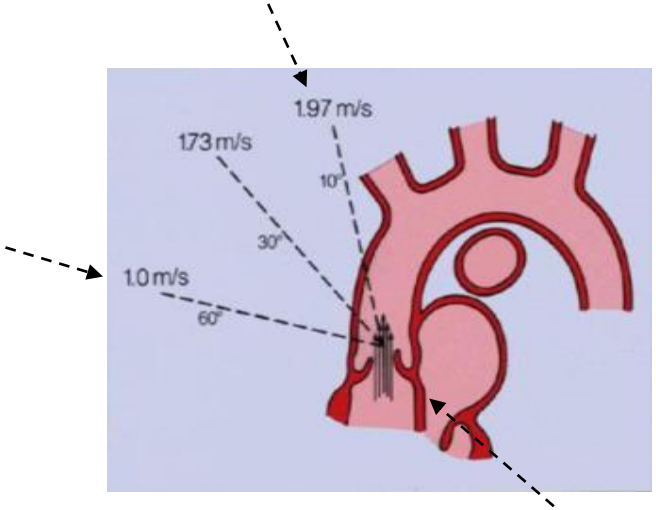

Aortic stenosis must be evaluated with Pedoff transducer

- Smaller footprint provides for better angle to stenotic jet

From 3 windows

- Apical
- Right parasternal
- SSN

Highest calculated velocity from the window closest to 0°

Non-imaging CW

- Pedoff
  - Continuous wave (blind)
  - Smaller footprint to better angles
  - Used
    - AS – Apical, Rt Parasternal, SSN
    - All prosthetic or repaired valves
      - Aortic as above
      - MV apical only

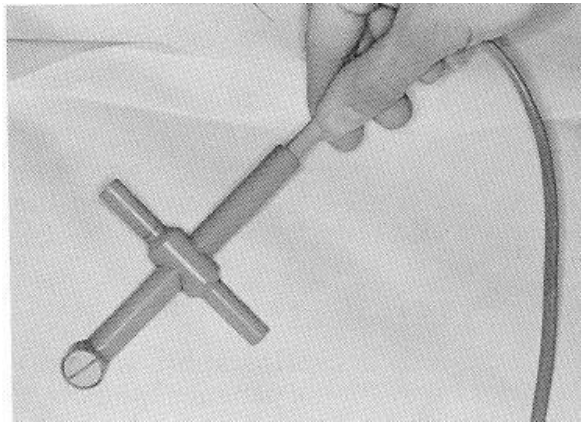

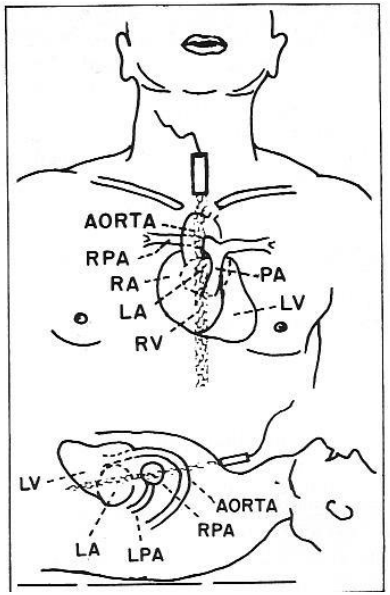

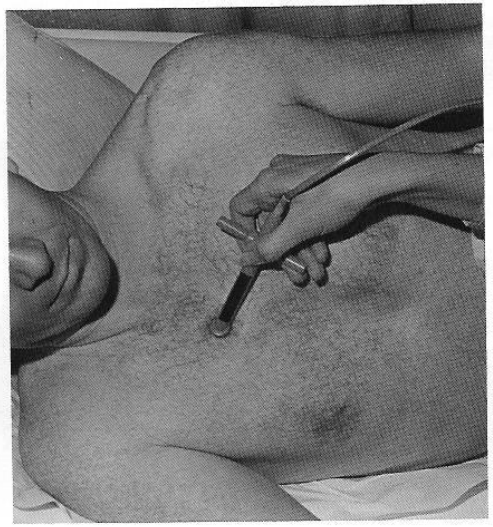

Case

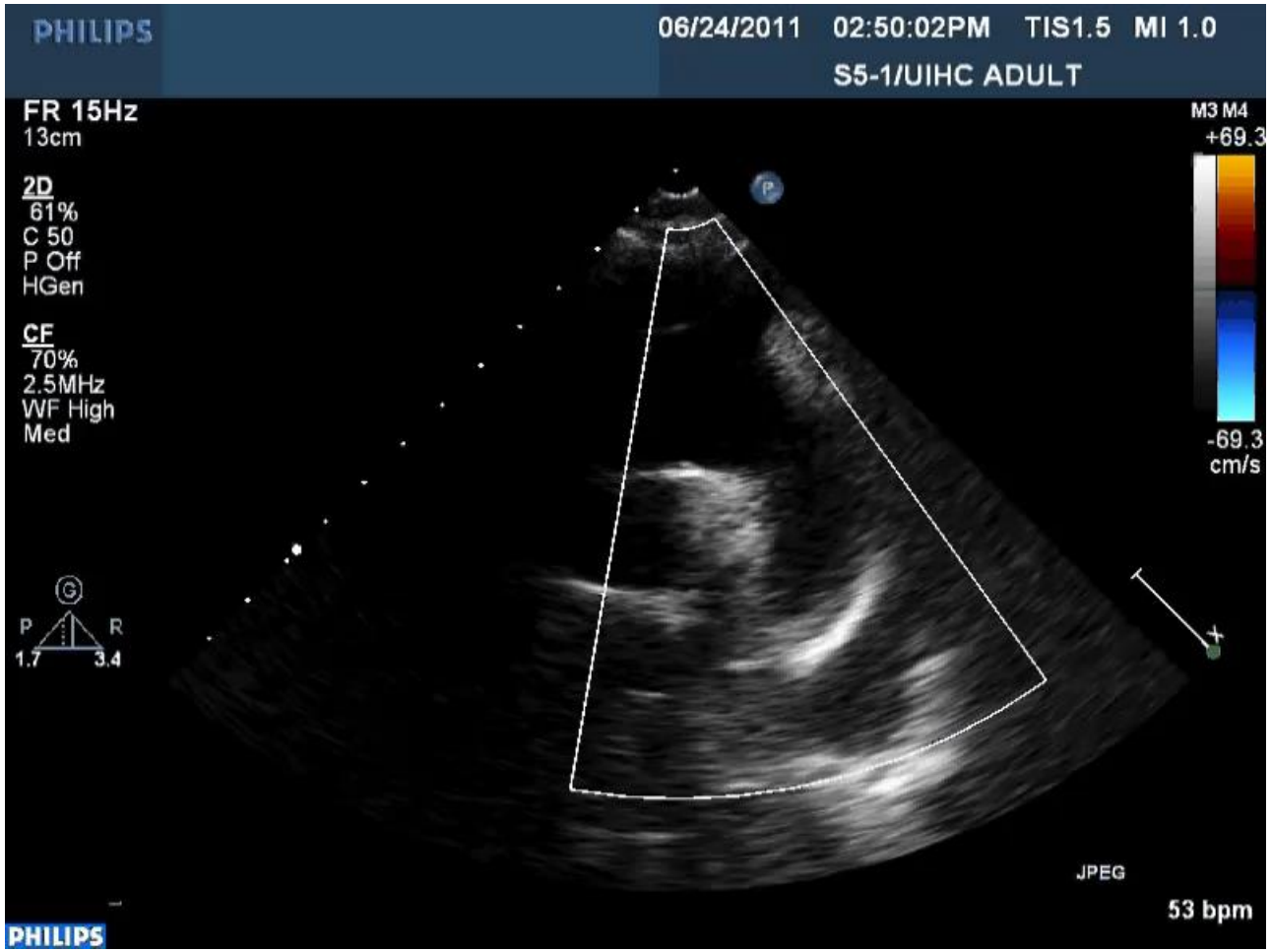

Can you identify two artifacts with the color Doppler?

Color Aliasing

- Aliasing artifact occurs when the pulsing rate (PRF) is too slow for the DS frequency being sampled
- Causes the flow to be displayed on the wrong direction
- Aliasing occurs if the DS exceeds
  - **Nyquist Limit** – max DS that can be sampled accurately
  - NL = ½ PRF
- PRF is limited by depth
- Increasing the depth will decrease the maximum PRF possible, resulting in aliasing at a lower DS

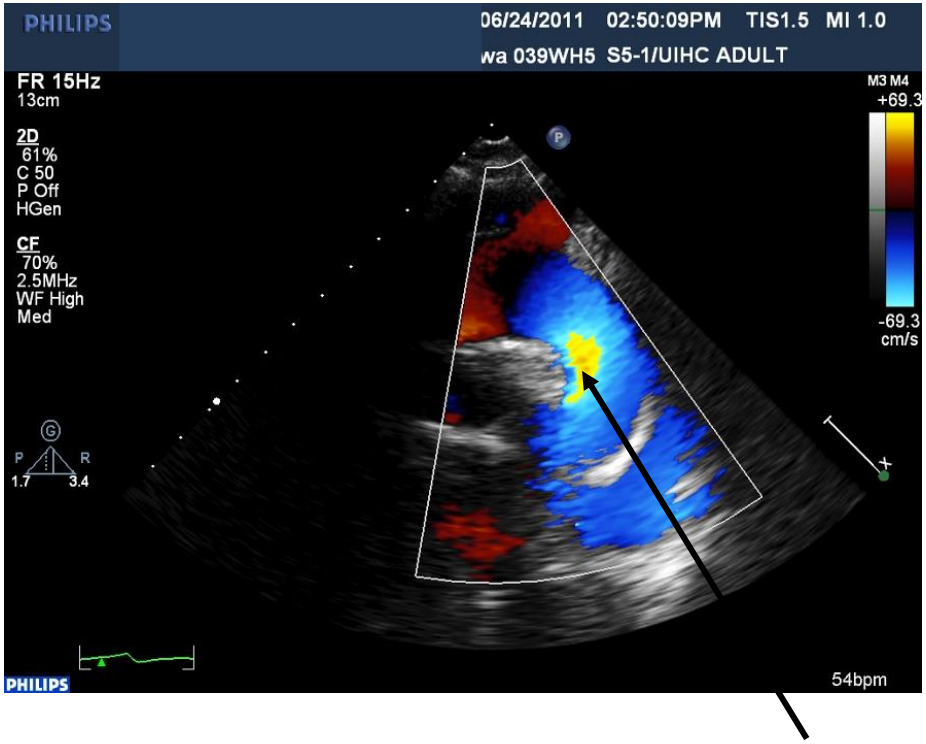

Color Mirror Image

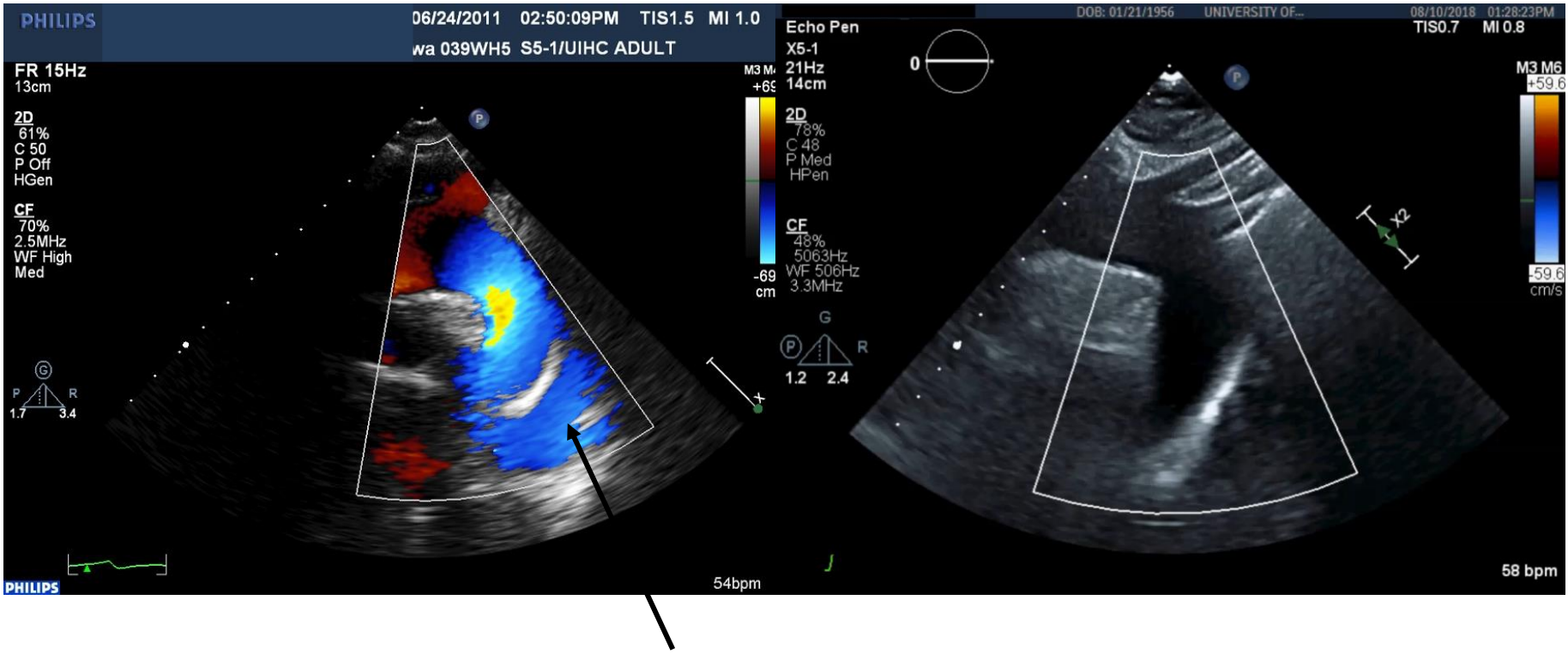

As we have already discussed

Case

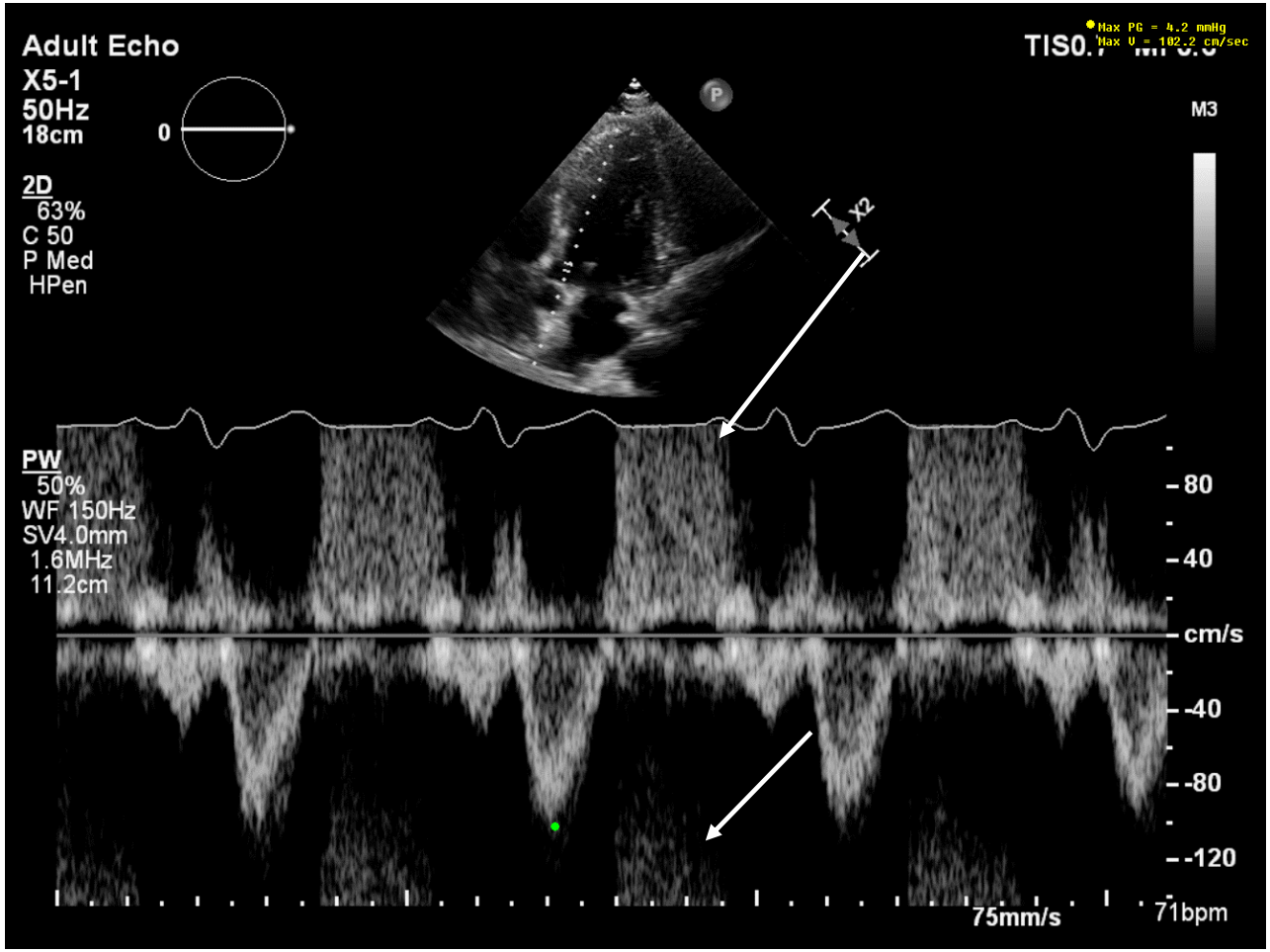

What is the Doppler artifact?

Aliasing

- PRF is too slow for the DS frequency being sampled
- DS exceeds Nyquist Limit
- How to eliminate
  - Baseline (cut and paste)
  - Increase scale (PRF) – this is limited by depth
  - Decrease DS by decreasing the operating frequency of the TB (already decreased by design)
  - CW Doppler
  - HPRF

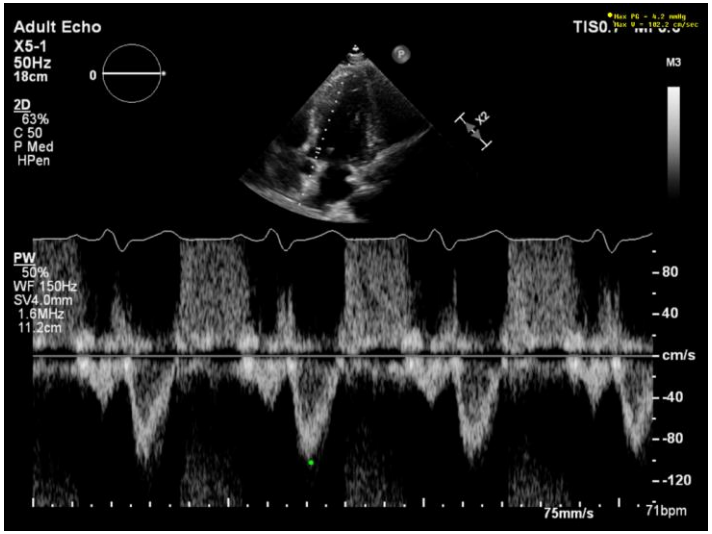

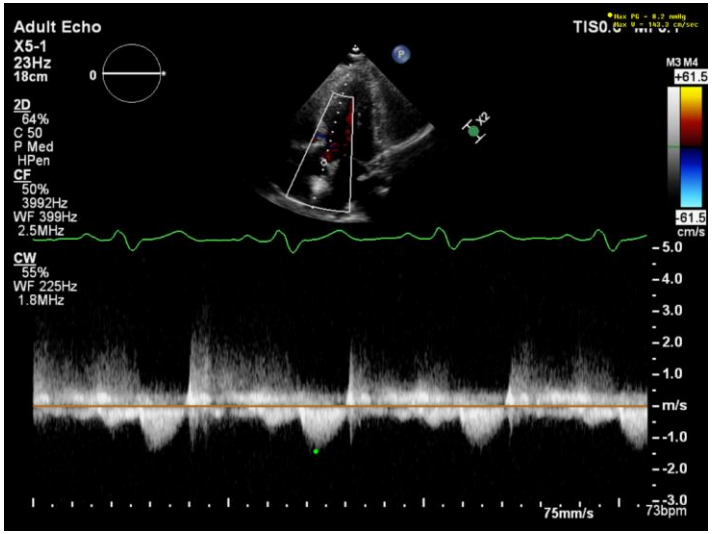

LVOT PW – Aortic Valve CW

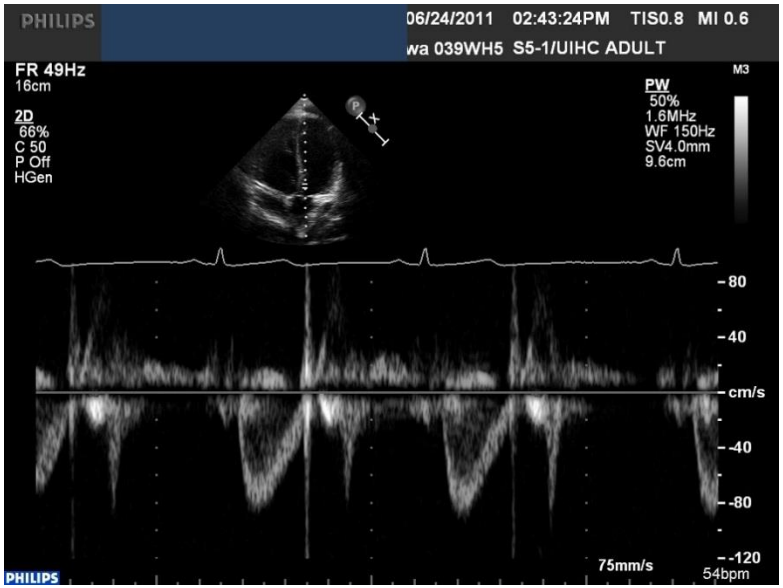

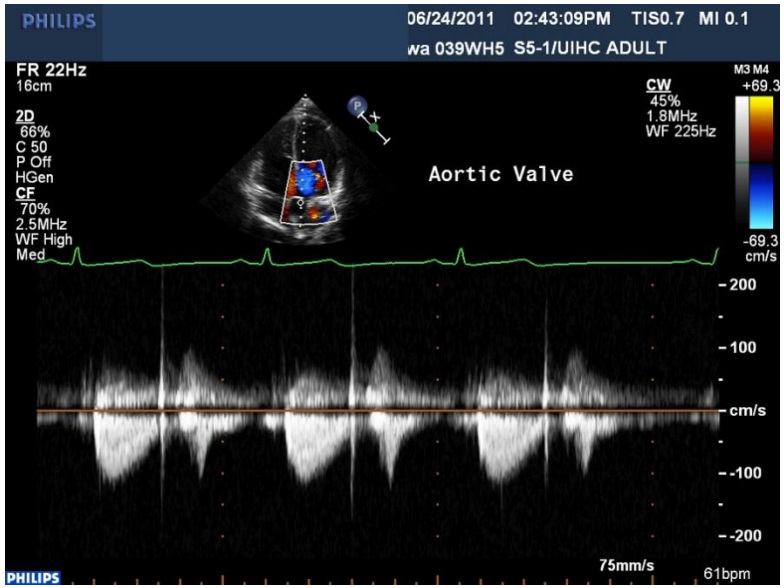

LOVT with PW
1 m/s

Aortic Valve with CW
1 m/s

Typical placement of sample gate for LVOT velocity,
0.5 cm proximal to the valve

LV Midcavity Obstruction

With LVOT or Midcavity obstruction the CW is used to identify the PEAK VELOCITY and the PW is used to identify the LOCATION (Depth).

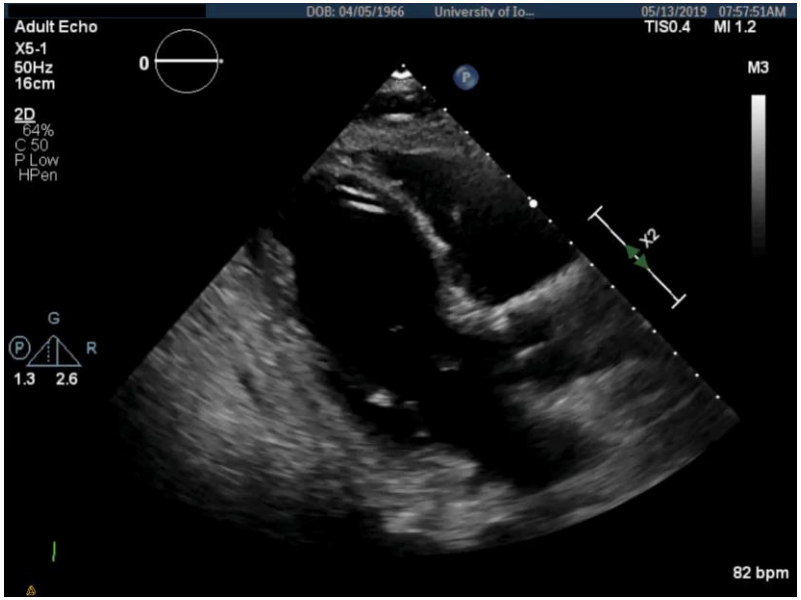

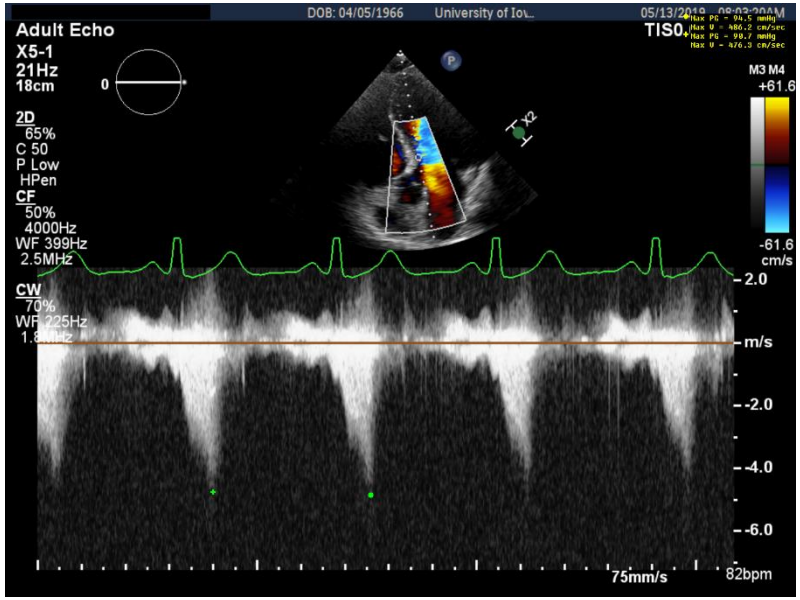

5ch with CW, 5 m/s – but where?

“Step Through” with PW

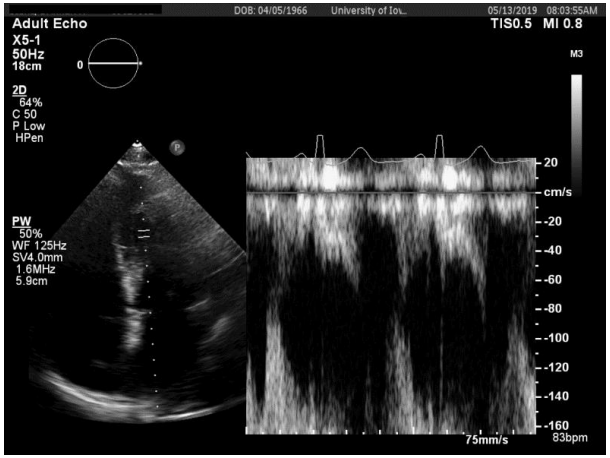

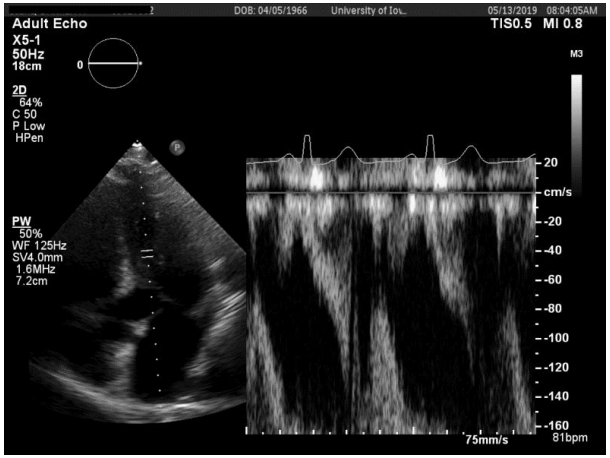

PW at various locations to demonstrate LOCATION of the highest velocity

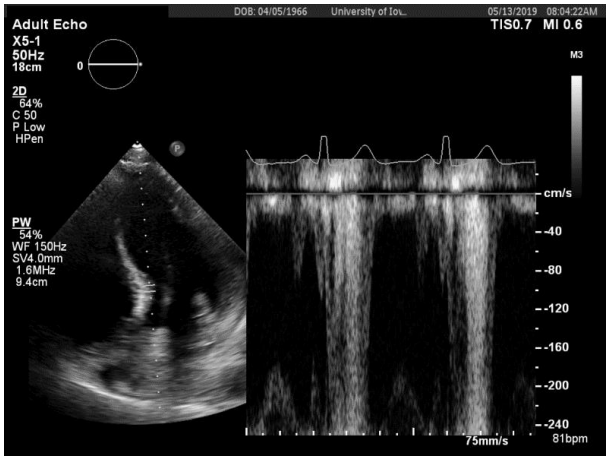

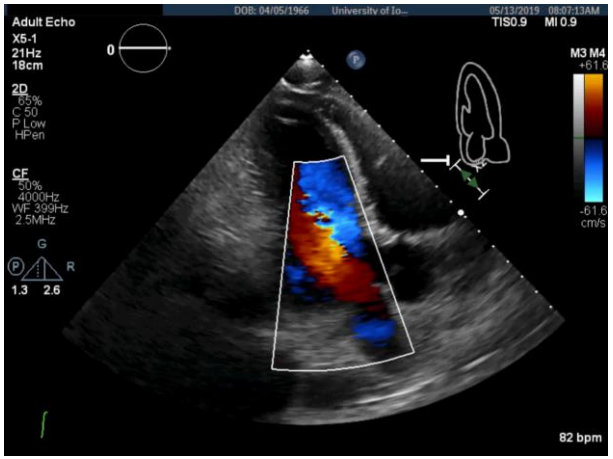

High PRF (HPRF)

- Doppler approach that intentionally pulses too fast, creating range ambiguity
- Advantages – eliminates aliasing and allows for velocity measurement with PW
- Disadvantage – multiple sample gates with risk of contamination
- Uses in echo are rare – LVOT or midcavity obstruction with concurrent AS

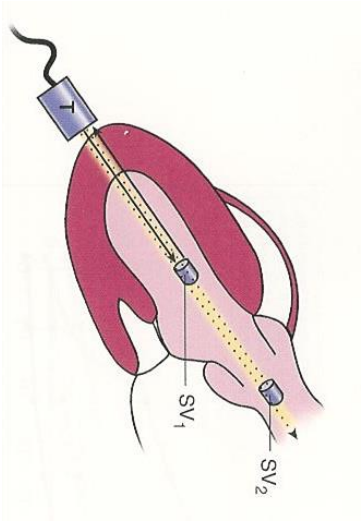

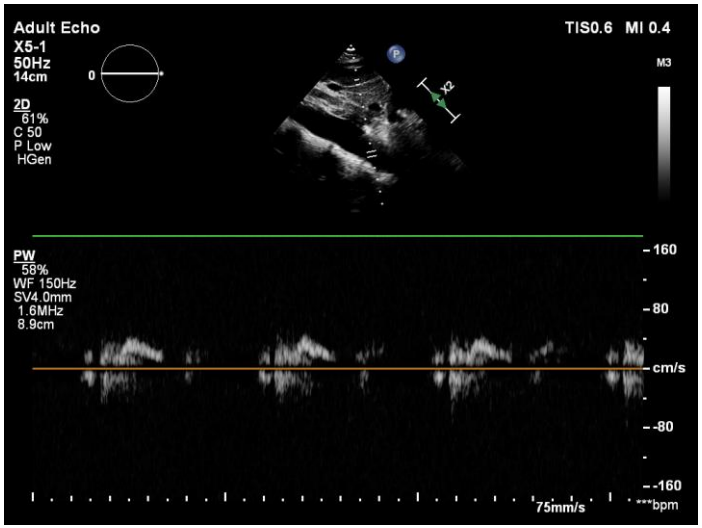

HOCM and AS

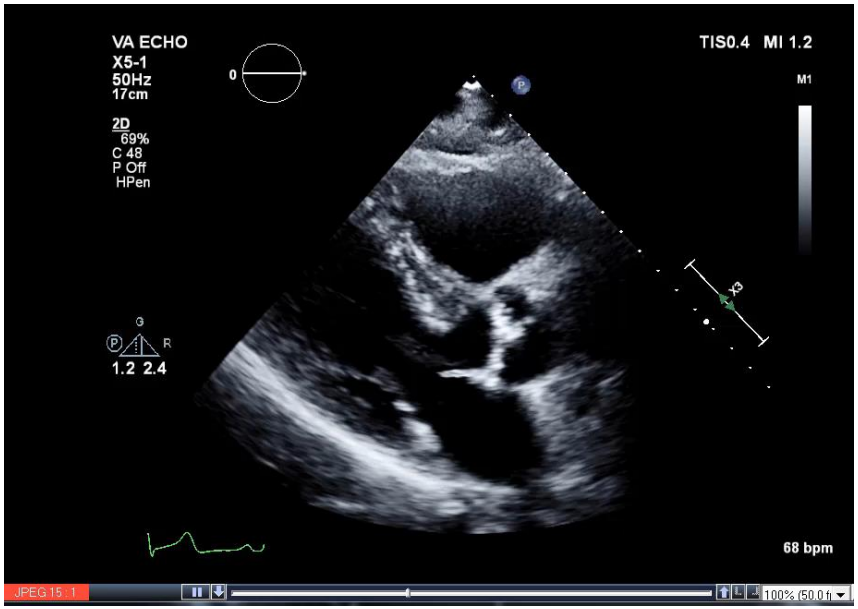
VA ECHO
X5-1
50Hz
17cm
TIS0.4 MI 1.2
2D
69%
C 48
P Off
HPen
1.2 2.4
68 bpm

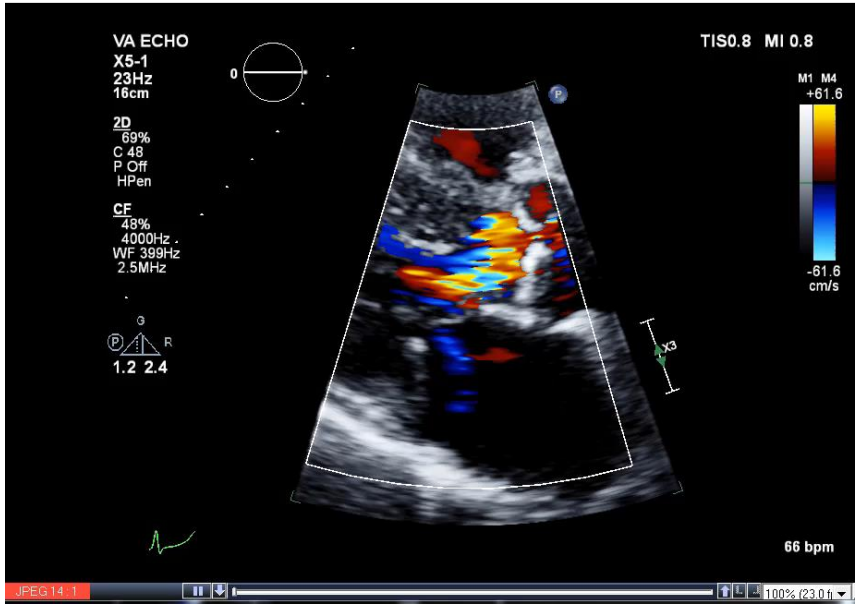
VA ECHO
X5-1
23Hz
16cm
TIS0.8 MI 0.8
2D
69%
C 48
P Off
HPen
CF
48%
4000Hz
WF 399Hz
2.5MHz
1.2 2.4
+61.6
-61.6
cm/s
66 bpm

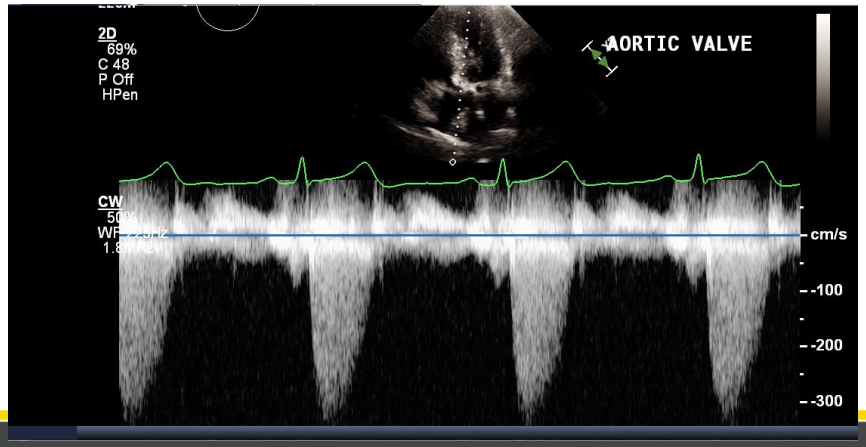
2D
69%
C 48
P Off
HPen
AORTIC VALVE
CW
cm/s
-100
-200
-300

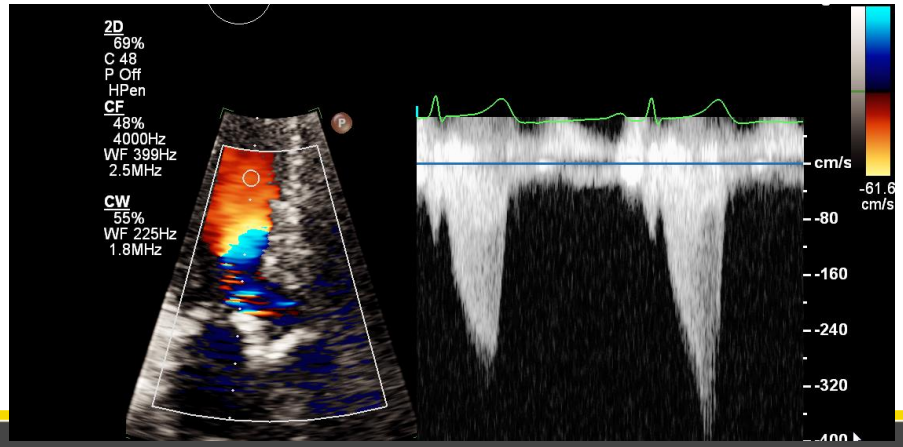
2D
69%
C 48
P Off
HPen
CF
48%
4000Hz
WF 399Hz
2.5MHz
CW
55%
WF 225Hz
1.8MHz
cm/s
-80
-160
-240
-320
-61.6
cm/s

Case

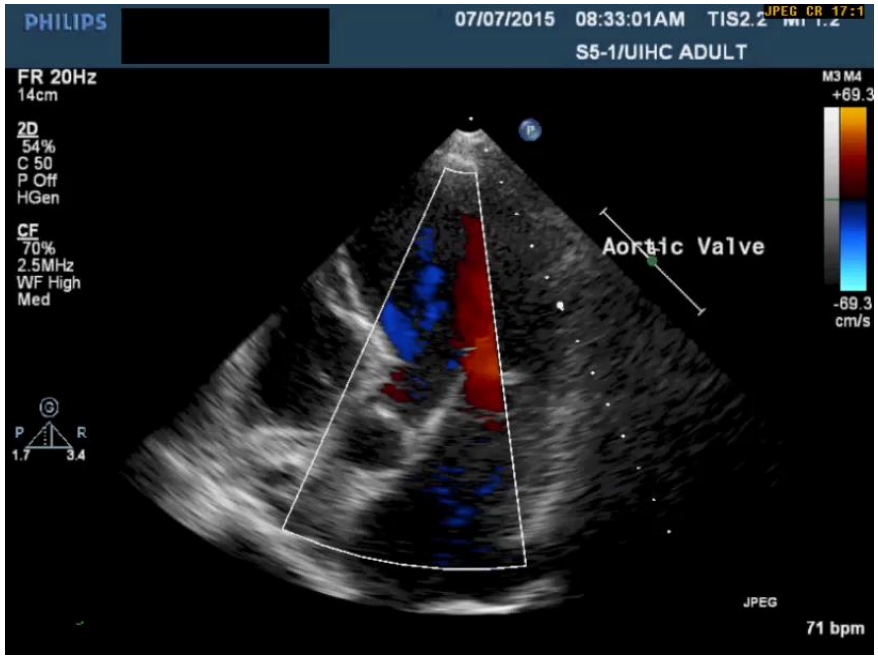

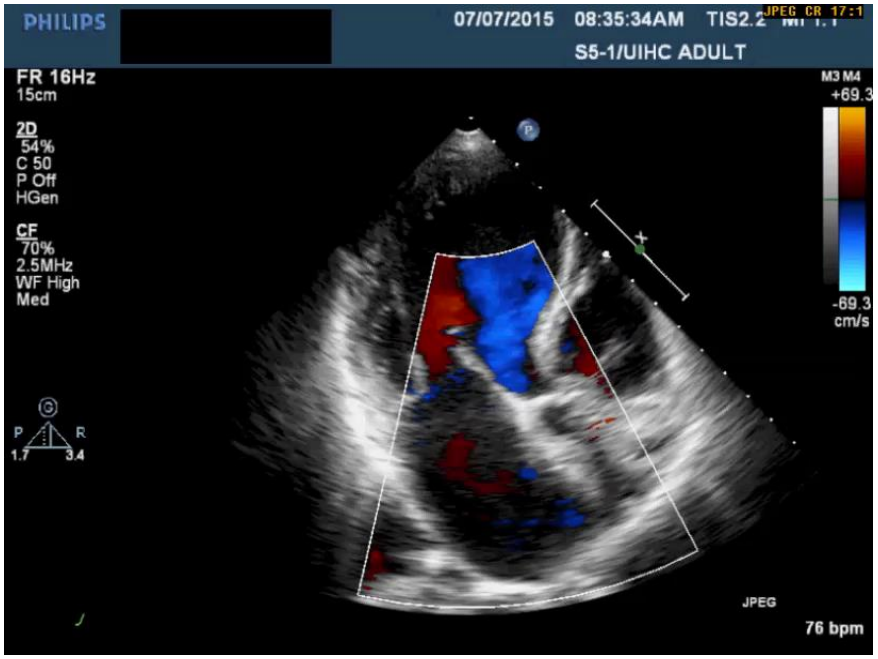

Findings?

Technical Concerns? Contamination: AS/MR, TR/MR

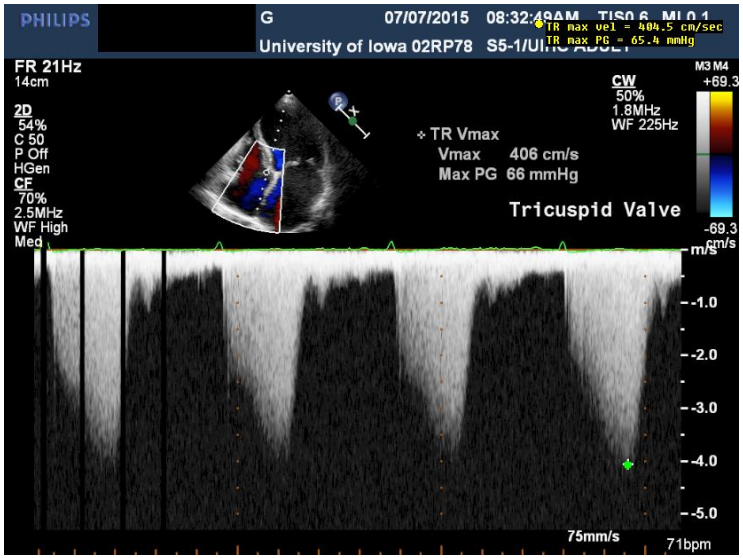
PHILIPS
G 07/07/2015 08:32:49AM TIS0.6 MI 0.1
University of Iowa 02RP78 S5-1/UIHC ADULT
TR max vel = 404.5 cm/sec
TR max PG = 65.4 mmHg
FR 21Hz
14cm
2D
54%
C 50
P Off
HGen
CF
70%
2.5MHz
WF High
Med
CW
50%
1.8MHz
WF 225Hz
M3 M4
+69.3
TR Vmax
Vmax 406 cm/s
Max PG 66 mmHg
Tricuspid Valve
-69.3
cm/s
m/s
-1.0
-2.0
-3.0
-4.0
-5.0
75mm/s
71bpm

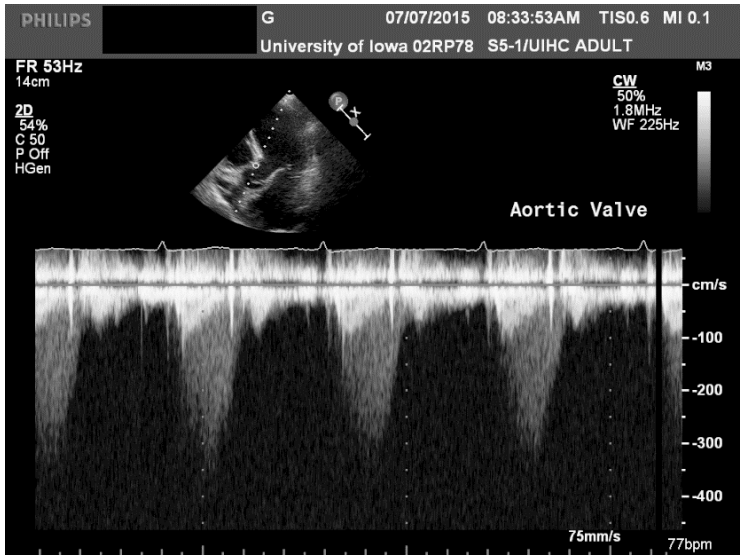
PHILIPS
G 07/07/2015 08:33:53AM TIS0.6 MI 0.1
University of Iowa 02RP78 S5-1/UIHC ADULT
FR 53Hz
14cm
2D
54%
C 50
P Off
HGen
CW
50%
1.8MHz
WF 225Hz
M3
Aortic Valve
cm/s
-100
-200
-300
-400
75mm/s
77bpm

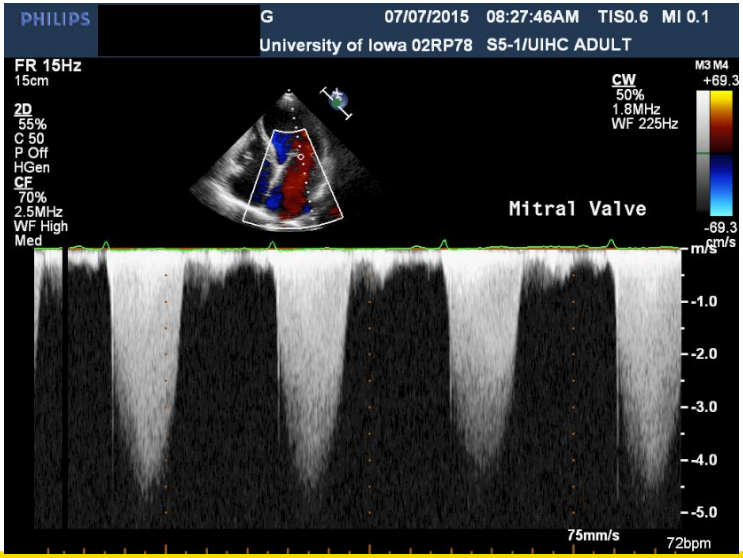
PHILIPS
G 07/07/2015 08:27:46AM TIS0.6 MI 0.1
University of Iowa 02RP78 S5-1/UIHC ADULT
FR 15Hz
15cm
2D
55%
C 50
P Off
HGen
CF
70%
2.5MHz
WF High
Med
CW
50%
1.8MHz
WF 225Hz
M3 M4
+69.3
Mitral Valve
-69.3
cm/s
m/s
-1.0
-2.0
-3.0
-4.0
-5.0
75mm/s
72bpm

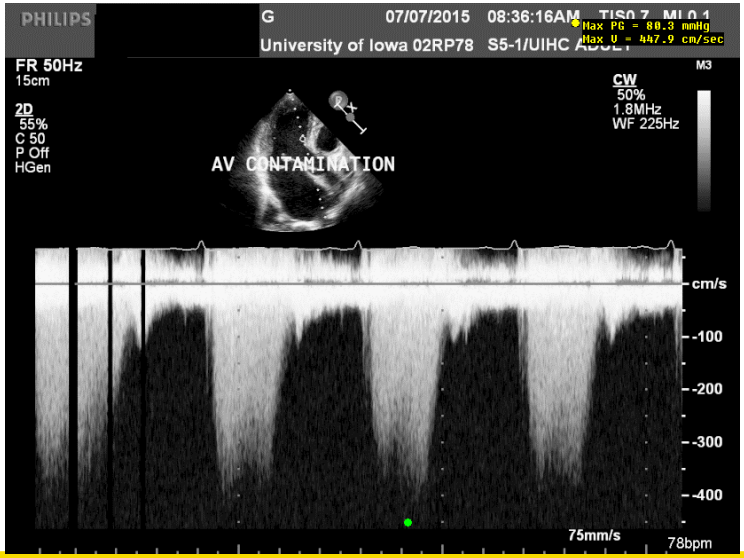
PHILIPS
G 07/07/2015 08:36:16AM TIS0.7 MI 0.1
University of Iowa 02RP78 S5-1/UIHC ADULT
Max PG = 80.3 mmHg
Max V = 447.9 cm/sec
FR 50Hz
15cm
2D
55%
C 50
P Off
HGen
CW
50%
1.8MHz
WF 225Hz
M3
AV CONTAMINATION
cm/s
-100
-200
-300
-400
75mm/s
78bpm

A Note about Amplitude

- The amplitude of the Doppler signal is represented by brightness
- Amplitude is determined by how many reflectors (RBC) are creating the DS
- Larger area = more RBC = higher amplitude
- Smaller area (stenosis) = less RBC = lower amplitude/weak

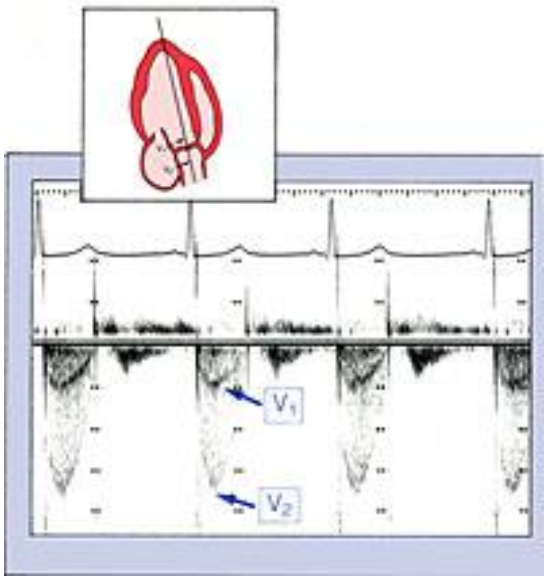

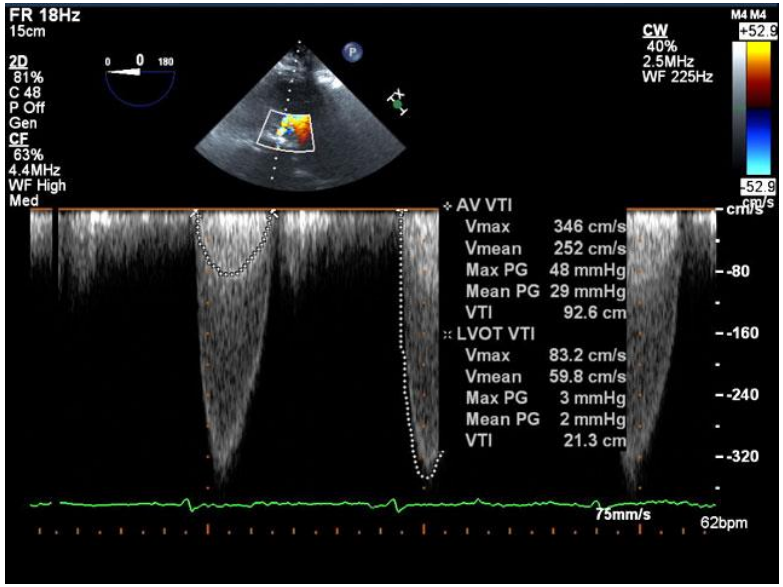

I'm not suggesting you calculate AS this way, just FYI you'll see it

Case

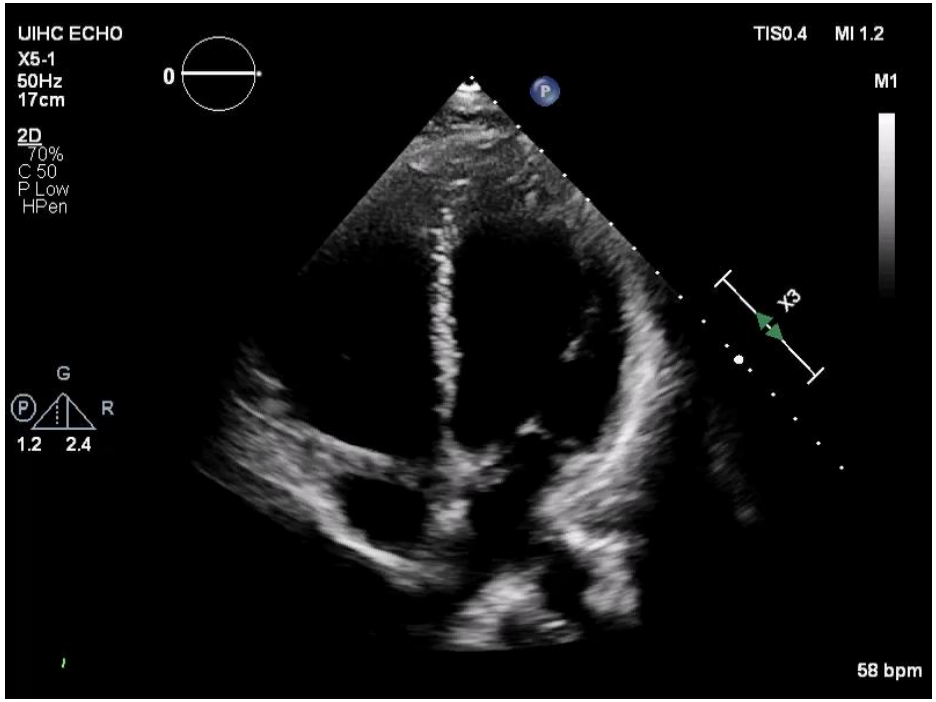

Apical thrombus?

Near field artifact/clutter can be challenging
2D adjustments include: zoom/depth, focus at the apex, different window, 2 planes
May use image enhancing agents

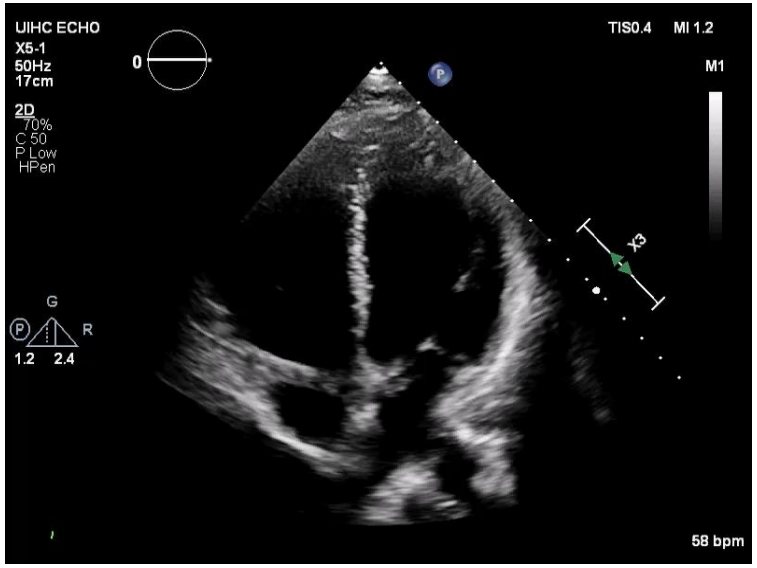

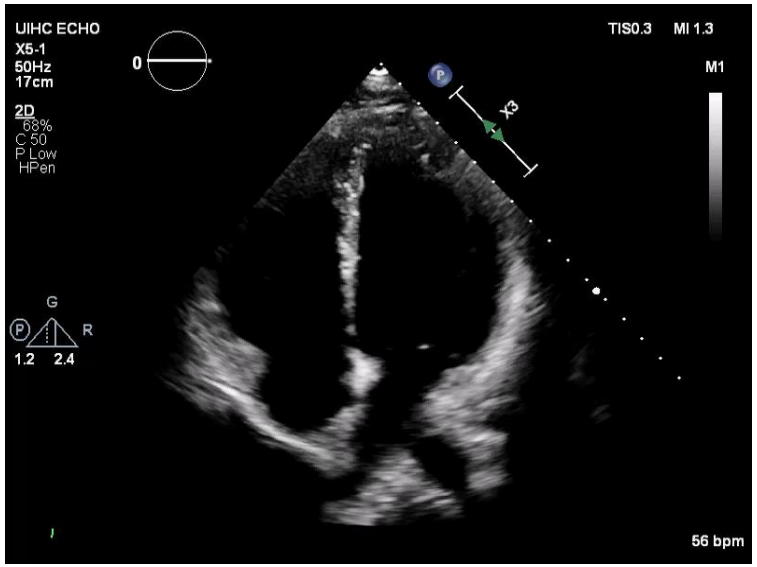

Move focus

Colorize

Depth and Higher Frequency

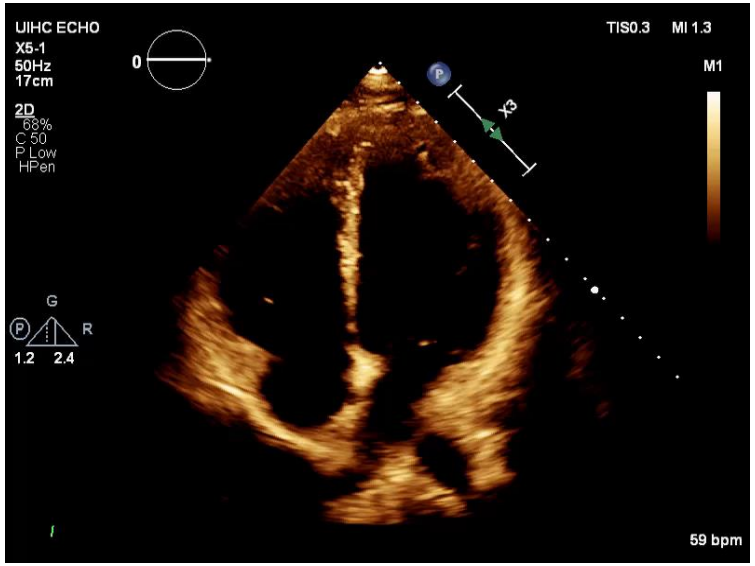

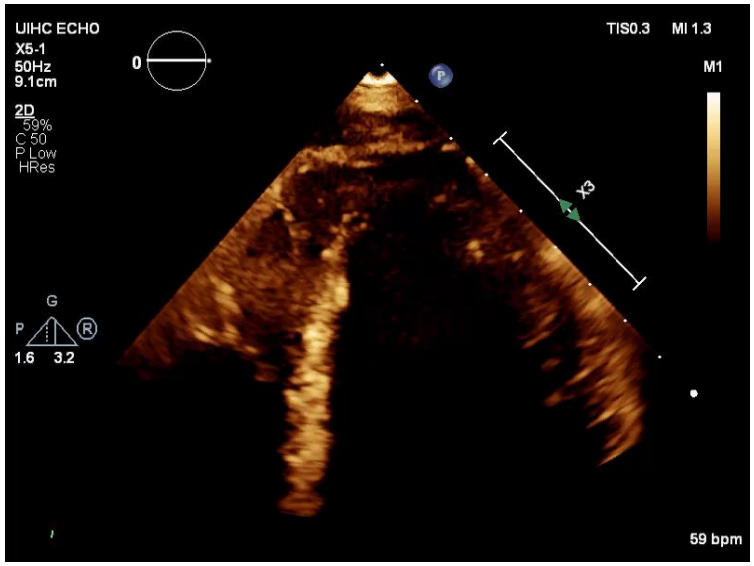

Near field Artifact

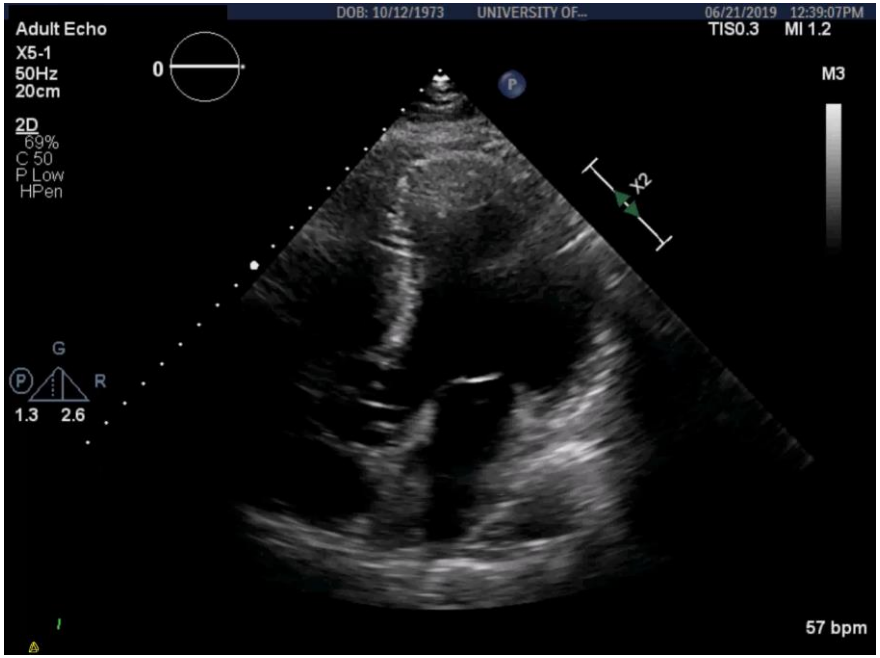

Definity contrast

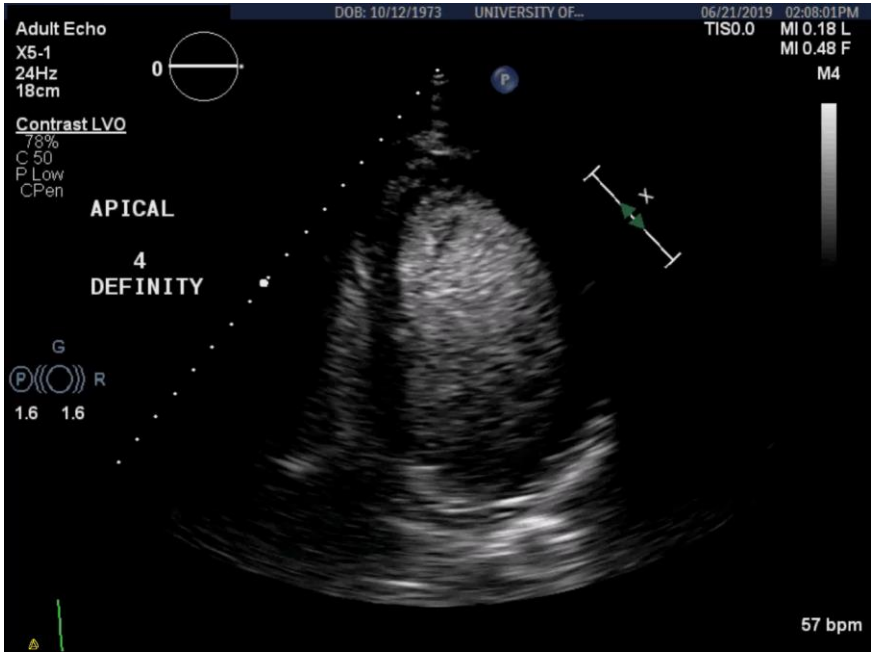

LV Thrombus - real

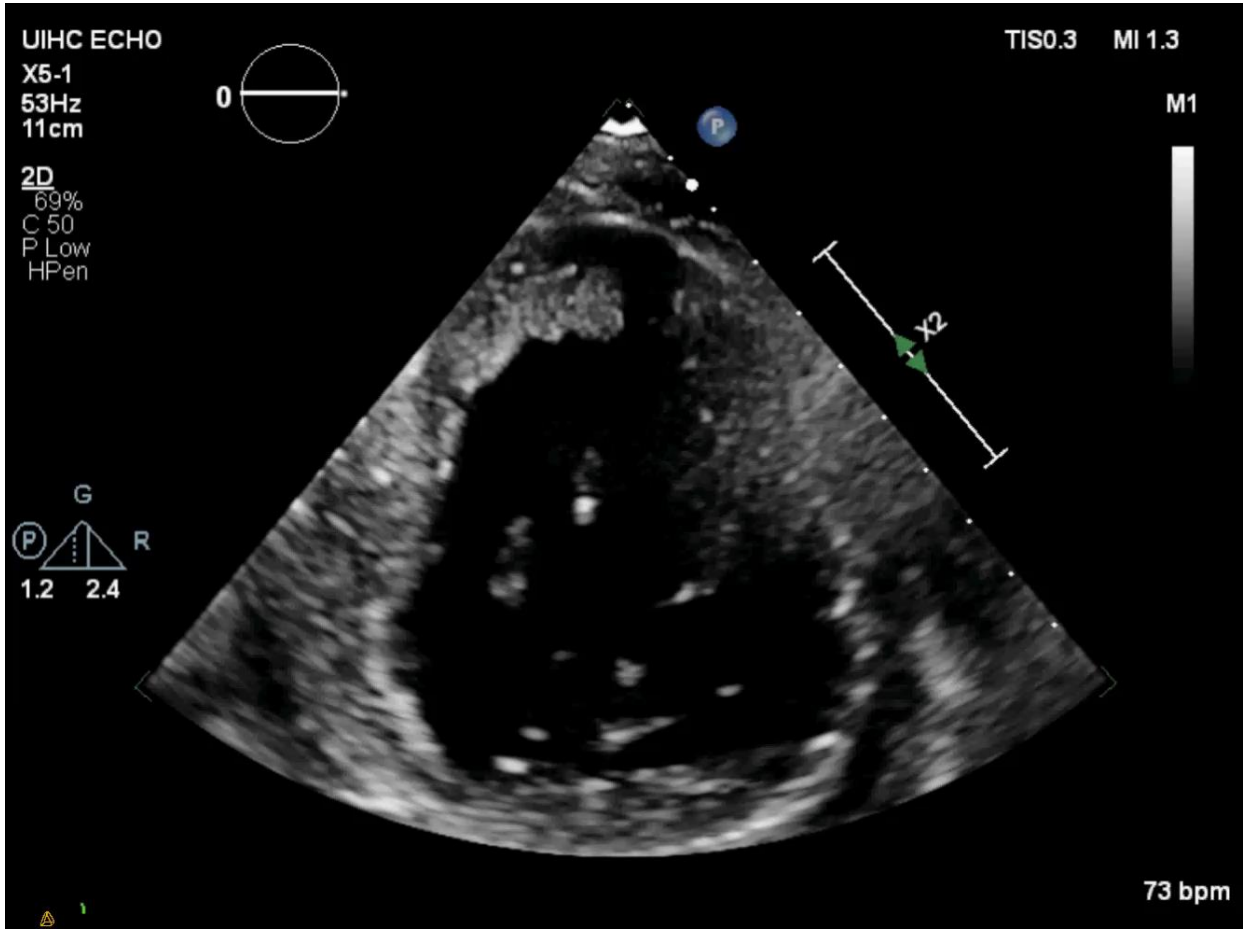

Case

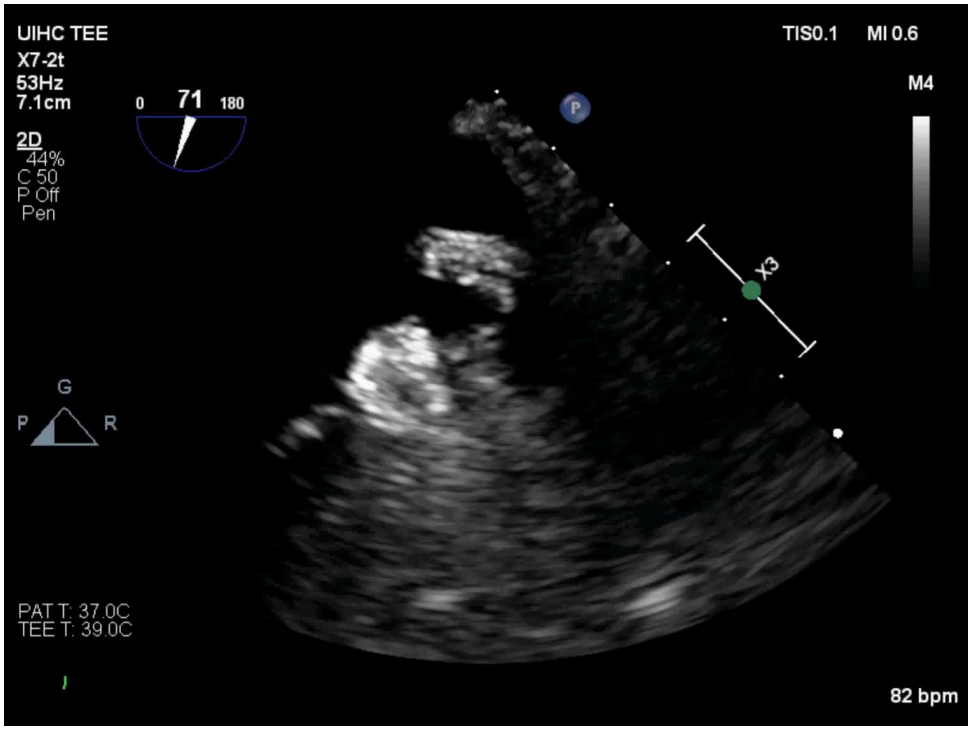

LAA Thrombus?

Beam width/slice thickness artifact
The elevation plane picks up echoes from adjacent area and displays them within the scan plane
2D techniques include: different window, 2 planes, scan through in real-time

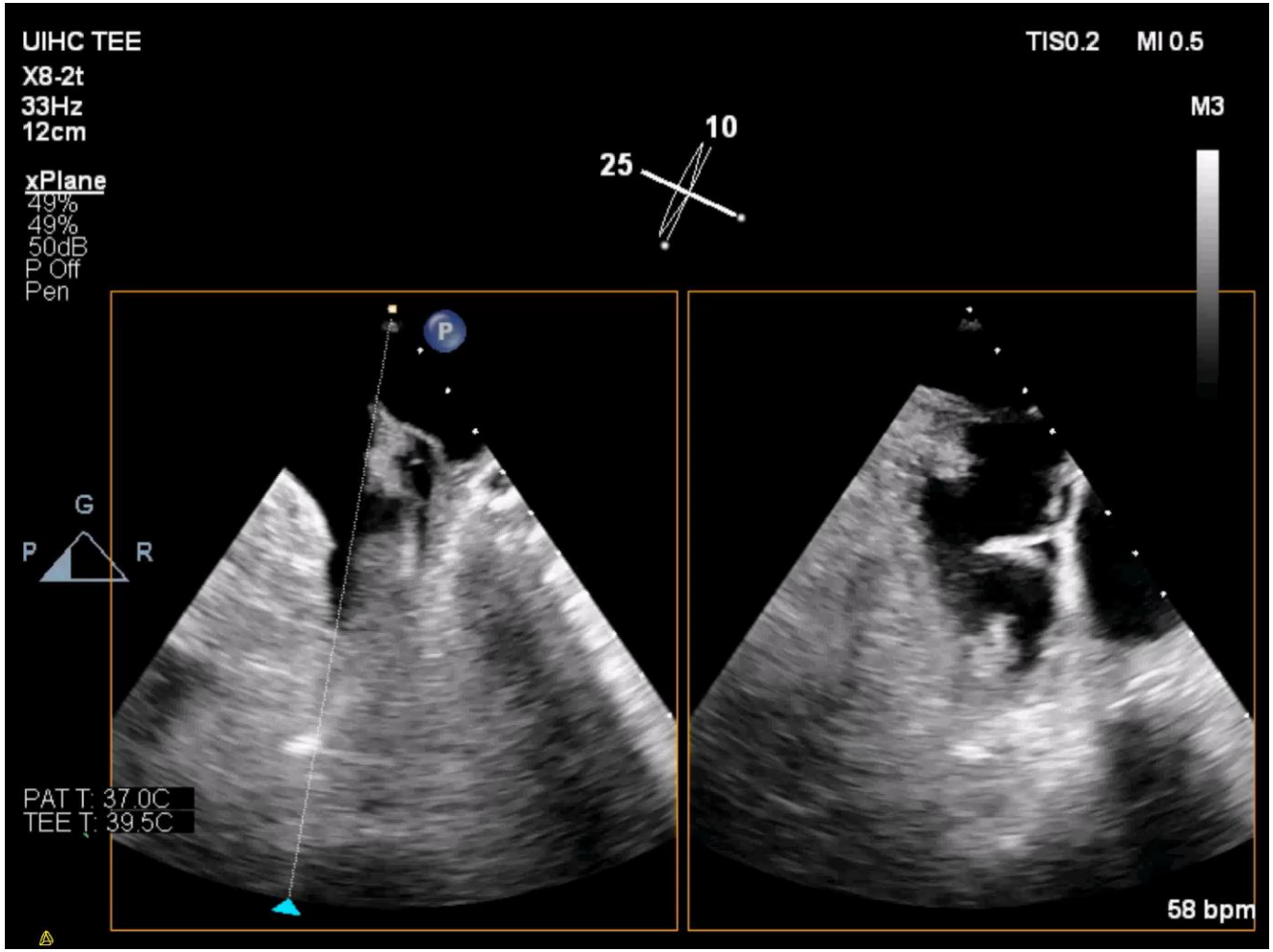
UIHC TEE
X8-2t
33Hz
12cm
xPlane
49%
49%
50dB
P Off
Pen
TIS0.2 MI 0.5
M3
10
25
G
P
R
PAT T: 37.0C
TEE T: 39.5C
58 bpm

Beam Width Artifact

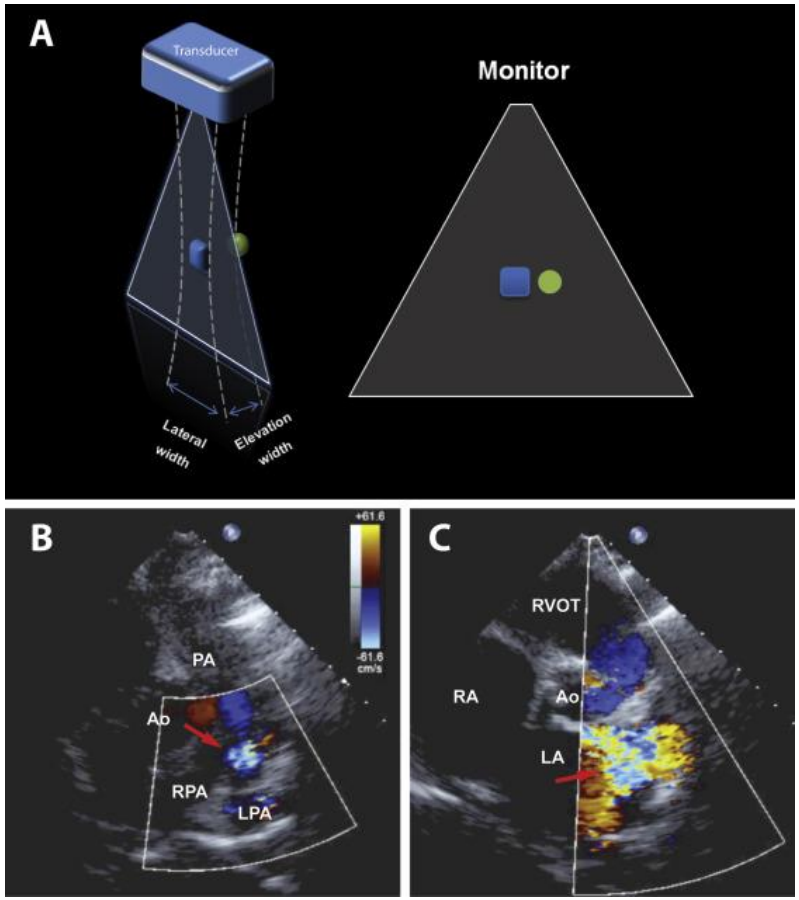

PSAX, apparent turbulence in left pulmonary artery is actually turbulent MR in LA picked up via elevation plane and beam width

The matrix transducers have a thinner beam (better elevation resolution) which decreased the beam width artifacts

Bertrand et all, JASE, May 2016

Beam Width artifact in aorta

Beam Width artifact in LA

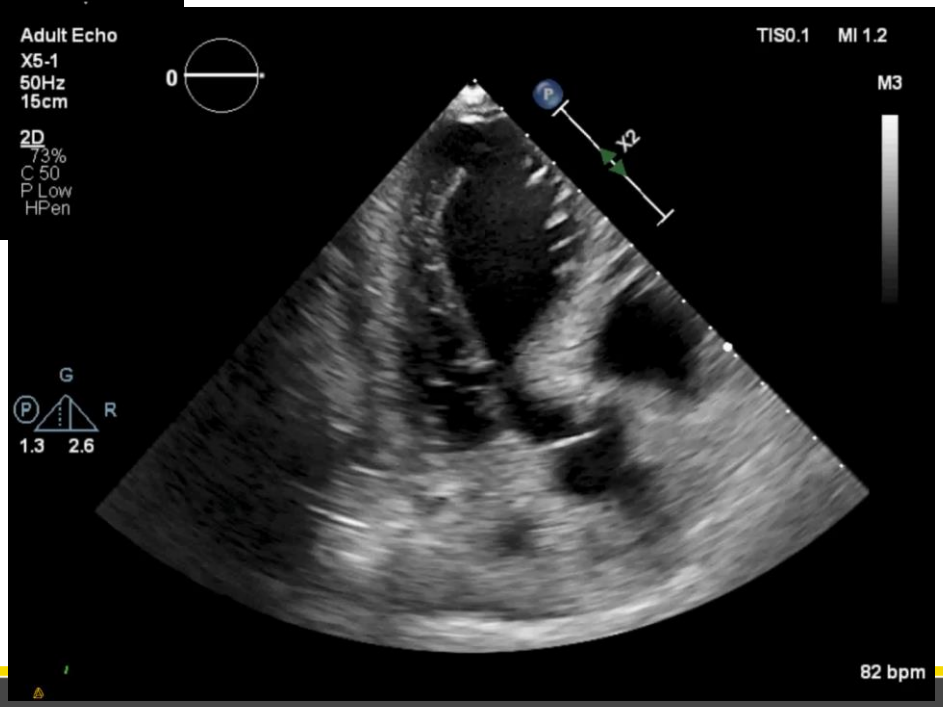

Case

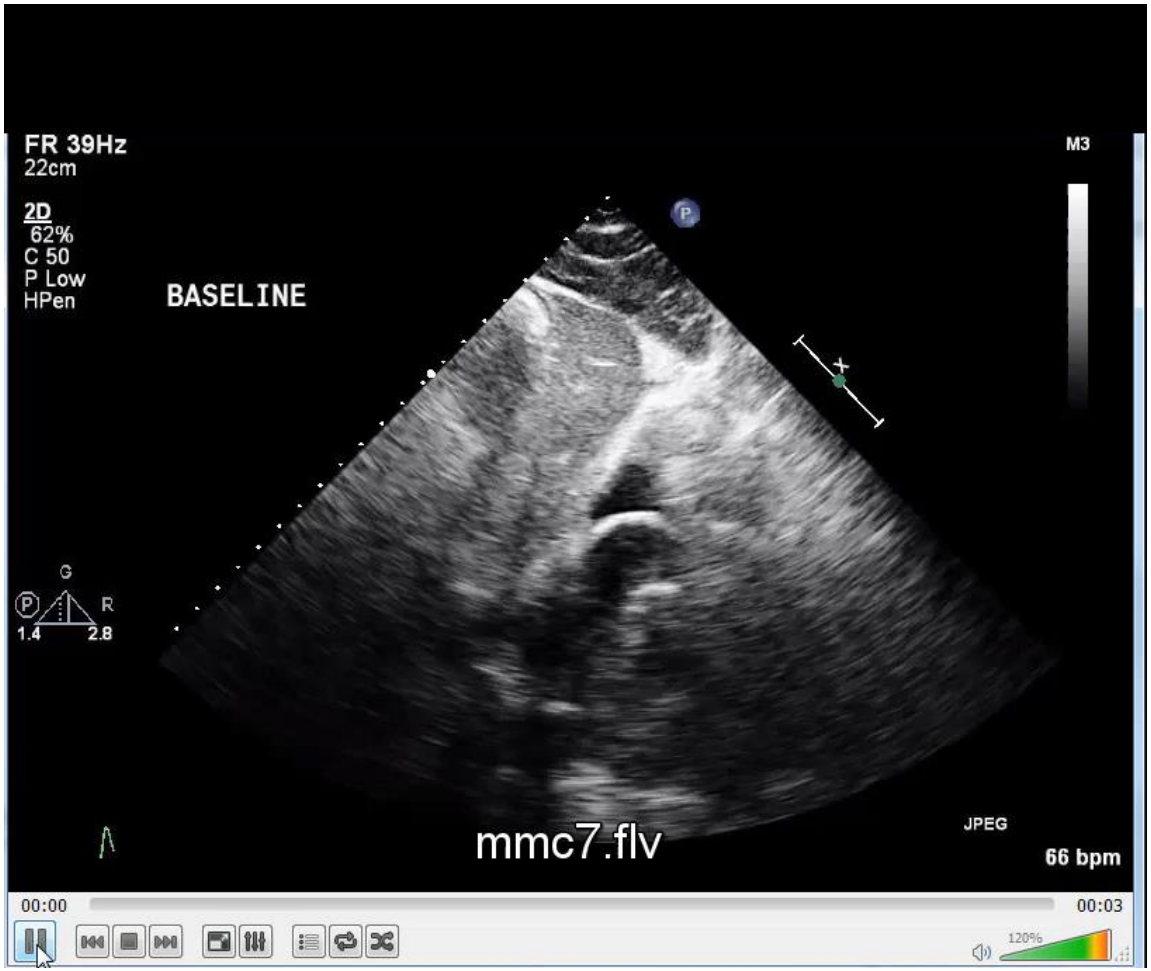

Subcostal SAX at Base

Refraction anteriorly (liver or abdominal wall) causes refraction of the beam

Duplicate echoes are placed in the wrong location horizontally

“Mirror image” of the aorta, but this time horizontally

Bertrand et all, JASE, May 2016

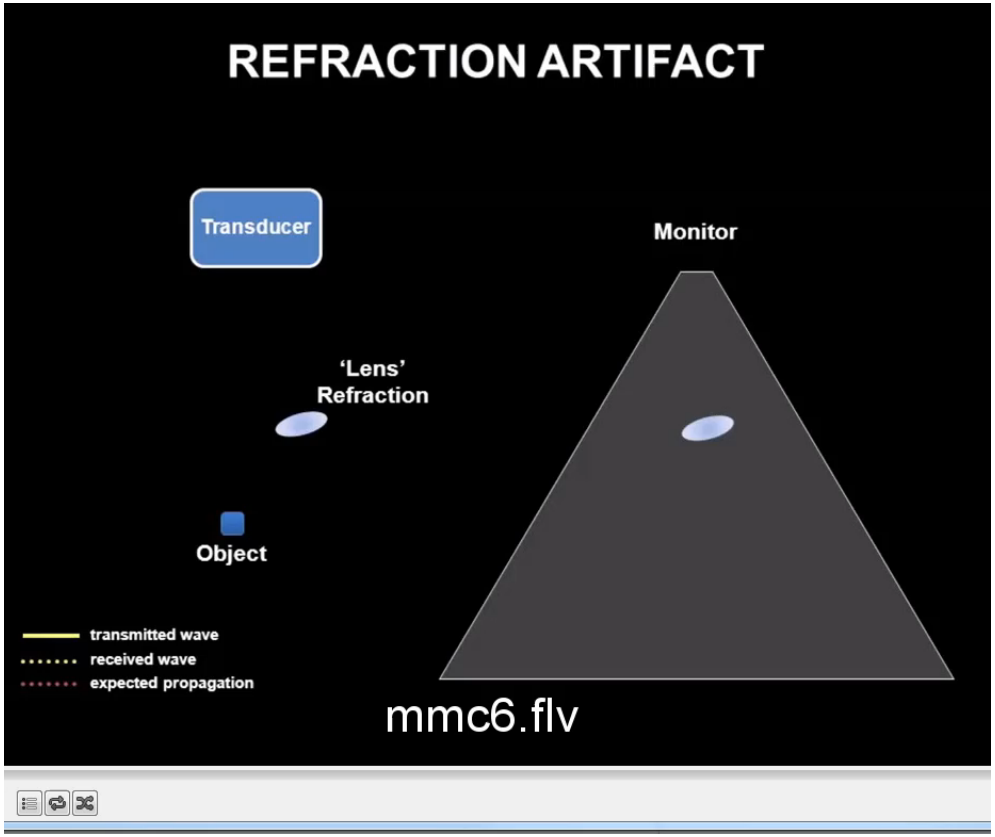

Bertrand et all, JASE, May 2016

The beam changes direction when it intersects a specular reflector at an angle (not perpendicular)

This redirection will cause shadows or duplicate echoes in the wrong location horizontally

Edge Shadows (Refraction Artifact)

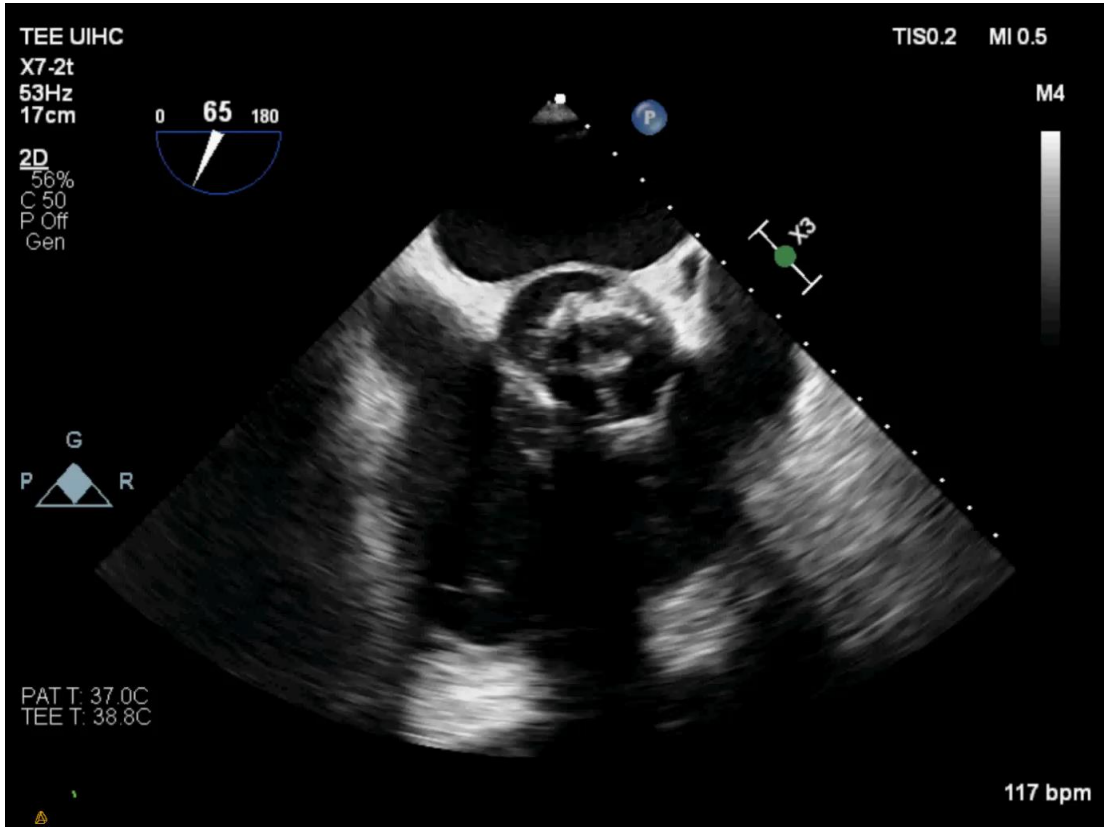

The redirection will cause shadows

Often seen in SAX at pap muscle

Summary

1. Identify how the 2D image is created, potential imaging pitfalls and artifacts, and changes required for image optimization
   - Shadow
   - Grating/side lobes
   - Reverberation (mirror image, comet tail)
   - Drop out
   - Near field clutter
   - Beam width
   - Refraction
2. Identify ways the color image is created, potential imaging pitfalls and artifacts, and changes required for image optimization
   - Shadow
   - Angle
   - Aliasing
3. Identify how the PW Doppler is used, advantages, disadvantages, pitfalls and artifacts
   - Angle - Velocity calculation
   - Aliasing
4. Identify when CW Doppler is used, advantages, disadvantages, pitfalls and artifacts
   - Angle – velocity calculation
   - Contamination

References

1. Bertrand PB, Levine RA, et al. Fact or Artifact in Two-Dimensional Echocardiography: Avoiding Misdiagnosis and Missed Diagnosis. JASE, May 2016; Vol 29, Issue 5, p 381-391. DOI: https://doi.org/10.1016/j.echo.2016.01.009
2. Hagen-Ansert SL. Textbook of Diagnostic Sonography, 8th Ed. Elsevier, 2018.
3. Kremkau FW. Sonography Principles and Instrumentation, 10th Ed. Elsevier, 2021.