Views, Catheters and Wires

Meera Kondapaneni, MD, FACC, FSCAI
Assistant Professor of Medicine, Case Western Reserve University School of Medicine
Director, Cardiac Catheterization Laboratory
Director, Cardiovascular Disease Fellowship Program
Vice Chairperson of Medicine for Gender Equity, Diversity and Inclusion
MetroHealth Medical Center

Keys to successful planning of PCI

- Optimal Coronary Angiographic views
- Guiding catheters
- Guide wires

Coronary Angiography

- Lesion location and severity
- Defining precise lesion length
- Degree of calcification
- Presence of thrombus
- Relationship to side branches
- Distribution of collateral supply

Optimal angiographic projections for PCI

- Guide catheter selection
- Visualizing the target vessel course
- Identifying optimal angle for treatment
- Estimating the true dimensions of index vessel

Coronary Anatomy

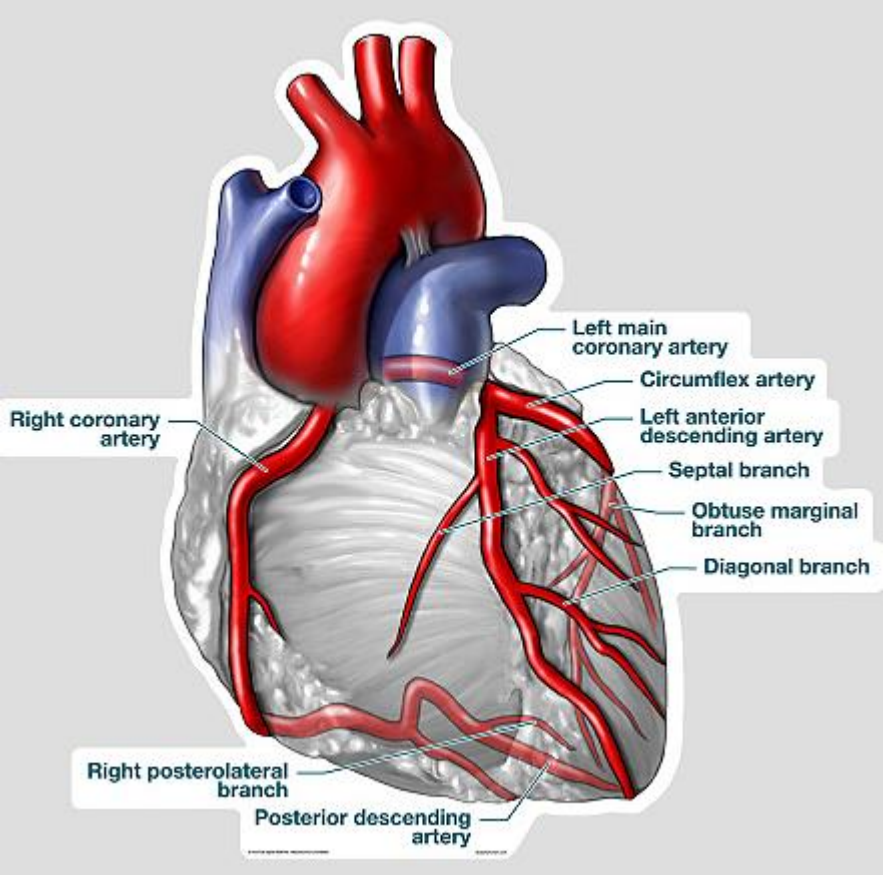

Coronary anatomy: Relative to Interventricular septum and Atrioventricular Valve Planes

Anterior descending (LAD) and posterior descending (PDA) arteries lie in the interventricular plane

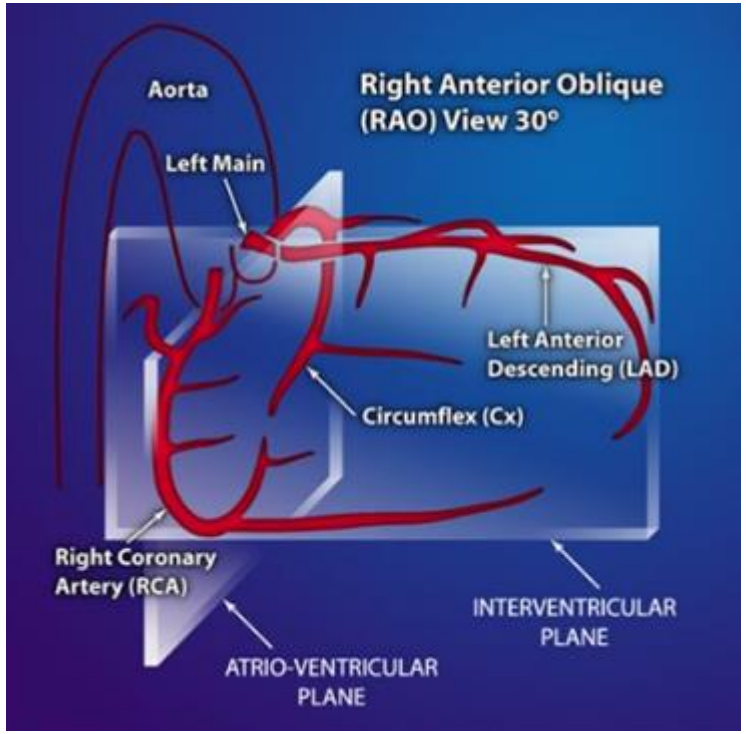

Right (RCA) and circumflex (Cx) coronary arteries lie in the atrioventricular plane

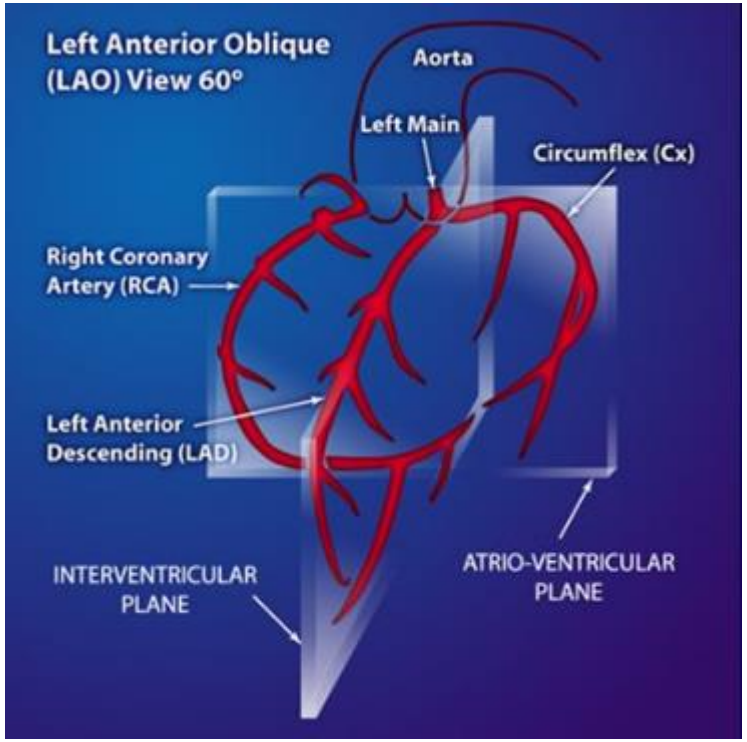

RAO 30° Projection: looking down the AV valves (Atrioventricular Groove plane)

The interventricular septum plane seen en-face

The two artia and the two ventricles are superimposed

The proximal circumflex and proximal RCA are well visualized as they follow the course of the atrioventricular groove

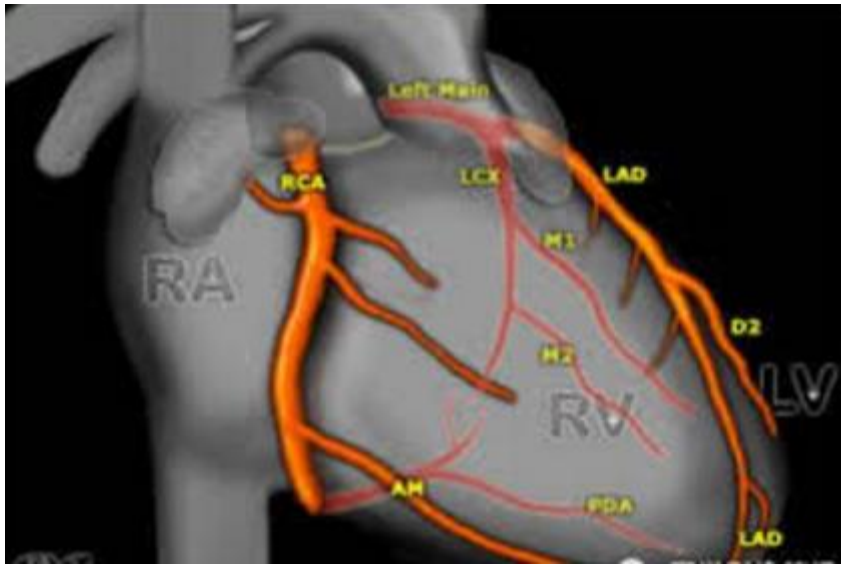

LAO 60° Projection
looking down the interventricular and interatrial septum plane

AV valves are seen en face

All left-sided cardiac chambers appear to the viewer's right

The LAD and PDA are seen coursing vertically in the middle of the cardiac silhouette following the path of the interventricular septum.

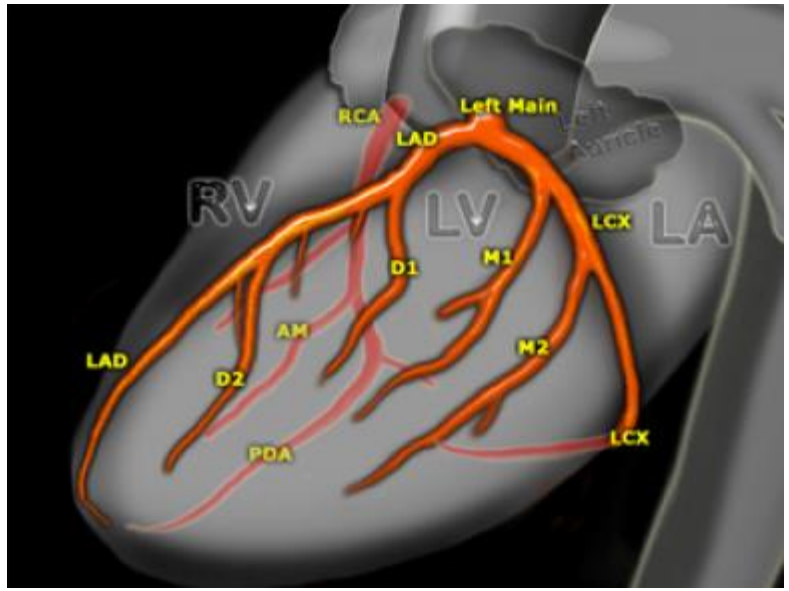

Standard Angiographic Views

Left Coronary artery Standard Views

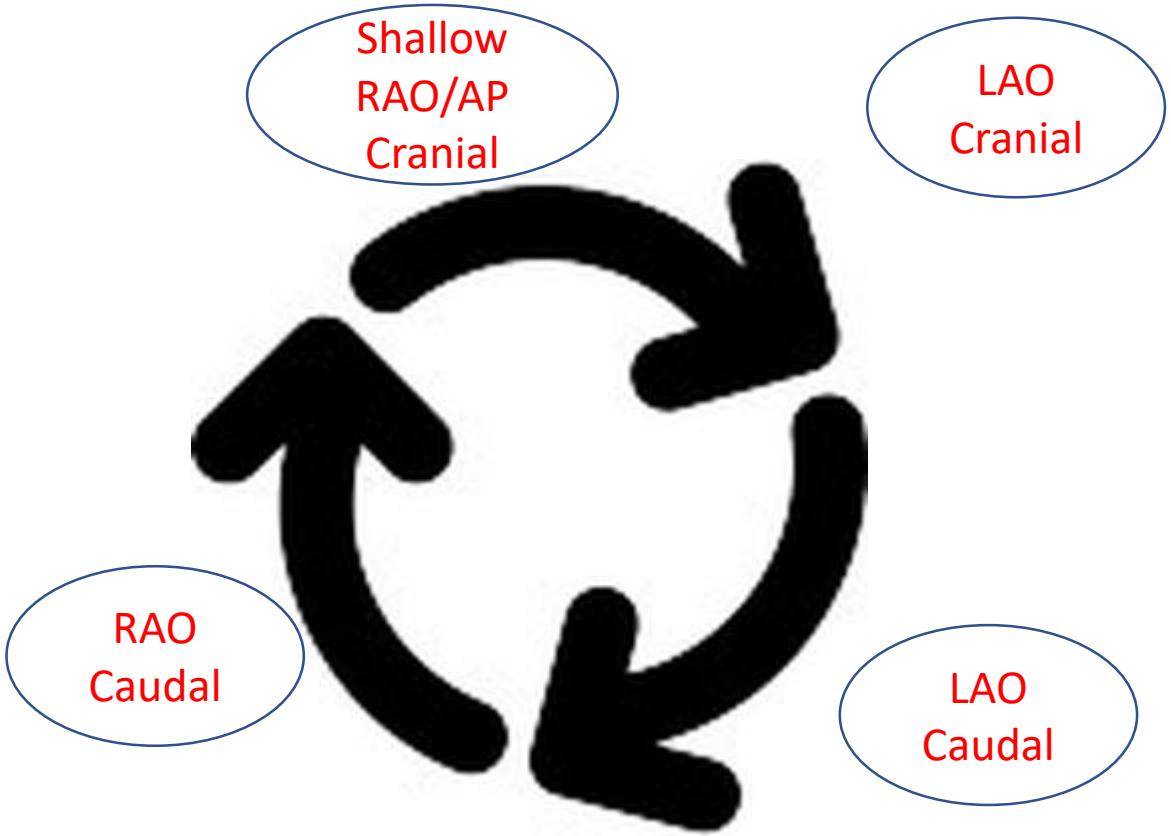

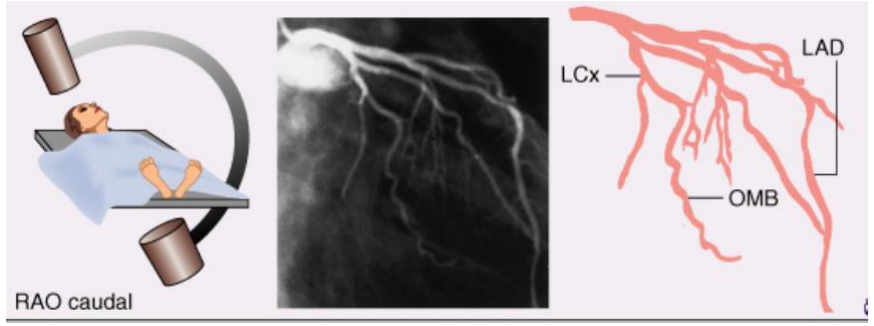

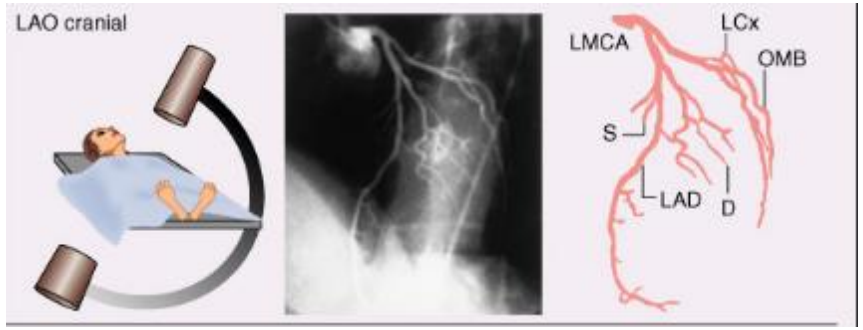

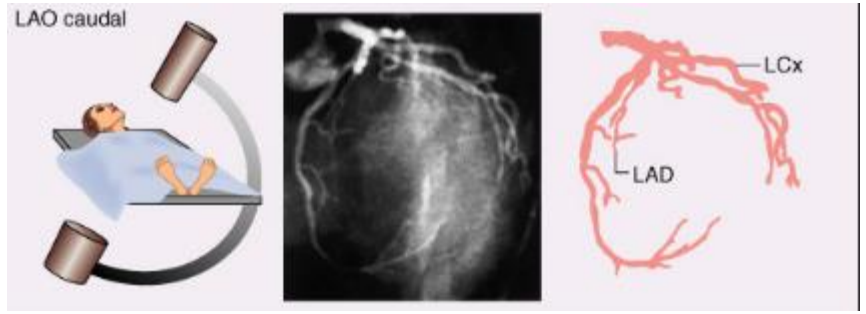

Images adapted from “Braunwald's Heart Disease: A Textbook of Cardiovascular Medicine”

Left Coronary artery: optional views

Optional LAD view

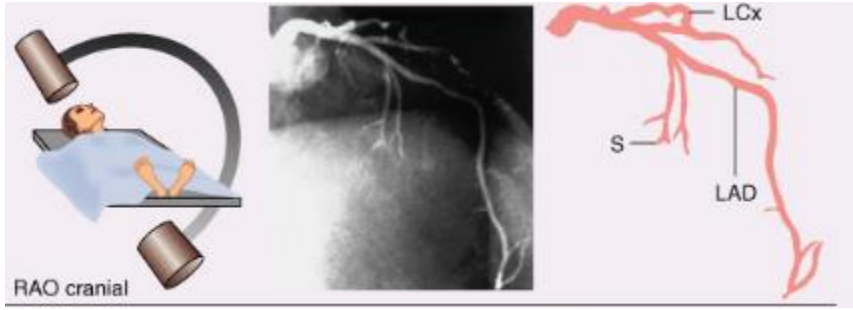

Optional Circumflex View

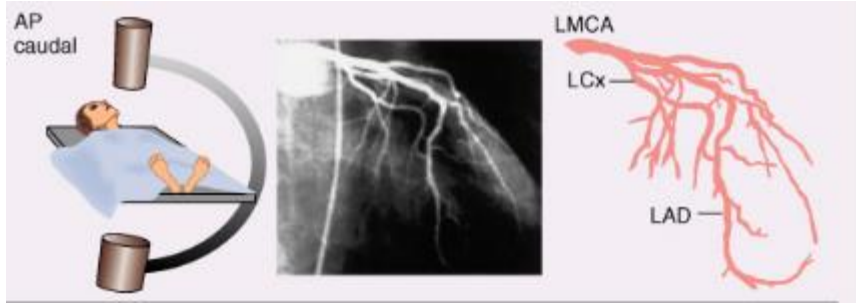

Right Coronary artery
Standard Views

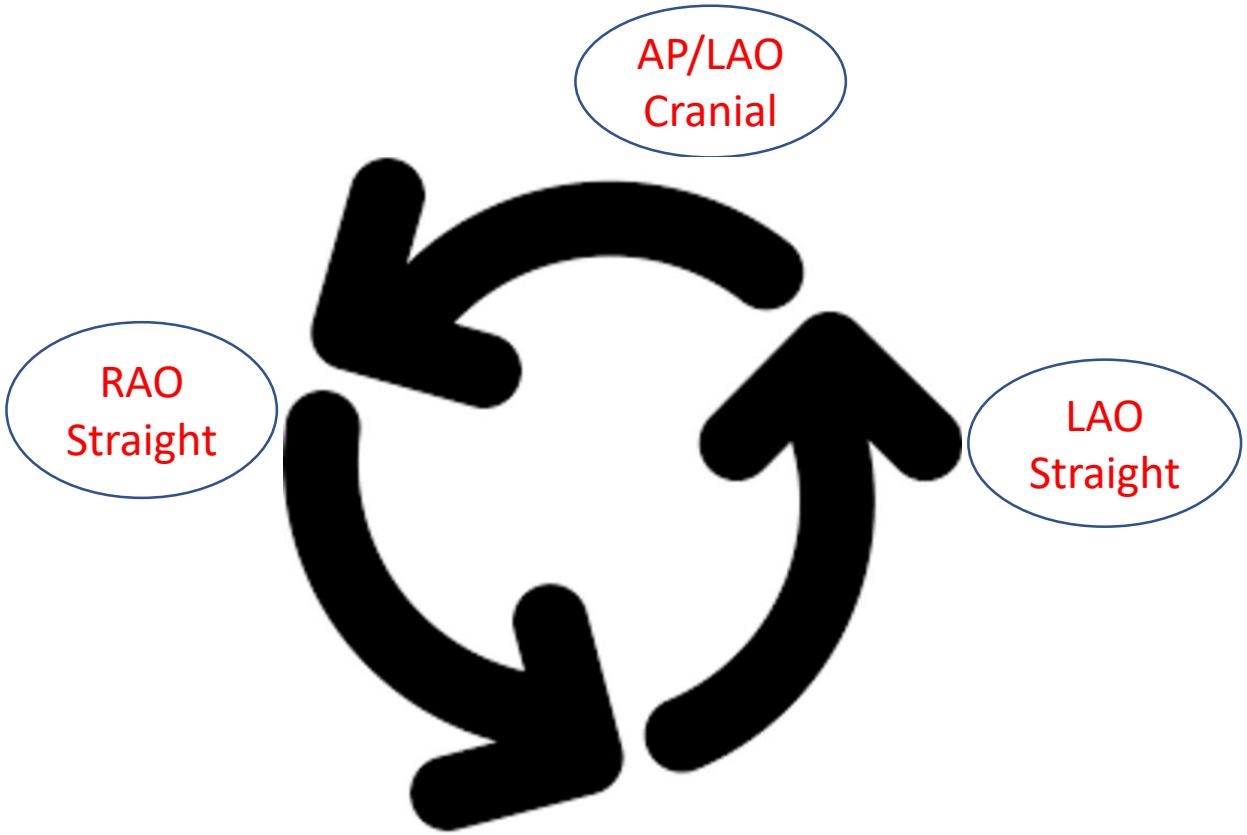

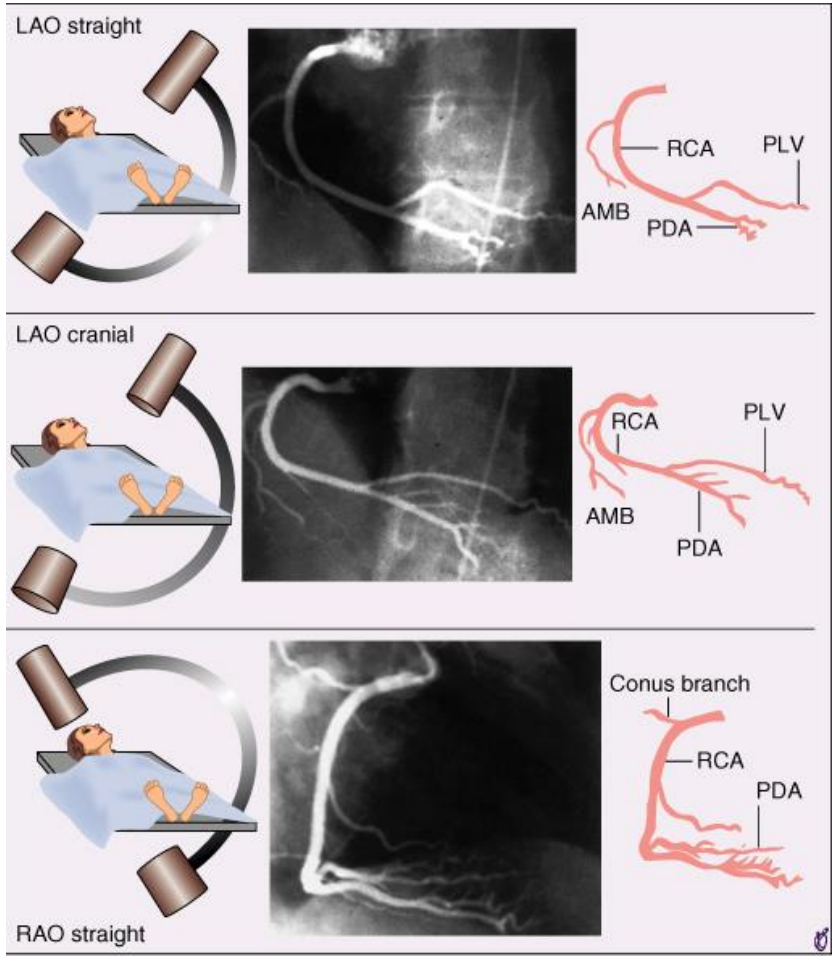

Table 2 Angiographic projections and optimal visualisation of left and right coronary artery segments

Coronary artery segment	LAO 40–50°, caudal 25–40° (spider)	AP/RAO 5–15°, caudal 30°	RAO 30–45°, caudal 30–40°	AP/RAO 5–10°, cranial 35–45°	LAO 30–45°, cranial 25–35°	Lateral ± caudocranial 10–30°	LAO 45–60°	RAO 30–45°
LM ostium	++	+	+	+++	+++	–	–	–
LM bifurcation	+++	+++	++	–	–	–	–	–
LAD proximal	++	++	+++	++	++	+	–	–
LAD mid	–	+	+	+++	++	++	–	–
LAD distal	+	+	+++	+	–	+++	–	++
LAD/diagonal	++	+	–	++	+++	–	–	–
LCX proximal	+	+++	+++	–	–	–	–	–
LCX distal	+	+	++	+++	++	+	++	–
OM bifurcation	++	+++	++	–	–	–	+	–
RCA proximal	–	–	–	+	+++	–	++	–
RCA mid	–	–	–	–	+	+++	++	+++
RCA distal/crux	–	–	–	+++	+++	–	++	–
PDA	–	–	–	+++	++	–	+	++
PLV	+	–	–	+++	++	+	+	–
LIMA anastomosis	+	–	–	–	–	+++	–	–

– View not recommended; + occasionally useful; ++ very useful; +++ ideal view.
AP, anteroposterior; LAD, left anterior descending; LAO, left anterior oblique; LCX, left circumflex; LIMA, left internal mammary; OM, obtuse marginal; PDA, posterior descending artery; PLV, posterior left ventricular; RAO, right anterior oblique; RCA, right coronary artery.

Carlo Di Mario, Nilesh Sutaria; Heart 2005;91:968–976

Coronary Saphenous Vein Graft Angiography

- At least two views (LAO and/or RAO)
- Lay out aortic anastomosis, body of the graft, and distal anastomosis
- Distal runoff and collaterals if present

Coronary Saphenous Vein Graft Angiography

Match the graft angiography view with the native vessel views

- RCA graft: LAO cranial/RAO and lateral
- Circumflex (and obtuse marginals) grafts: LAO and RAO caudal
- LAD graft (or internal mammary artery): lateral, RAO cranial, LAO cranial, and AP (the lateral view is especially useful to visualize the anastomosis to the LAD)



Left coronary angiography: Left lateral

60^0 to 90^0 LAO

Best for visualizing

- **Mid LAD**
- **Mid Circumflex**

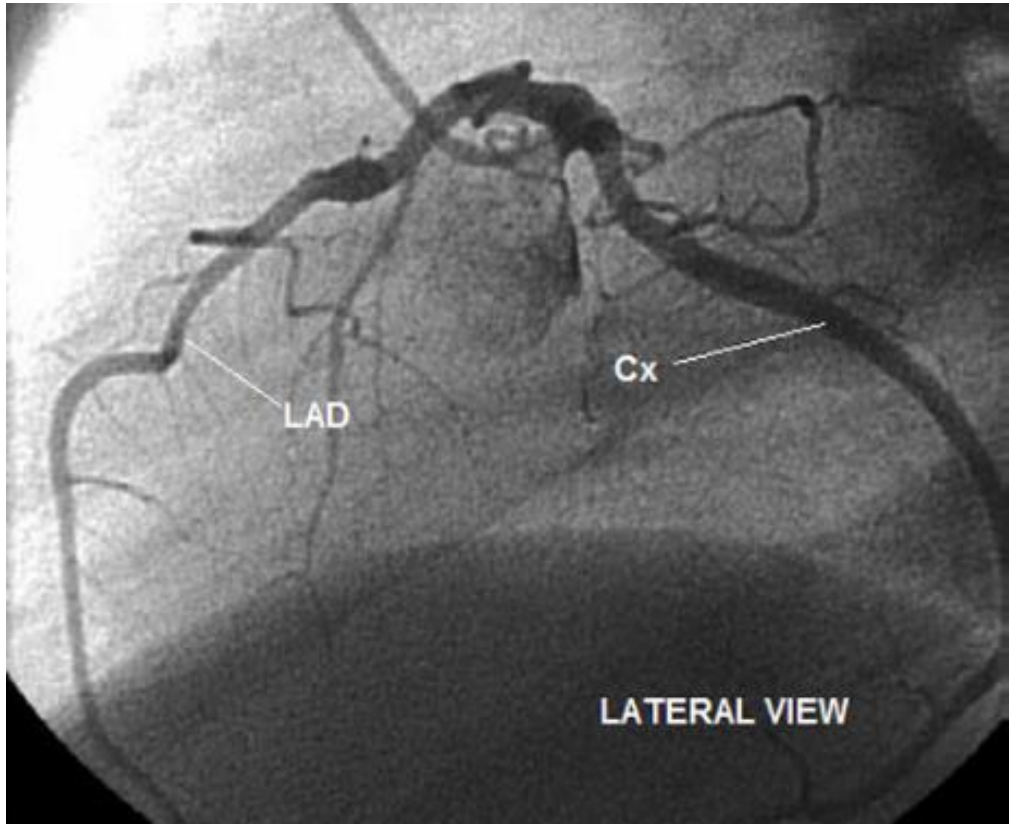

Take home message

Guiding Catheters

Guiding catheter

- Supportive conduit for advancement of guidewires and devices
- A vehicle for contrast injection
- Monitor blood pressure

Characteristics of a Guiding Catheter

- Atraumatic tip
- Proper preformed shape (co-axial with vessel)
- Torque control
- Kink resistance
- Radiopacity
- Support
- Device compatibility

Guiding catheter: Parts

- **Tip**
  - Atraumatic
  - Length influences stability in target vessel and maneuverability in Aorta
- **Primary Curve**
  - Angle of target vessel from Aorta
- **Secondary Curve**
  - Width of the Aorta
- **Tertiary Curve**
  - Normal curvature of Aorta
- **Length**
  - 100-110 cm for native vessels
  - 90 cm for LIMA graft or long SVG intervention

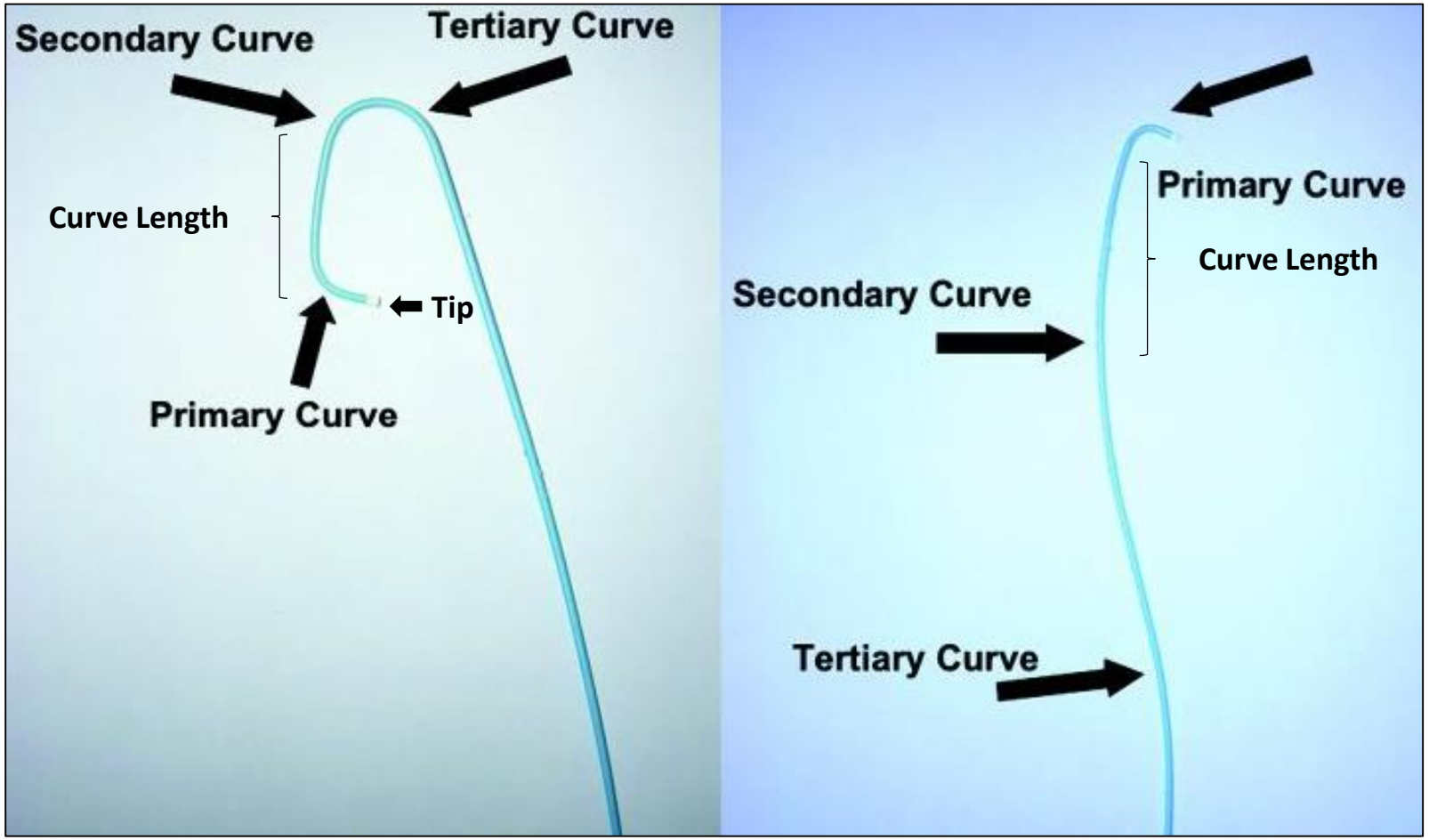

Factors Influencing Guide Selection

Patient factors

- Body habitus
- Age

Anatomy

- Ascending aorta and aortic root
- Coronary artery anatomic variants

Approach

- Femoral Vs Radial
- Co-axial Vs non-coaxial Vs deep intubation
- Ipsilateral Vs Contralateral back up support

Target vessel

- Native coronary artery Vs bypass graft
- Degree of tortuosity
- Calcification in the coronary artery

Target lesion

- Ostial Vs proximal Vs distal
- Bifurcation disease

Guide Selection based on Aortic Configuration

Narrow

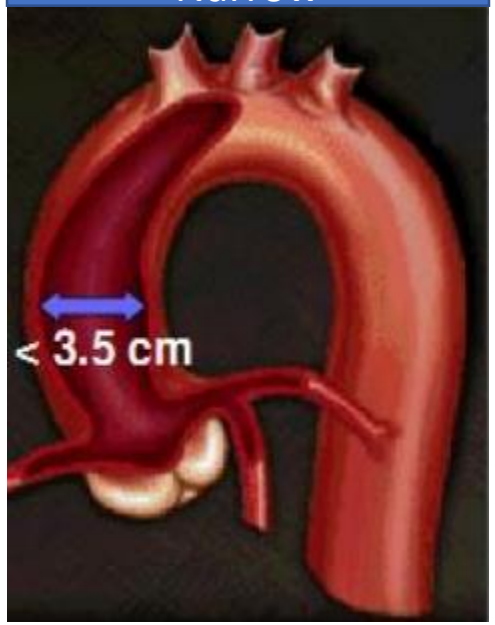

Left Coronary
EBU/XB 3-3.5
JL 3-3.5

Right Coronary
JR3
LIMA

Normal

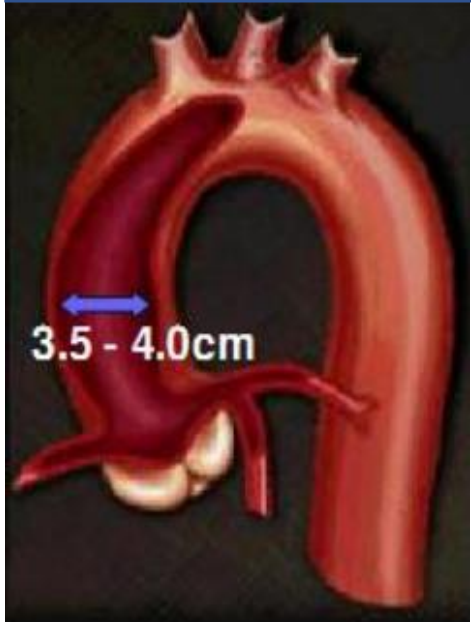

Left Coronary
EBU/XB 3.5-4
JL4, AL 1.5-2

Right Coronary
JR 3.5-4
AL 0.75-1 & AR 1
Hockey Stick

Dilated

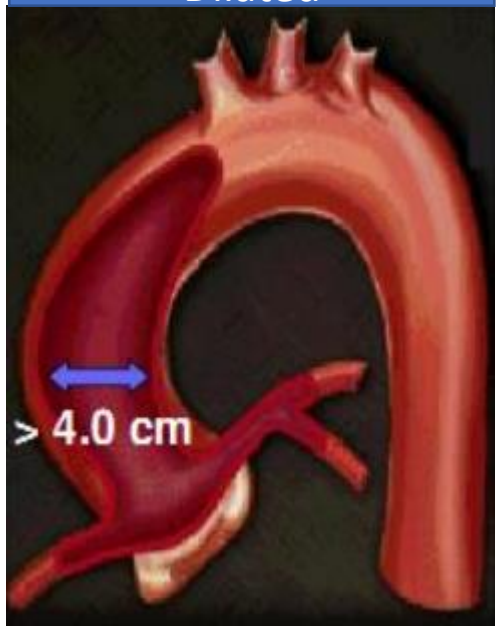

Left Coronary
EBU/XB 4
JL4.5 or >

Right Coronary
JR 4-4.5
AL 1.5-2 & AR 2

Guide Selection Based on Coronary Anatomy

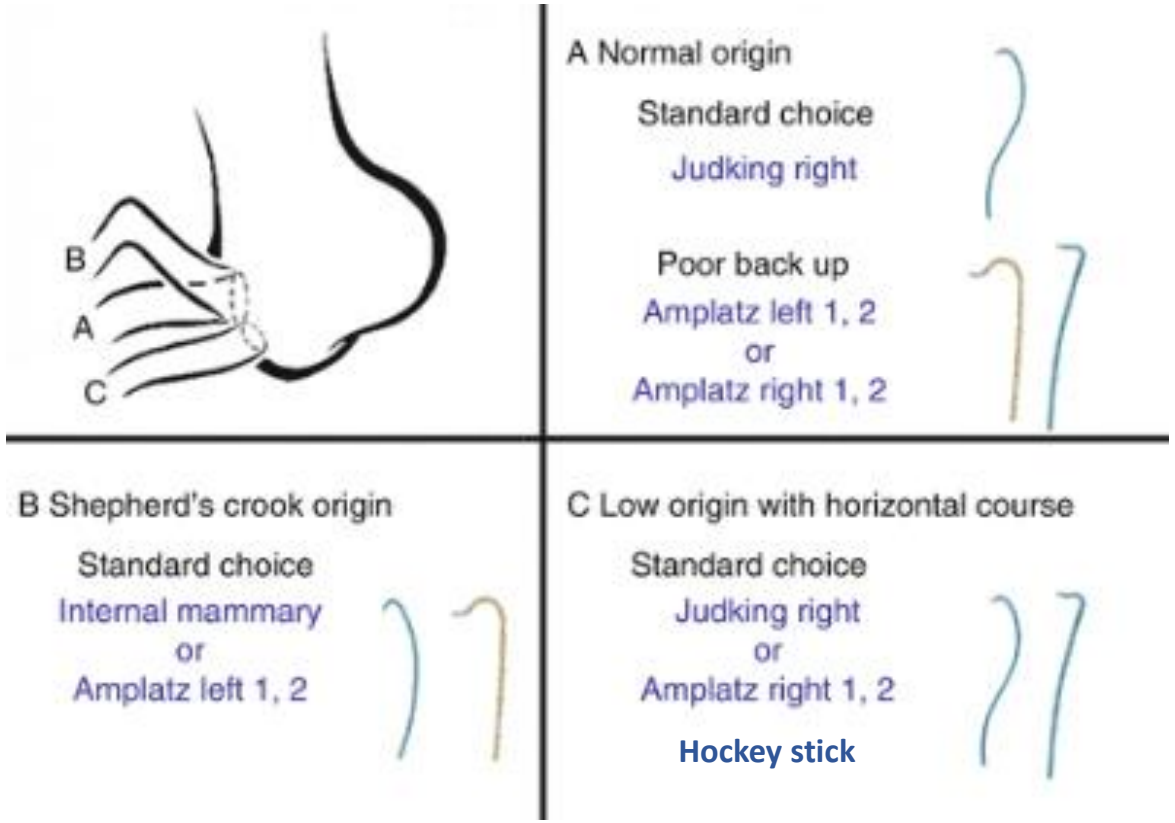

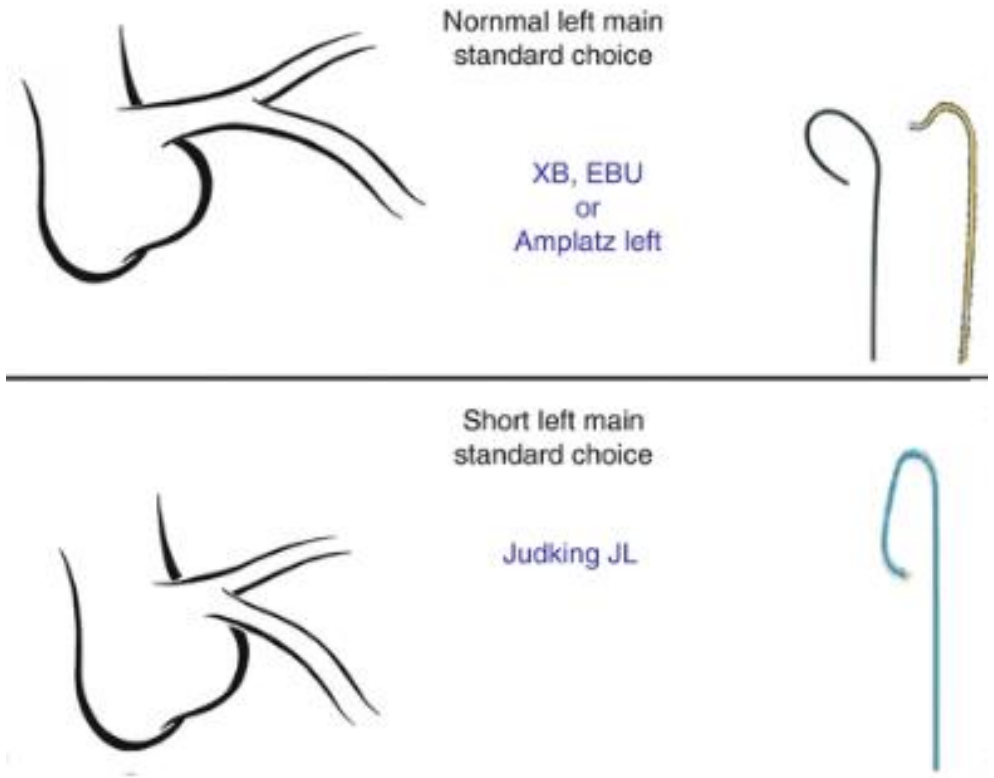

Guide Selection for Right Coronary Artery

Anterior Take-off

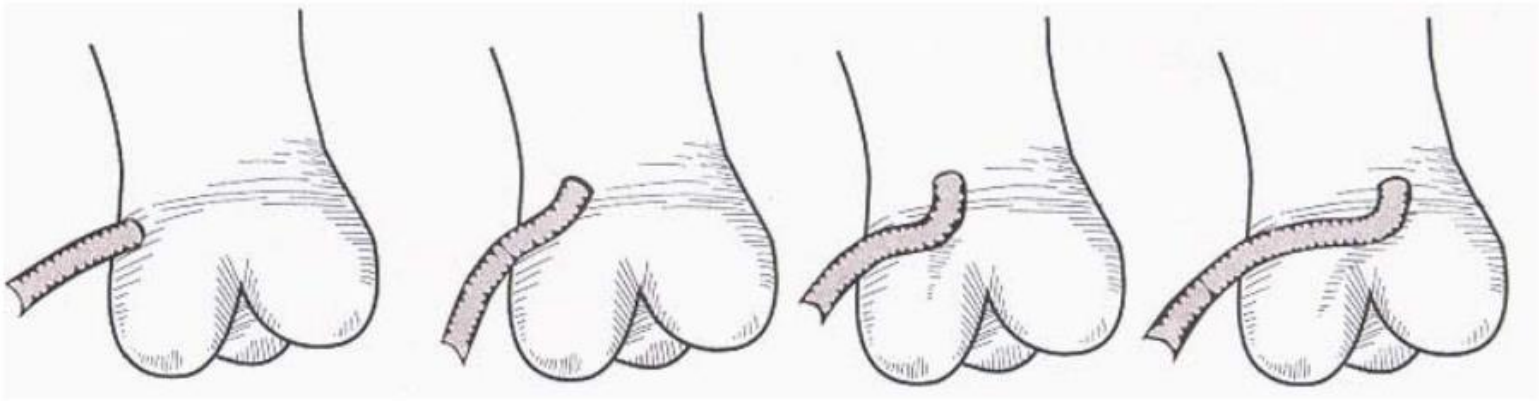

Right Judkins | Right Judkins or Hockey Stick | Hockey Stick or Left Amplatz | Left Amplatz or Left Judkins

Back up Support

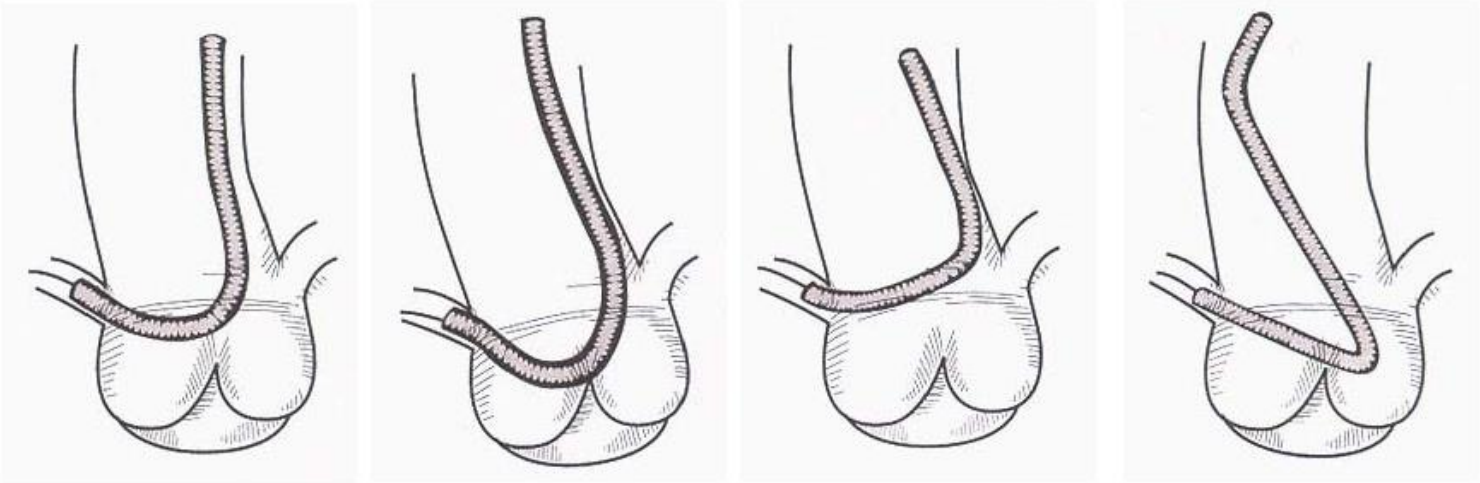

Hockey Stick | Amplatz | Left Venous Bypass Graft | Arani or XBRCA

Guide Selection for Left Coronary Artery

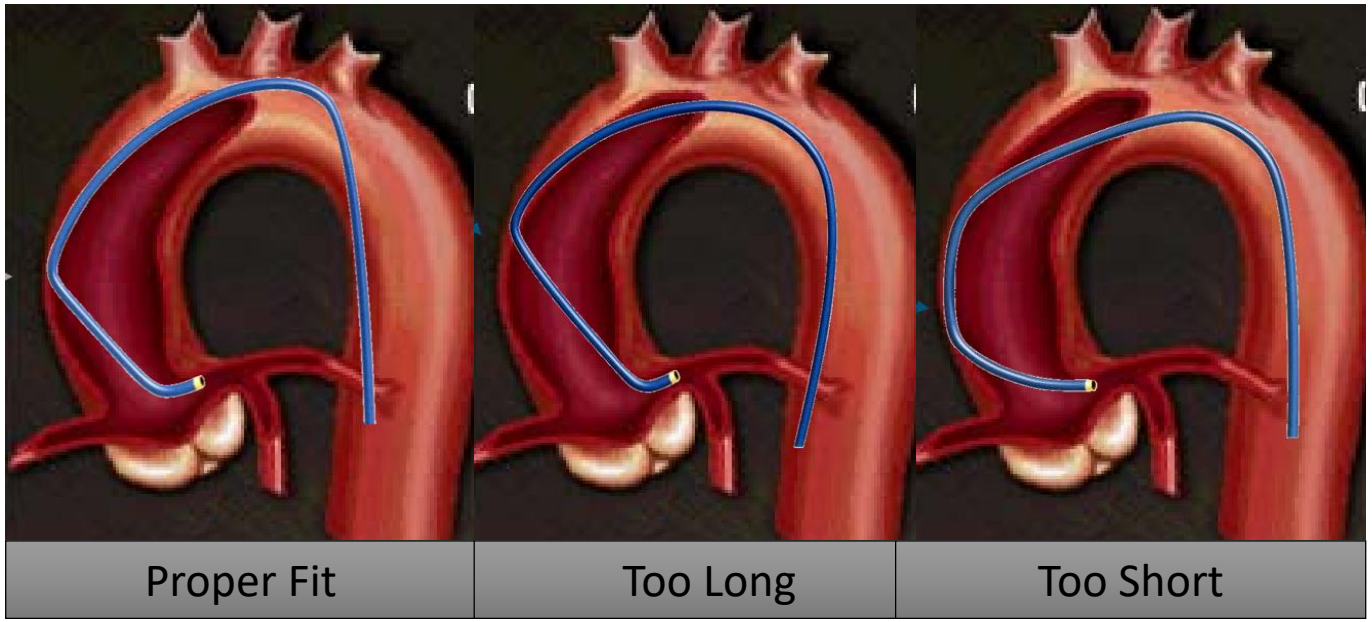

JL Fit in Normal Aorta

Extra Back up Catheter (XB/EBU) Fit in Normal Aorta

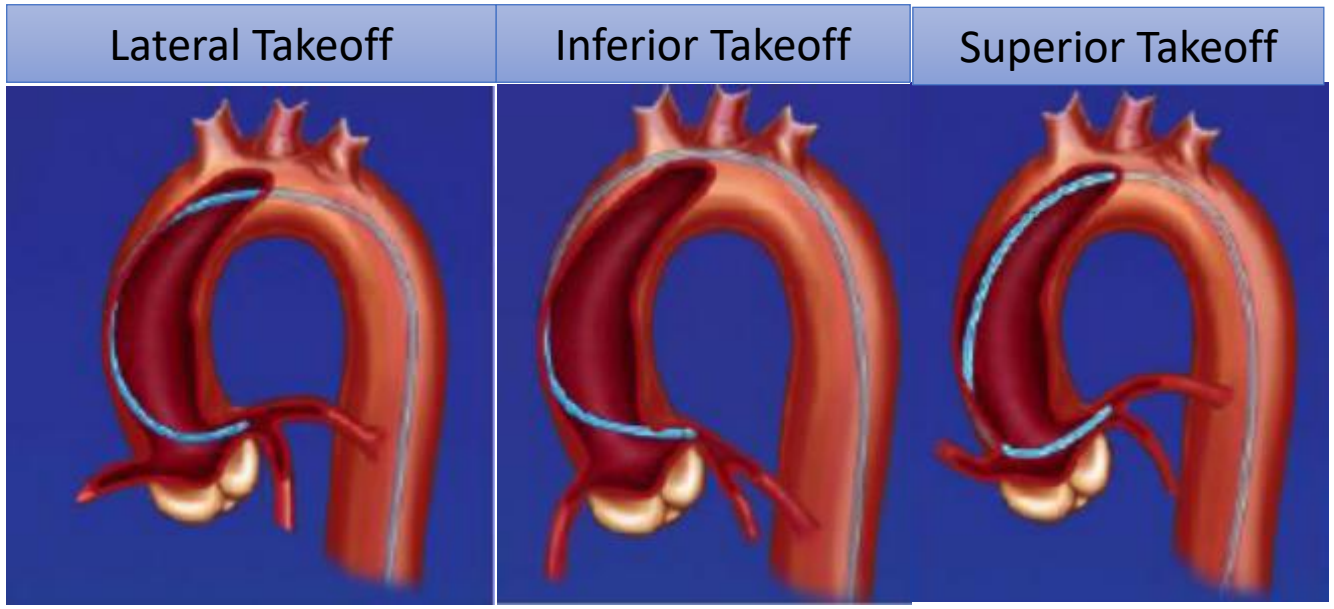

Guide Selection for Grafts

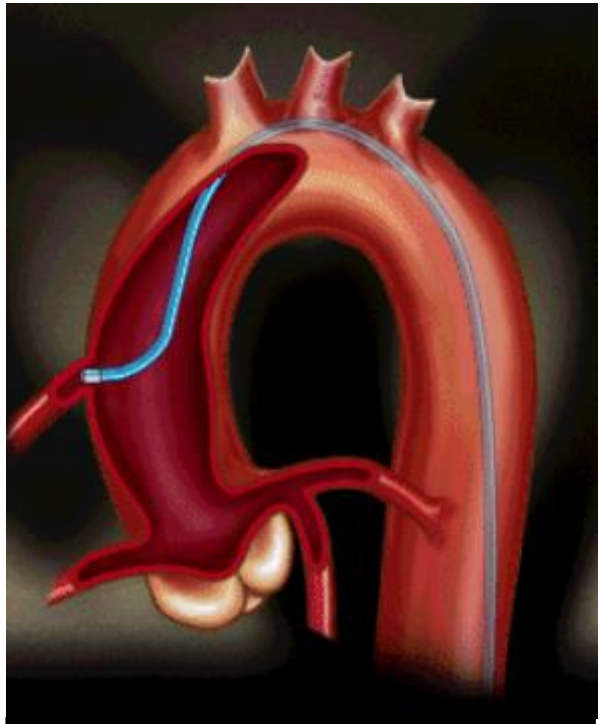

Right Grafts:
JR4
Right Coronary Bypass
Multipurpose

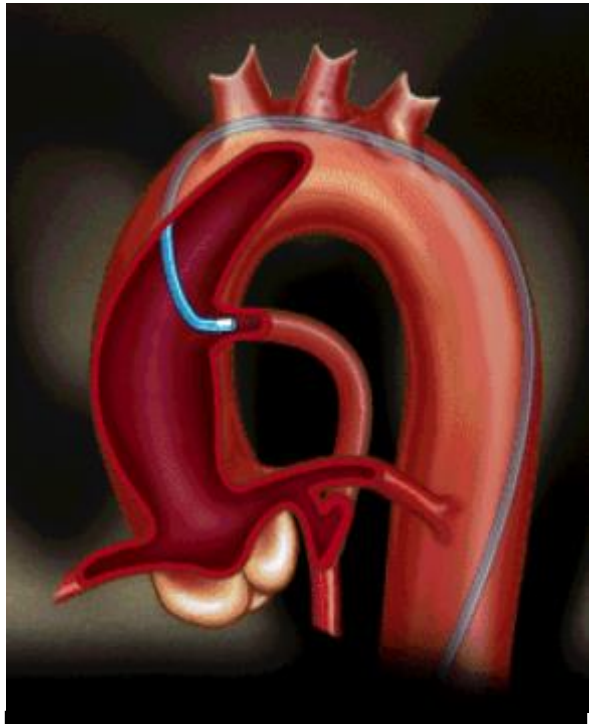

Left Grafts:
Left Coronary Bypass
Hockey Stick
Amplatz Left

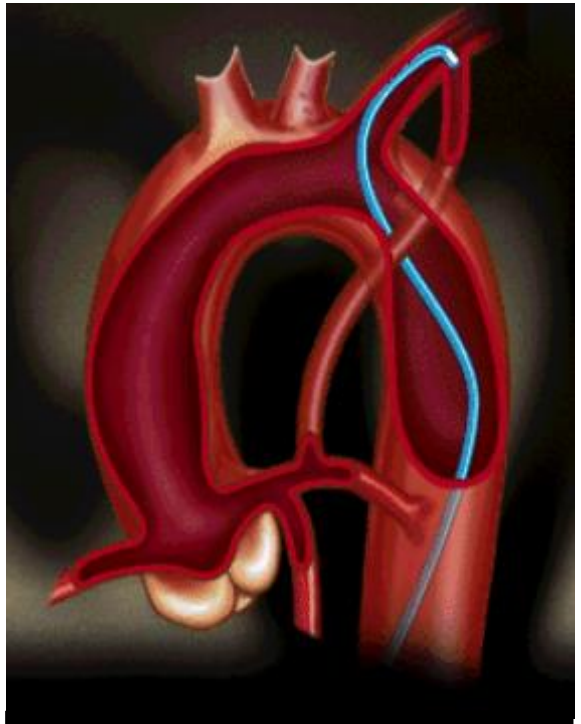

LIMA Graft:
IMA
JR4
LCB

Femoral vs Radial Approach

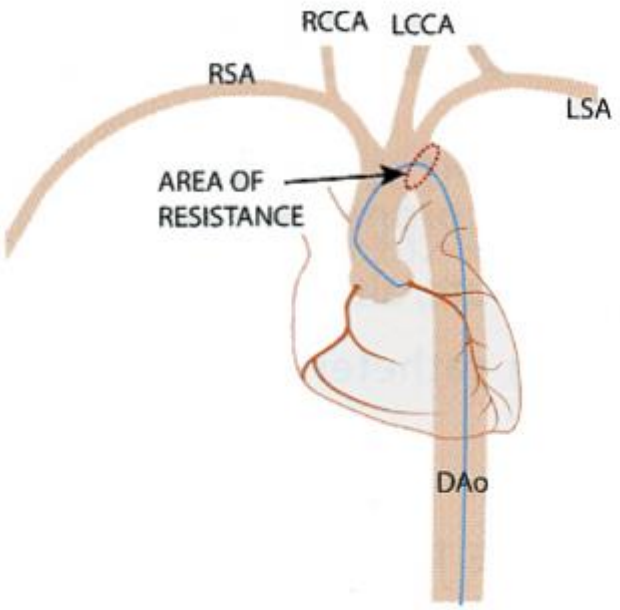

Femoral

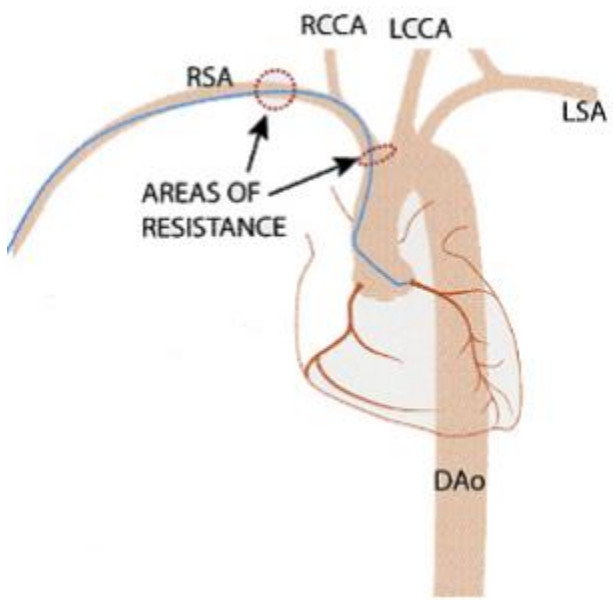

Right Radial

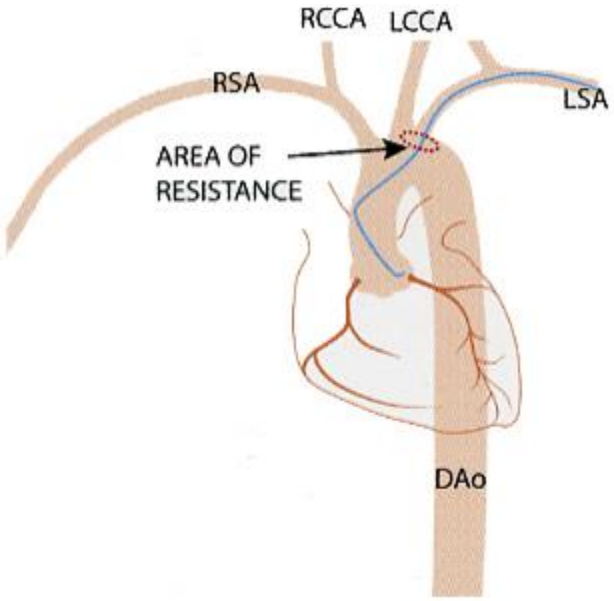

Left Radial

Guiding Catheter Support

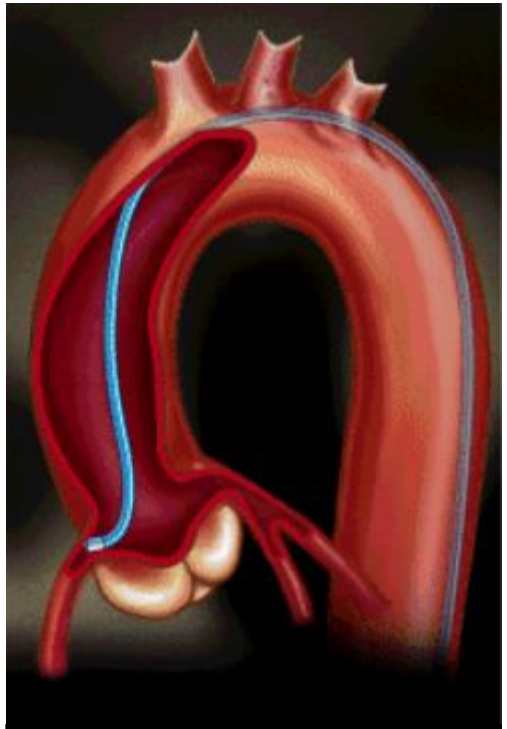

Standard Guide
Minimal Support

JL, JR, RCB & LCB

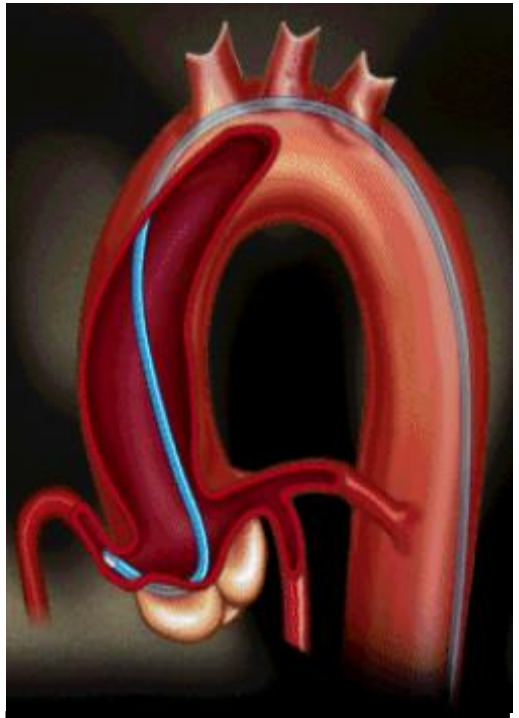

Support Guides derive support from ipsilateral SOV
AL, AR, Hockey stick & Multipurpose

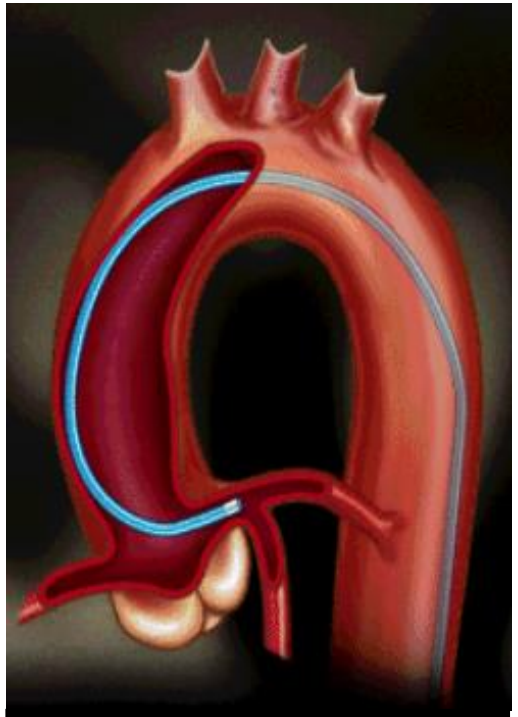

Extra Support Guides derive support from Opposite wall of Aorta

XB, EBU

Active Support

- Manipulation of guide into a configuration conforming aortic root
- Deep Seating of the guide into coronary artery

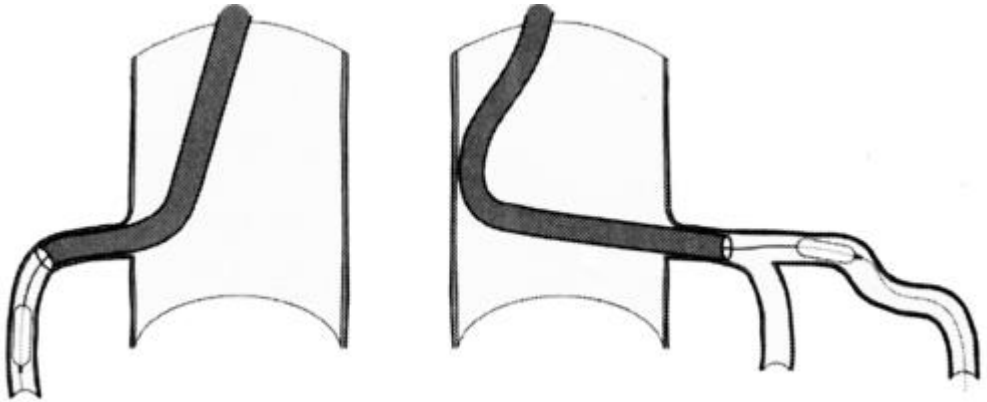

Passive Support

- Rely on inherent shape of the catheter and stiffness
- Minimal manipulation is needed

Guide Catheter Size

	5-6 French Guides	7-8 French Guides	
Pros	• Small arterial puncture • Brachial/radial access • Permit active support • Less contrast • Allows deeper engagement	• Better passive support • Better visualization • Better torque transmission • Kissing balloon/stents, covered stents • Larger Rotablator Burrs (> 2 mm)	Pros
Cons	• Smaller internal lumen • Less visualization • Less torque • Risk of kinking	• Larger arterial puncture • Pressure dampening • More contrast • Risk of vessel injury	Cons

Guiding Catheter with Side holes

- Useful with
  - Small ostia
  - Dampening or ventricularization of pressure
  - Need to deep-seat
- False sense of security
- Do not prevent guiding catheter injury
- Suboptimal opacification
- Reduction in back up support; weak shaft
- Risk of kinking at side holes

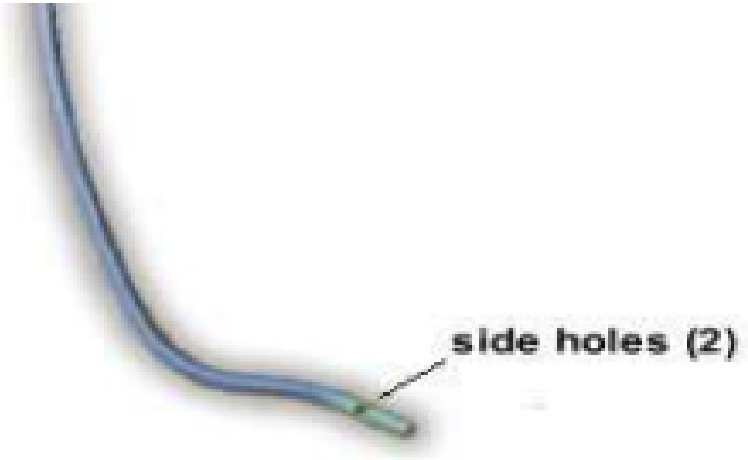

Introduction to Wires

Characteristics of a Coronary Guide Wire

- **Trackability:** Ability of the wire to follow down the vessel
    - Design of the tip
    - Material of core wire
- **Torqueability:** Ability to transmit the rotational force applied
- **Flexibility:** Ability to flex on longitudinal axis
- **Crossability:** ability to cross a lesion with least resistance
    - Interaction between lesion and wire
    - Lubricity
- **Supportability:** Ability to deliver equipment
- **Opacity:** level of visibility under fluroscopy

Guidewire Parts

- Tip
  - Platinum
- Central Core
  - Stainless steel
  - Durasteel
  - Nitinol
- Covers
  - Polymer cover +/- Coils
- Coatings
  - Hydrophilic
  - Hydrophobic

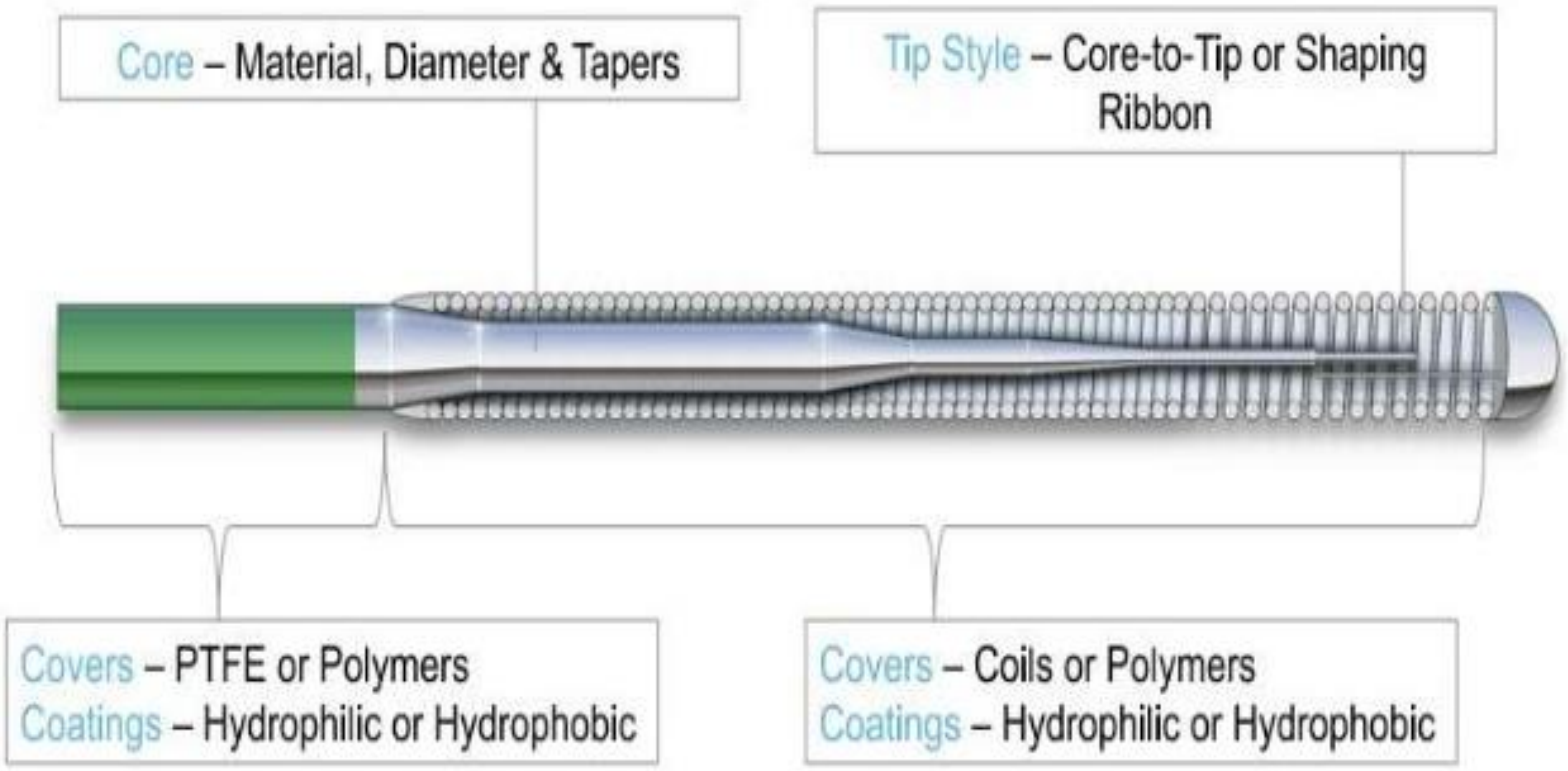

Tip Style

One Piece Core Design: Core to Tip

Precise steering

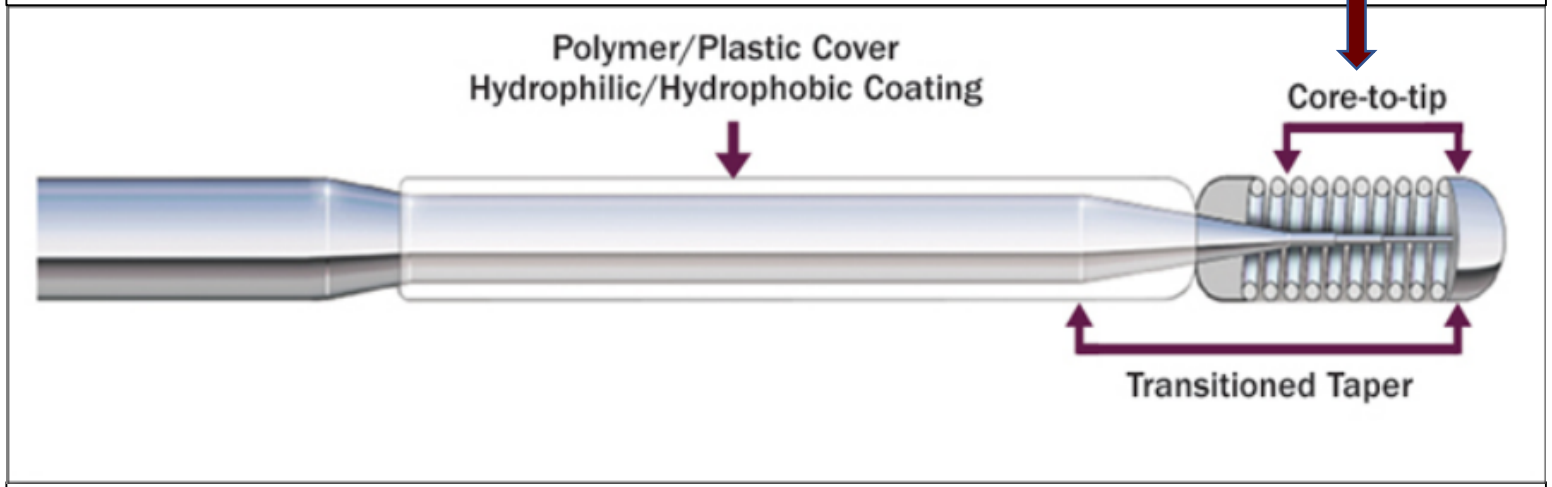

Two Piece Core Design: Shaping Ribbon

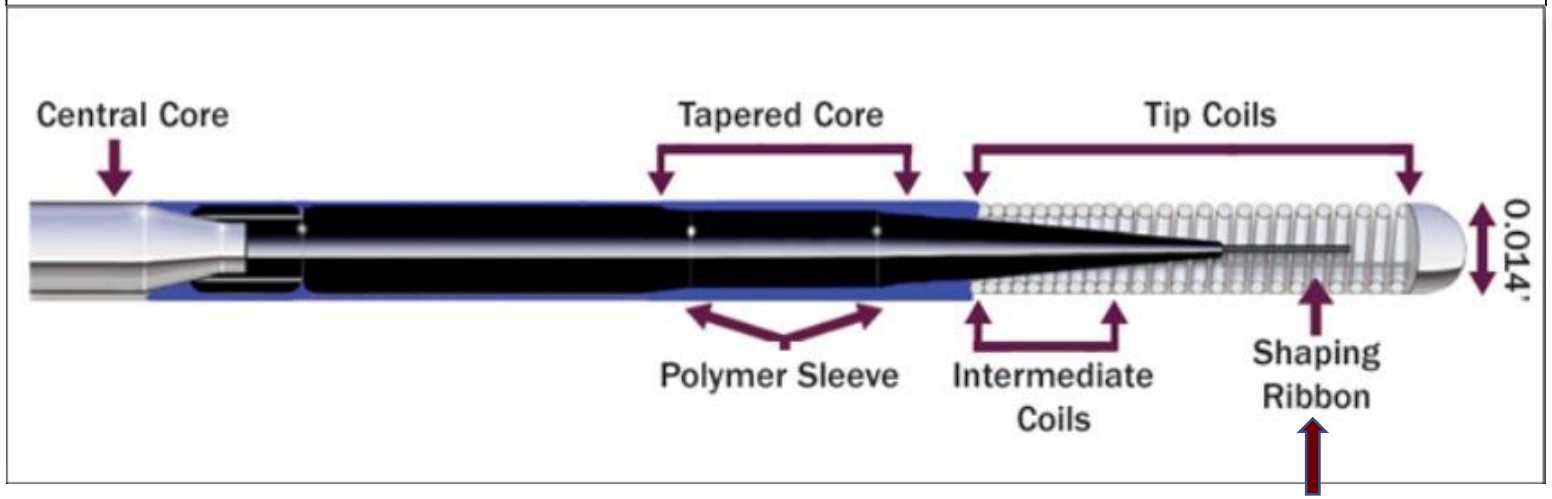

High flexibility atraumatic

Core Diameter

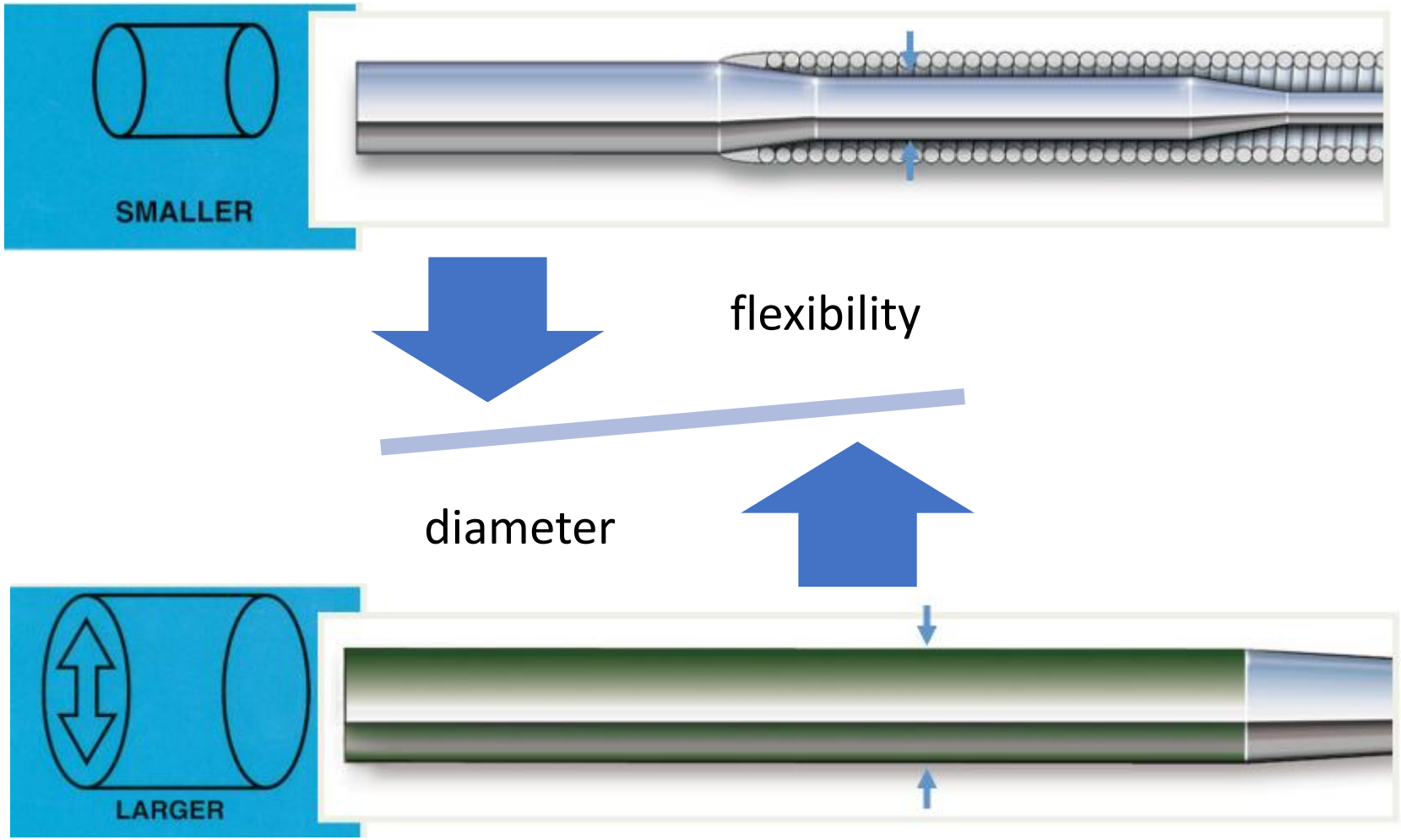

Core Taper

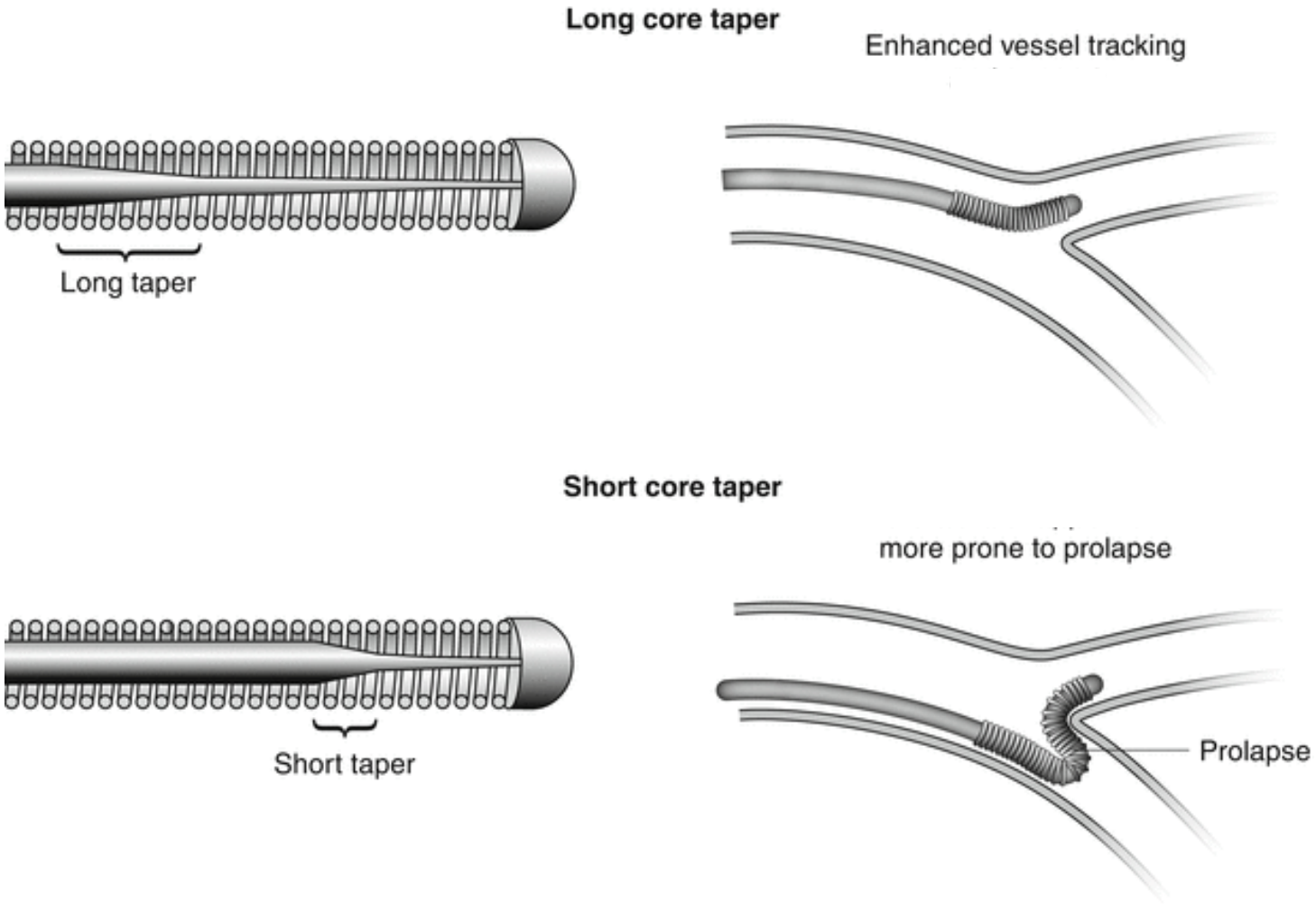
Long core taper
Enhanced vessel tracking
Long taper
Short core taper
more prone to prolapse
Short taper
Prolapse

Core Material

Stainless Steel

Good support

Good push and torque

Less flexible



Nitinol

Kink resistant & Super-elastic

Excellent flexibility and steering

Durable

No memory

Covers

- **Coils**
  - Tactile feedback
  - Resilient tip
  - Radiopacity
- **Polymer/Plastic covers**
  - Lubricity
  - Crossability
  - Smooth tracking
- **Micro-cut Nitinol Sleeve**
  - Precise steerability
  - Torque transmission

Coatings

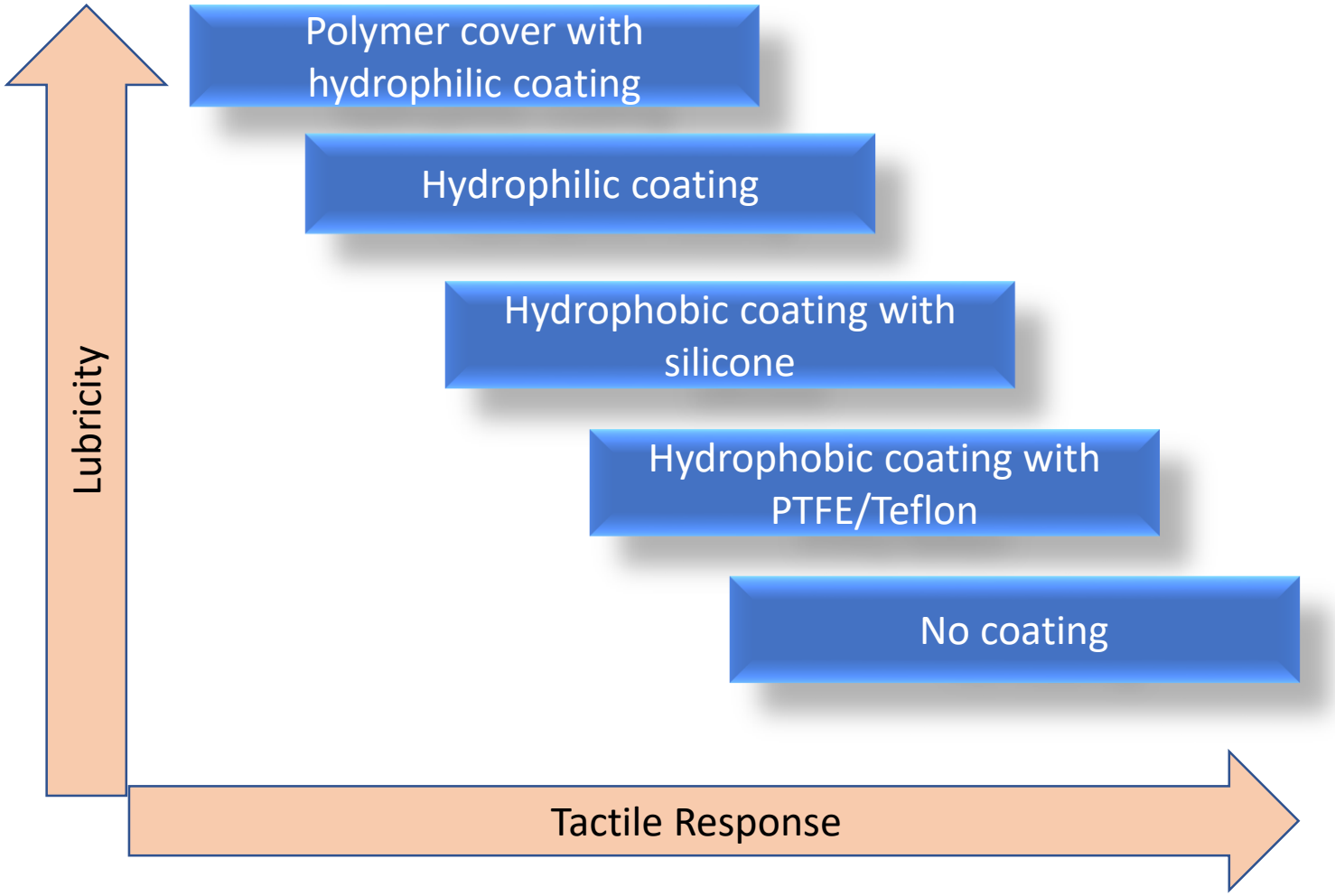
Polymer cover with hydrophilic coating
Hydrophilic coating
Hydrophobic coating with silicone
Hydrophobic coating with PTFE/Teflon
No coating
Lubricity
Tactile Response

Wire Classification

Tip Load

- Floppy: < 0.5 g
- Balanced: 0.5-0.9 g
- Stiff: > 0.9 g

Wire Support

- Light Support
- Moderate Support
- Extra Support

Selection of Guide Wires

Workhorse

- BMW
- BMW Universal
- Advance
- Prowater
- Runthrough

Frontline Finesse

- Whisper
- Pilot 50
- Fielder FC, XT
- Prowater
- Runthrough
- Choice PT
- PT Graphix
- Sion

Extra Support

- Grand Slam
- Buddywire
- Iron Man
- All Star
- Wiggle

Specialty

- Miraclebros 3-12
- Confianza Pro 9-12
- Cross-it 100 XT
- Pilot 150, 200
- Gaia

Guide Wire Selection: Vessel Anatomy

Straight Forward Anatomy

- Start with a workhorse wire
- If unable to deliver a balloon or stent, consider an extra support wire alone or as a buddy wire

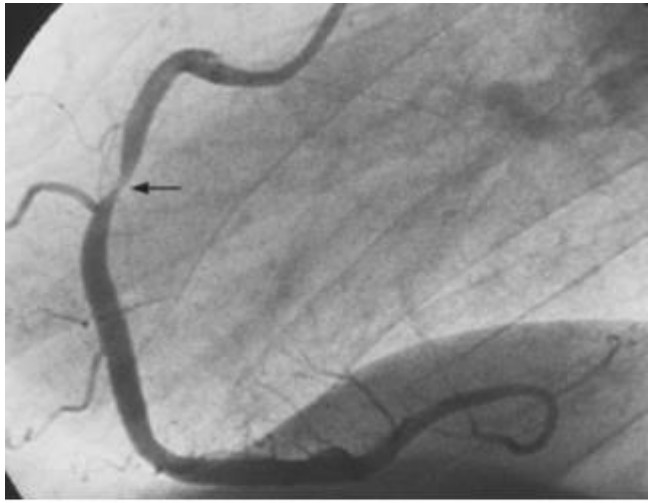

Tortuous or Calcified Anatomy

- Start with a hydrophilic/polymer jacketed wire for reduced friction
- If unable to deliver a balloon or stent, consider using a Wiggle wire

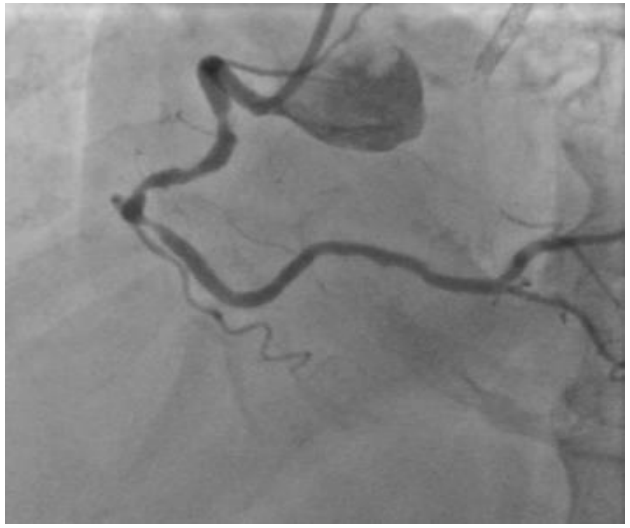

Wire Selection: CTO

0.009” wire and/or hydrophilic coating

Less rail support
Risk of perforation

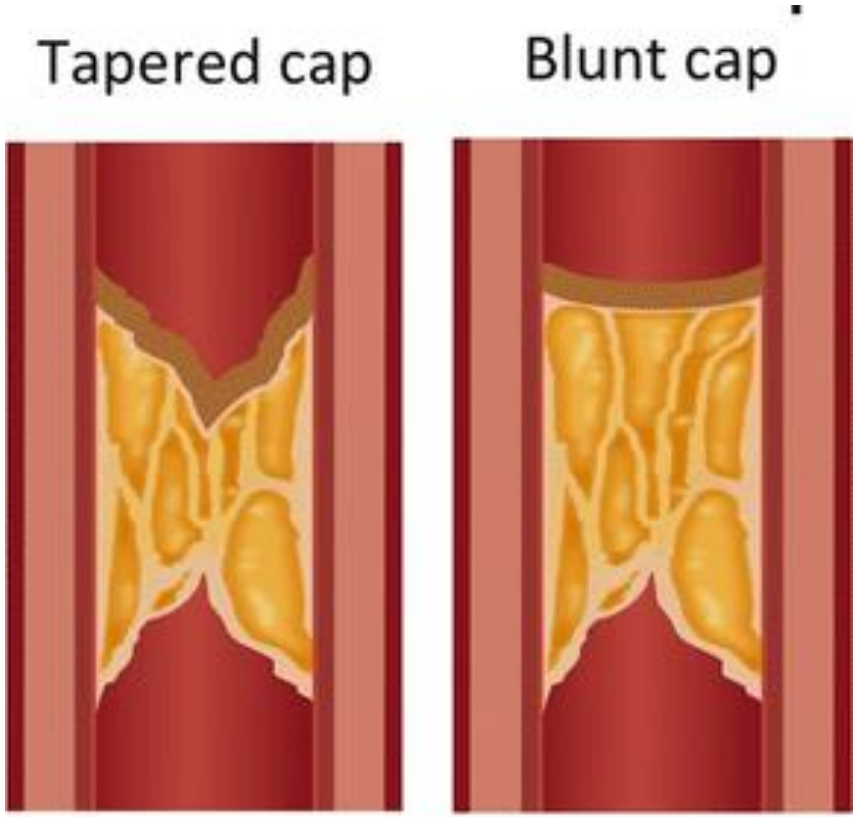

Consider stiff tip

Increased risk of dissection & perforation

Wire Nuggets

Dos

- Appropriate tip shape for lesion/vessel
- Maintain free movement of wire tip
- Prolapsing soft wires can aid in avoiding side branches

Do not

- Undue Force
- Excessive rotation
- Losing wire position

Image Sources:
www.medtronic.com
www.abbott.com
www.scai.org

Thank you

Questions?