Complications of PCI and Their Management

Annapoorna S. Kini, MD, MRCP, FACC

Director, Cardiac Catheterization Lab

Director, Structural Heart Disease Program

Director, Interventional Cardiology Fellowship Program

Zena and Michael A. Wiener Professor of Medicine

Coronary Complications

CENTRAL ILLUSTRATION: Epidemiology of Mechanical Complications During Percutaneous Coronary Intervention

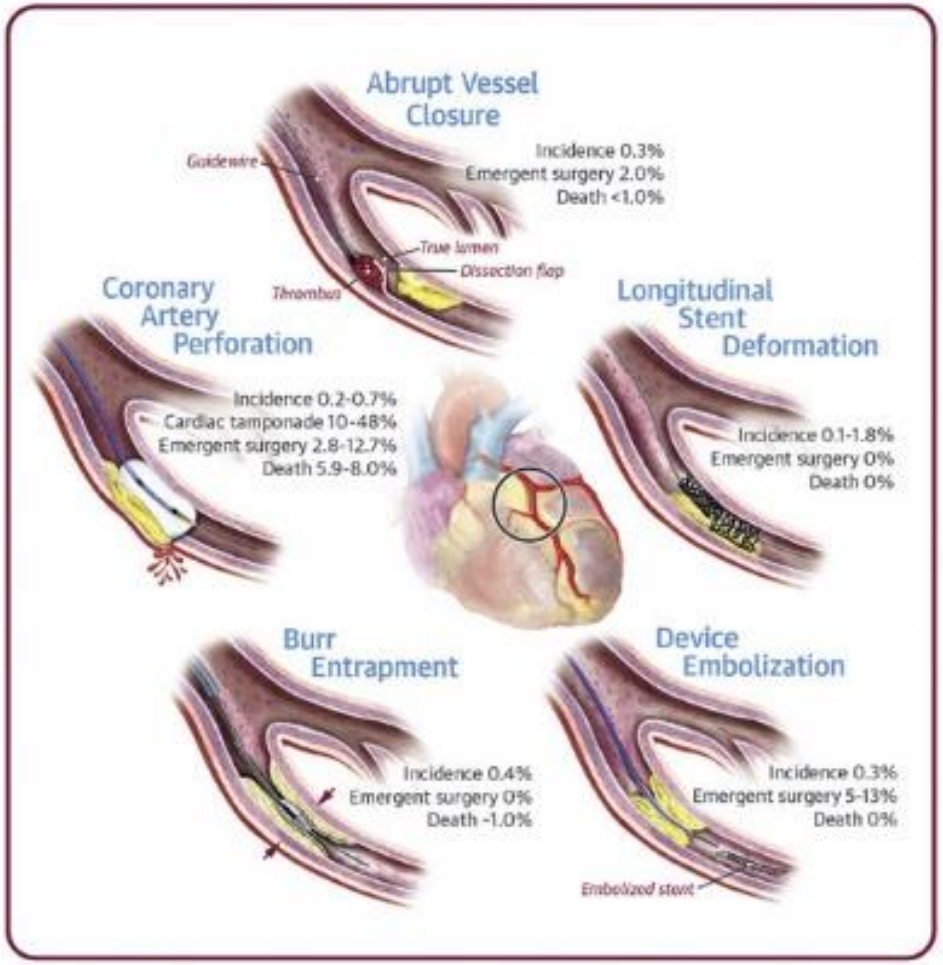

Giannini, F. et al. J Am Coll Cardiol Intv. 2018;11(18):1797-810.

- Coronary Dissection
- Slow-Flow / No Reflow
- Thrombus
- Wire Perforation
- Air Embolism / Vasospasm
- Guide-Induced Dissection

PCI Complications: NY State Hospitals

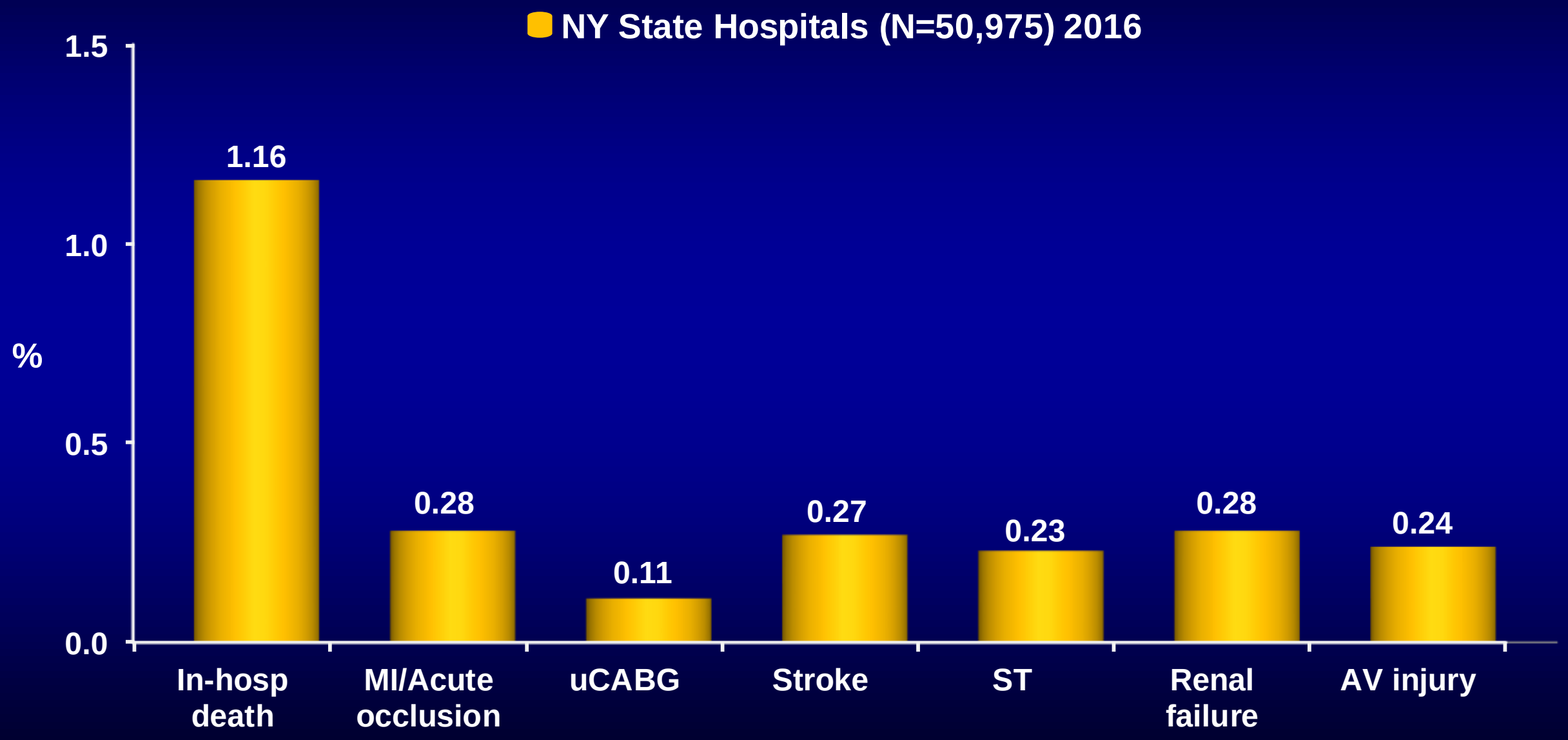

PCI Complications: ACC-NCDR Hospitals 2018-19

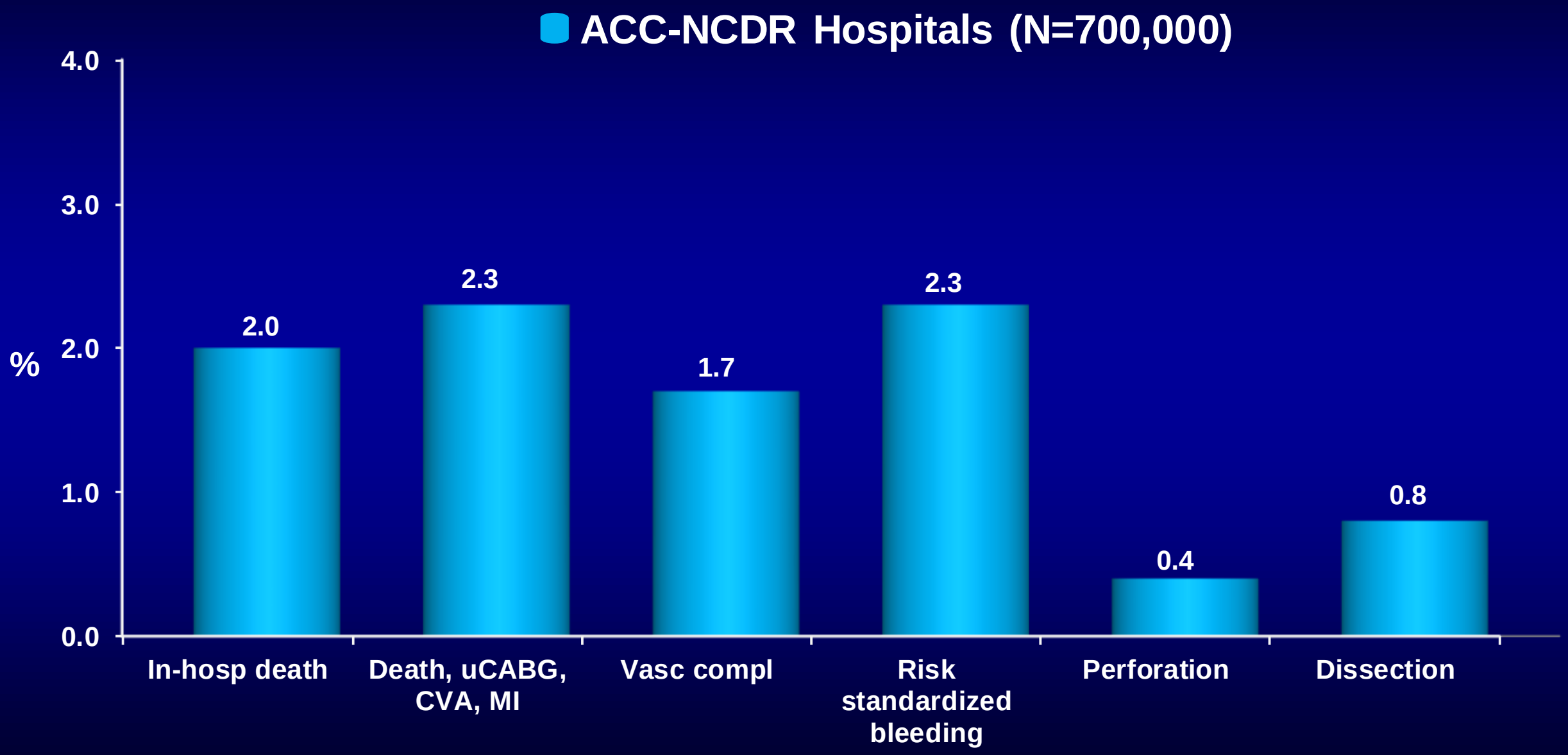

CCC LIVE CASES

Watch our monthly live webcasts from our new and improved website!

www.ccclivecases.org



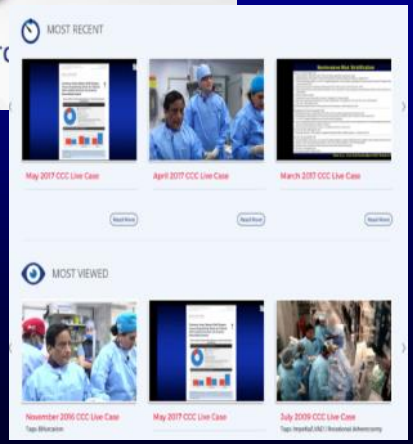

COMPLEX CORONARY CASES
Occurs 3rd Tuesday of the month at 8am

LIVE PERIPHERAL INTERVENTIONS
Every 4th Wednesday at 8am

STRUCTURAL HEART LIVE CASES
Every other Tuesday at 9am

www.ccclivecases.org

www.ccclivecases.org

CCCLiveCases.org: June 18 2013

Case #1 June 2013 CCC Live Case: 62yrs M

Presentation:

Pt with prior CABG (8/2004) and DES PCI of prox LAD (10/2004) for occluded LIMA, presented on 6/4/2013 with new onset class I angina and Stress echo +for moderate ischemia in apical and infero-lateral areas with LVEF 55%. Cath @OSH revealed 2 V+LM CAD with 99% in-stent restenosis of prox LAD DES and occluded SVG to OM1. Re-do CABG was recommended but declined.

Prior History:

Hyperlipidemia, NIDDM, Hypertension, s/p CABG and PCI

Medications:

Aspirin 325mg, ISMN 60mg, Atenolol 25mg, Metformin XL 500mg, Atorvastatin 20mg

Case #1 June 2013 CCC Live Case: 62yrs M

Cardiac Cath 6/4/2013: Right Dominance

2 V+LM CAD with LVEF 55%

Left Main: distal 70%

LAD: 99% prox DES ISR large vessel and fills via RCA

LCx: 90% prox and moderate diffuse distal vessel

RCA: moderate diffuse disease

Plan Today:

PCI of distal LM/LAD and prox LCx

Initial LVG and angiography

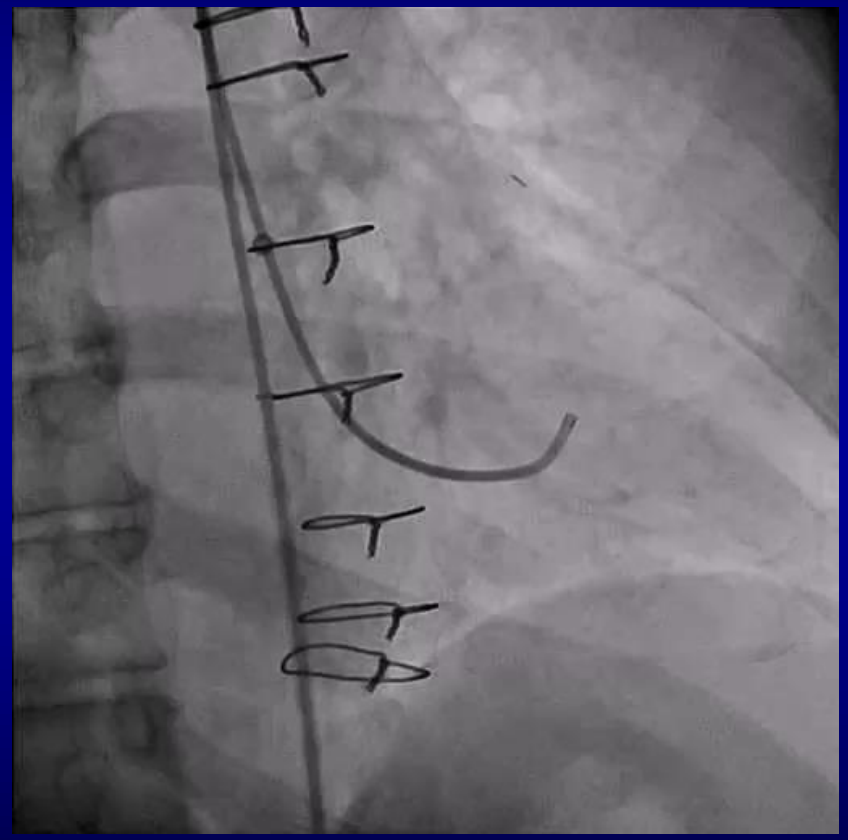

LVG (preserved EF)

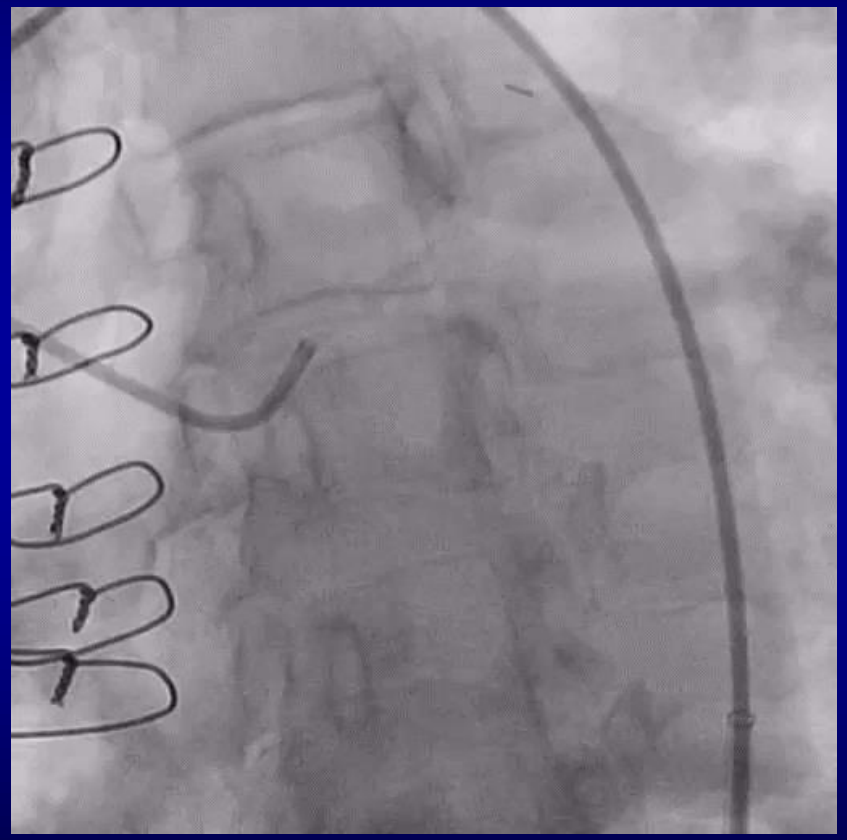

LCA (target)

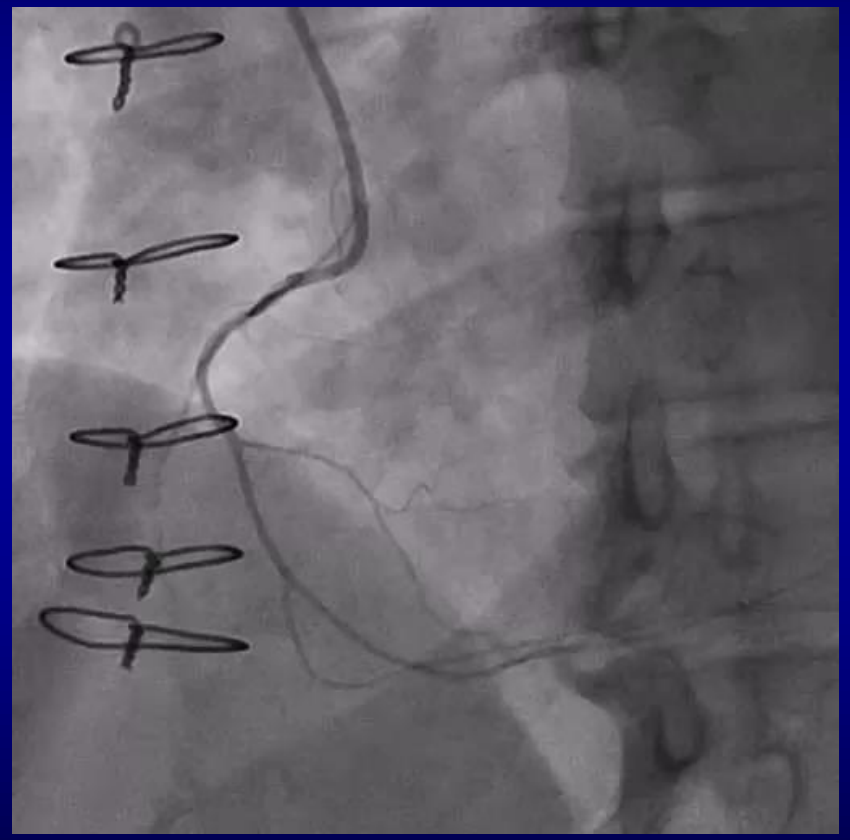

Non-dominant RCA

Left coronary angiography (picture)

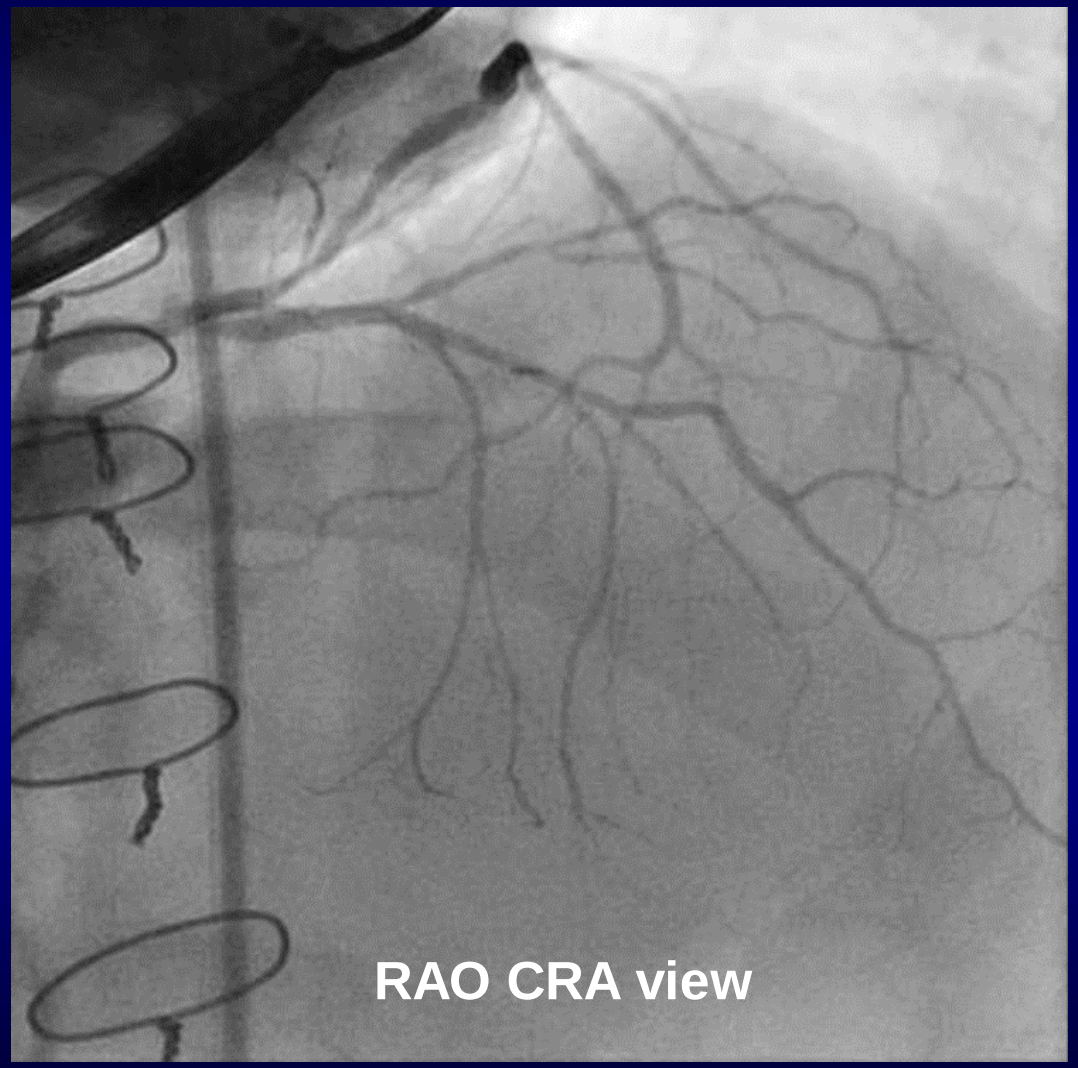

What will you recommend for this pt?

A. PCI

B. PCI with LV support (IABP or Impella)

C. Re-do CABG

D. Continue MMT

PCI of LM bifurcation

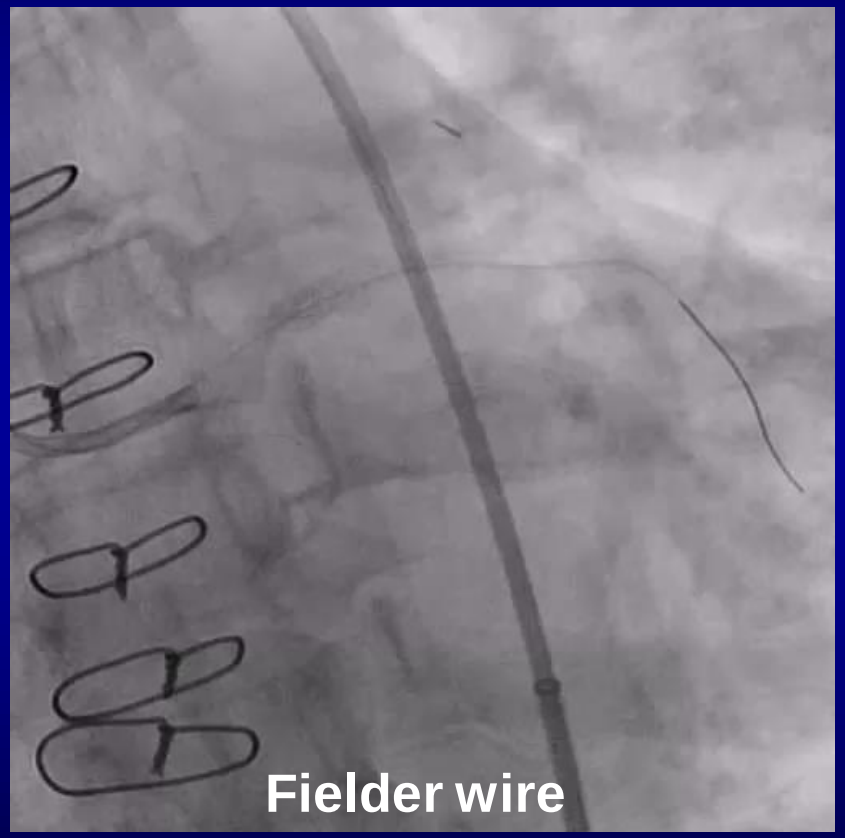

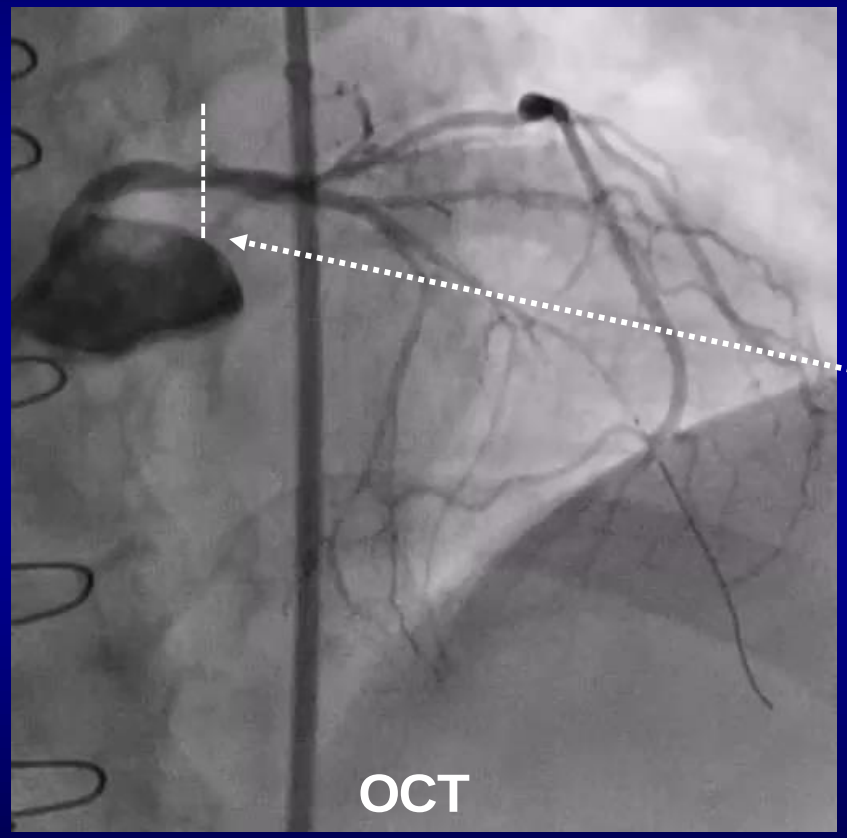

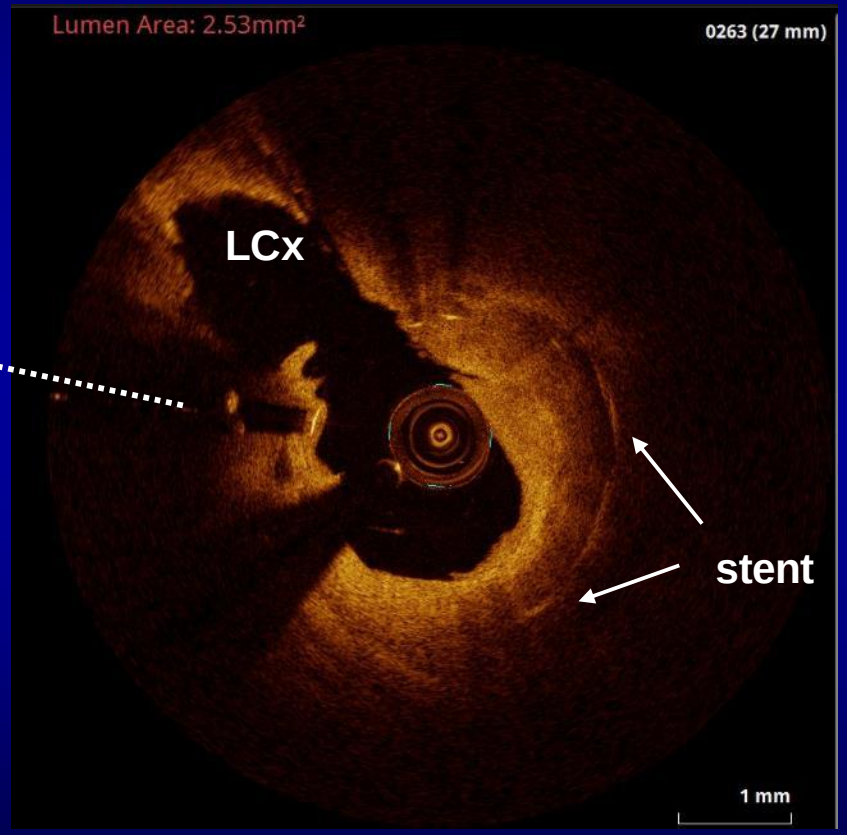

Heterogeneous DES-ISR and LCx was jailed by old stent

Will you wire the circumflex if planning to use cutting balloon of LAD ISR?

A. YES

B. NO

PTCA of LM-LAD

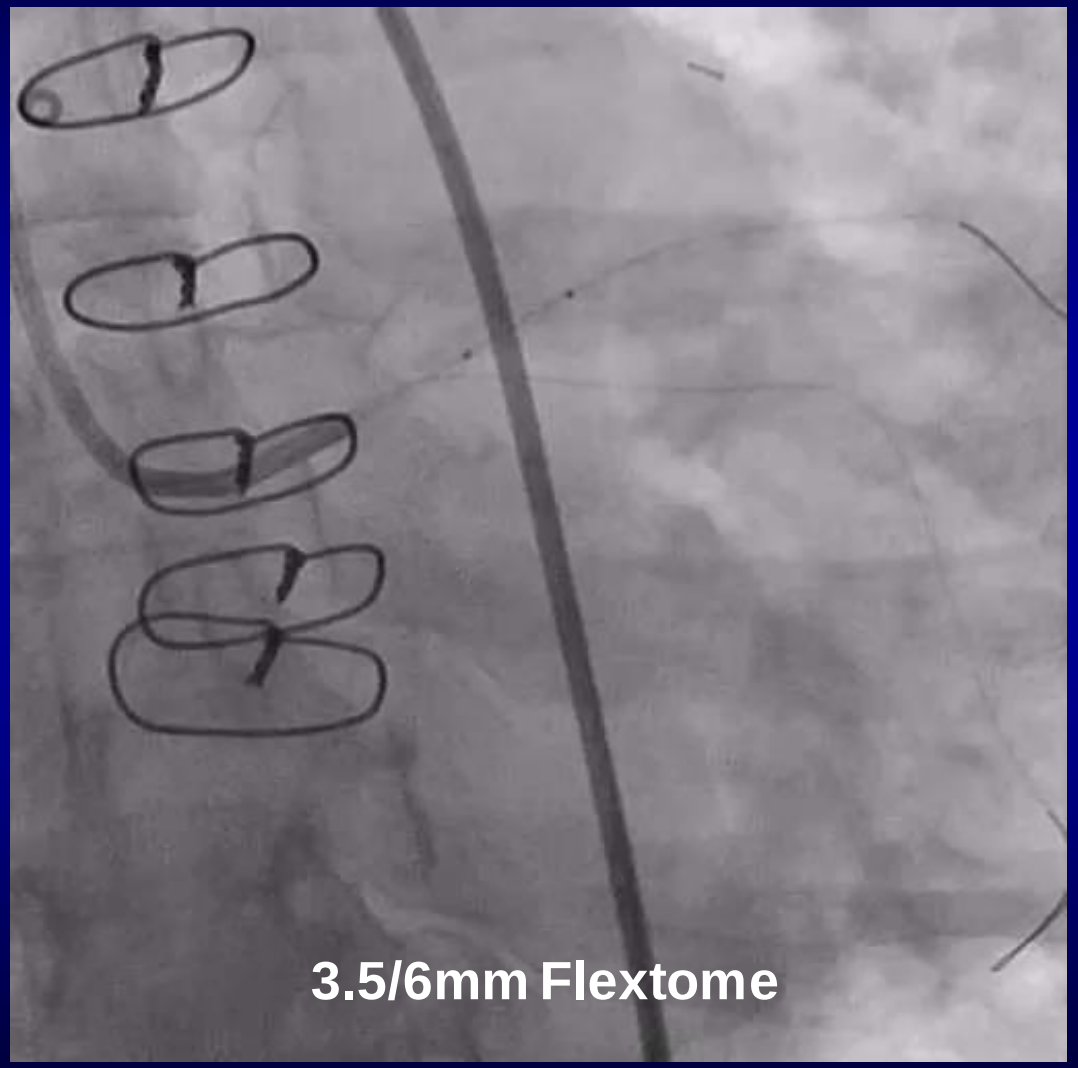

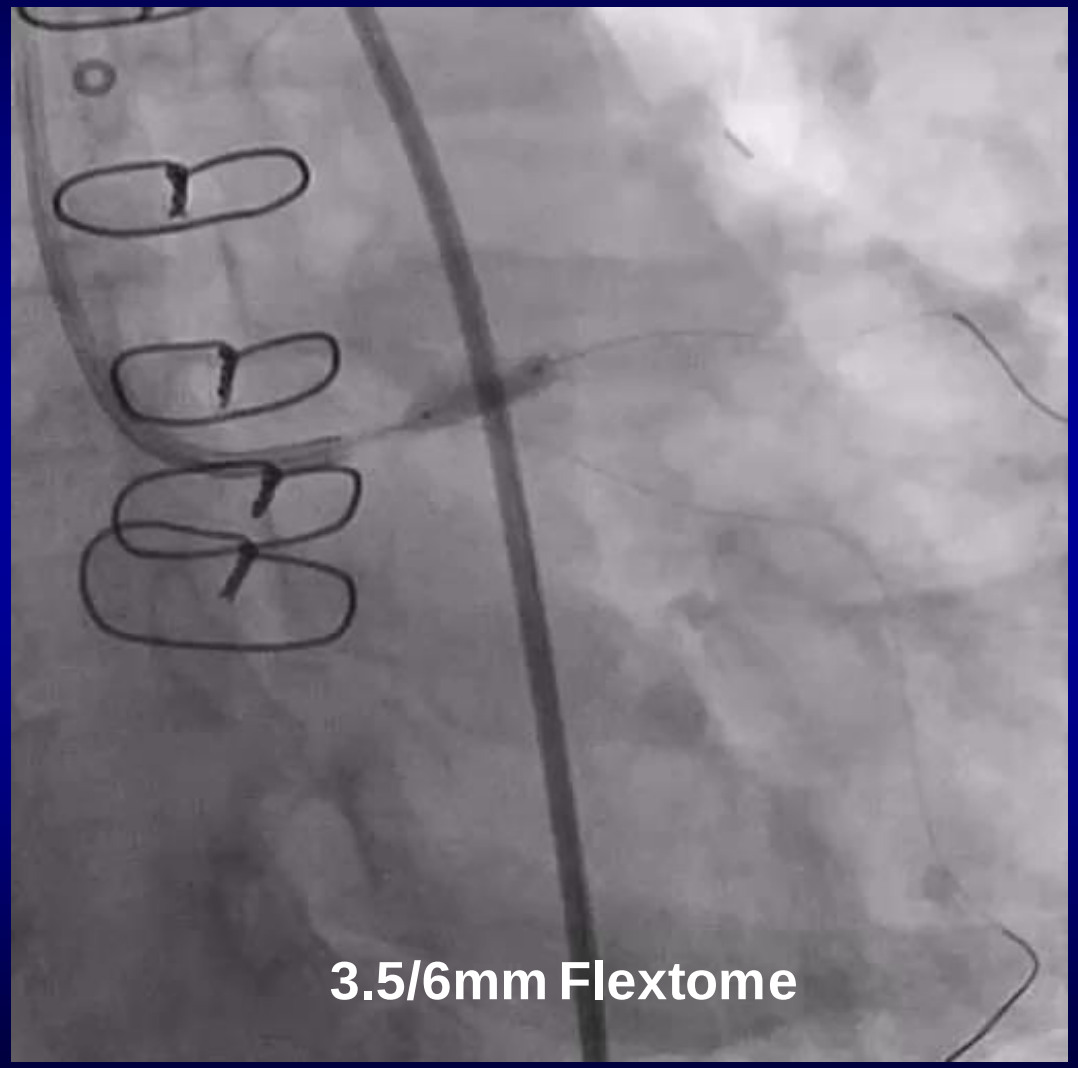

Acute closure of LM

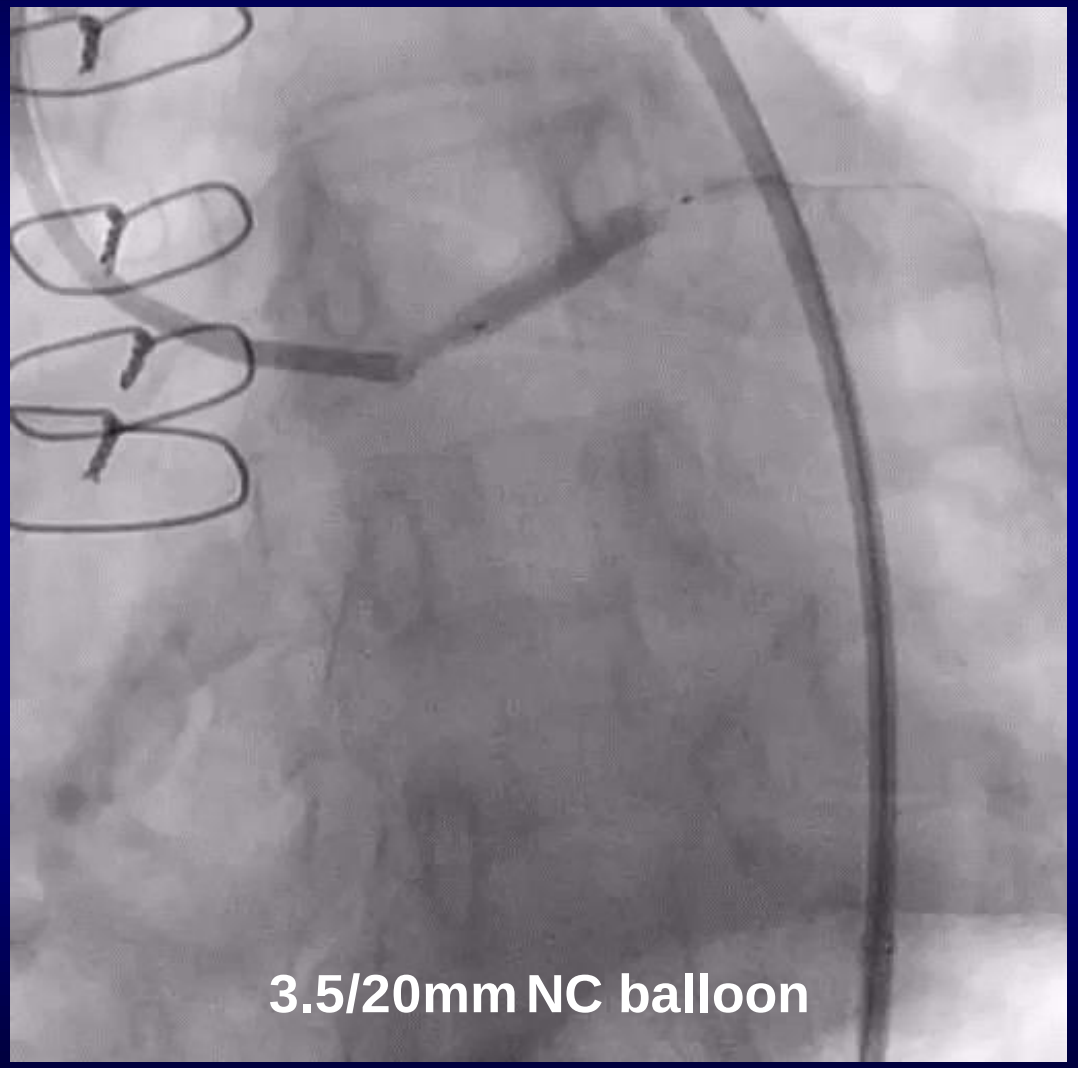

Acute Closure of LM:
Pt moved his legs due to chest pain and Guide+ all equipment were dislodged.

Pt had refractory Vfib requiring shocks and ACLS protocol for approx 25 minutes. LM/LAD wired and a 3.5/20mm NC balloon Inflated and continued in Vfib

ACLS

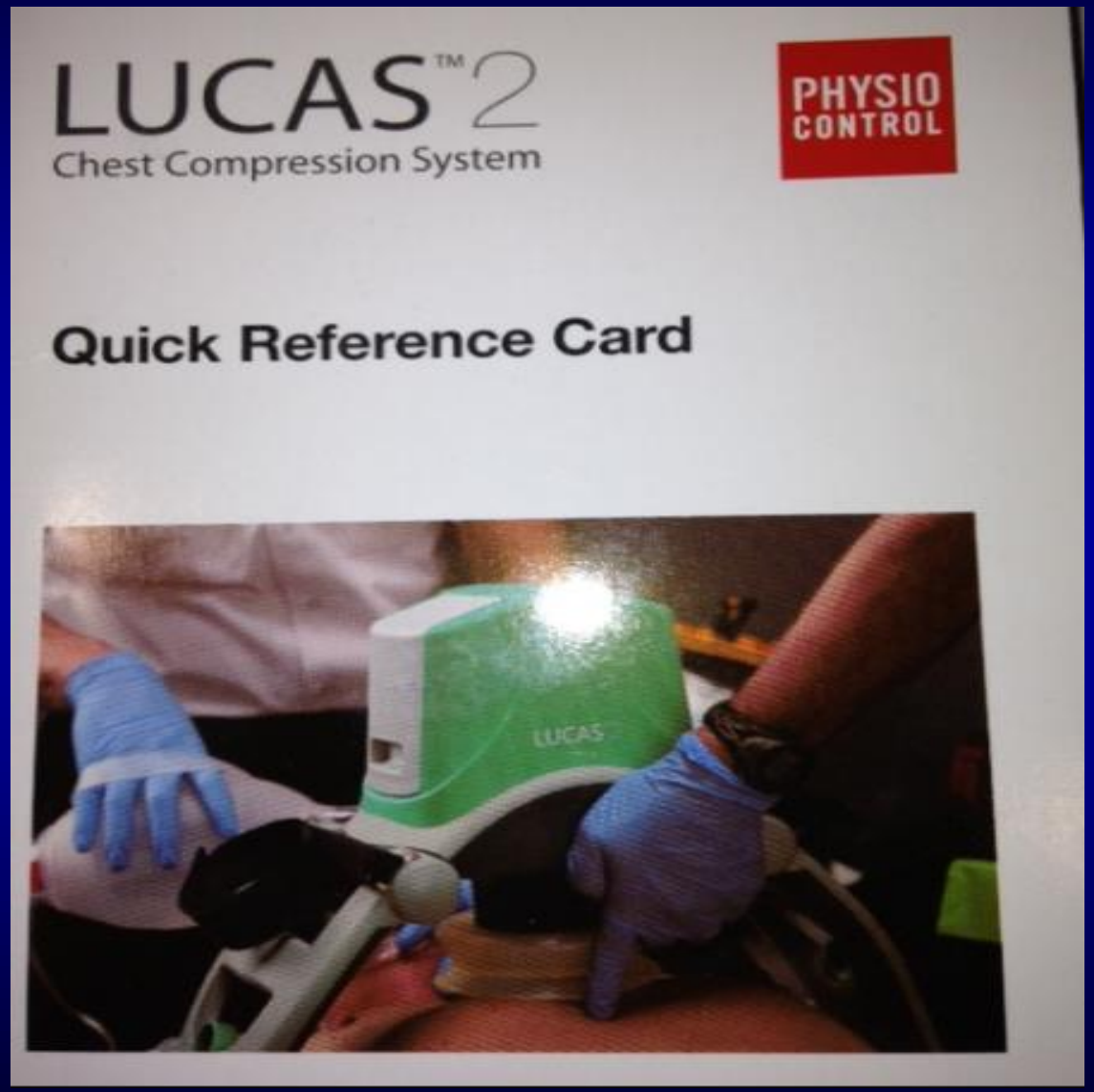
LUCAS™2
Chest Compression System
PHYSIO CONTROL
Quick Reference Card
LUCAS

IABP

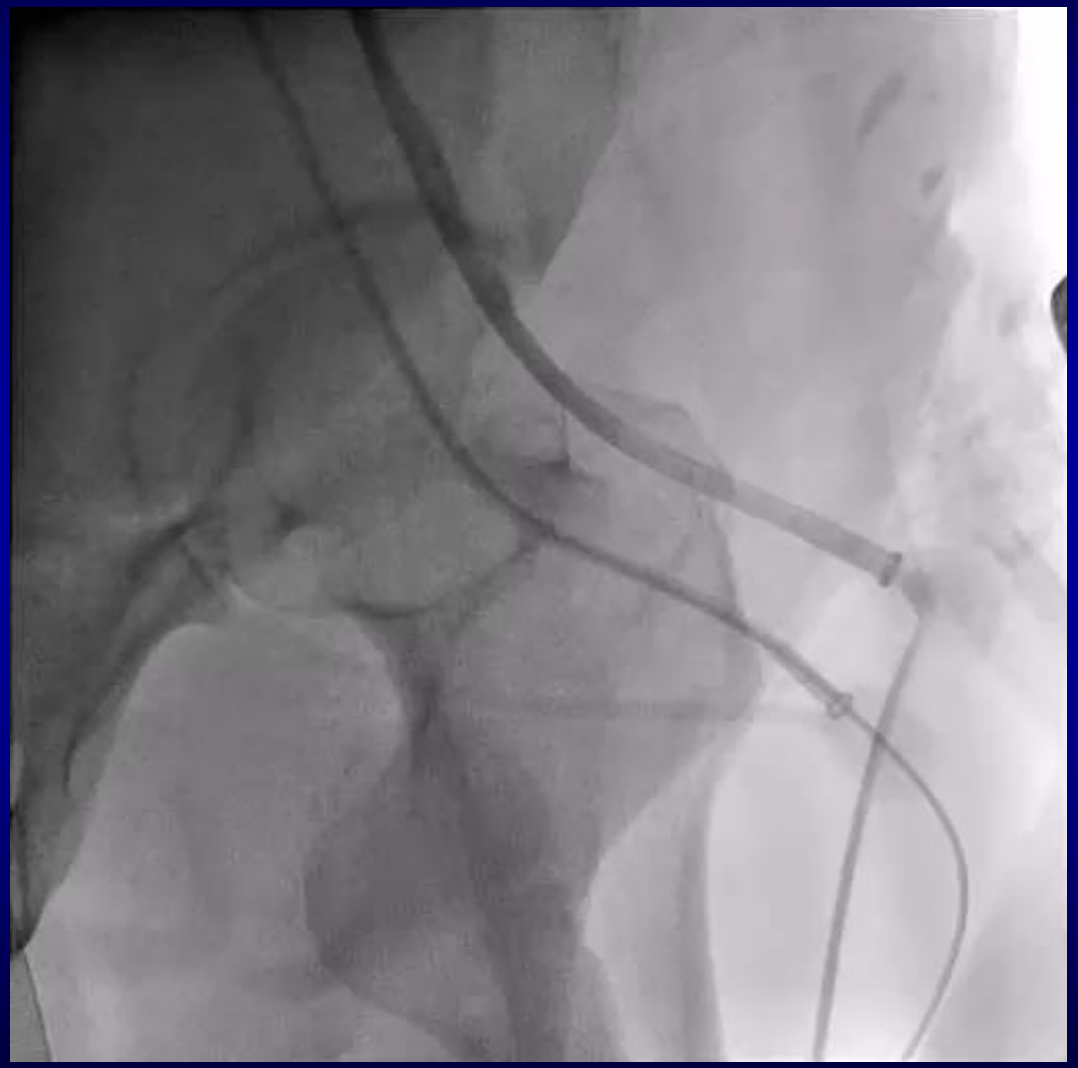

IABP inserted and CT surgeon called and felt pt to be very unstable to take to OR As well as unclear mental status with prolonged CPR

What will be your plan?

A. Insert LM/LAD Stent while in VFib

B. Insert Impella

C. Call another cardiac surgeon

D. Quit now as all resuscitation measures have failed (>60 minutes)

ECMO

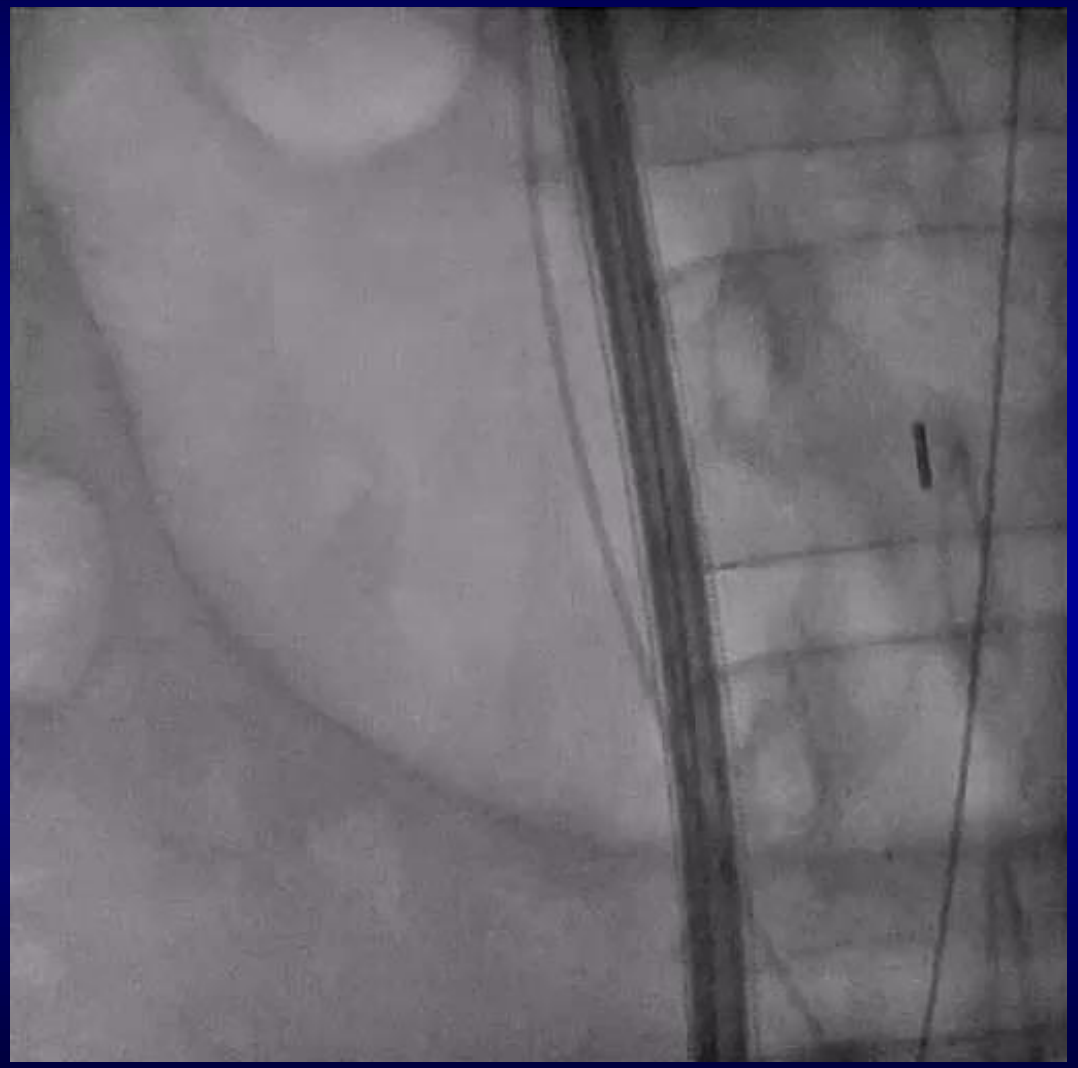

Decision to insert ECMO to stabilize hemodynamics was made

PTCA of LM-LAD

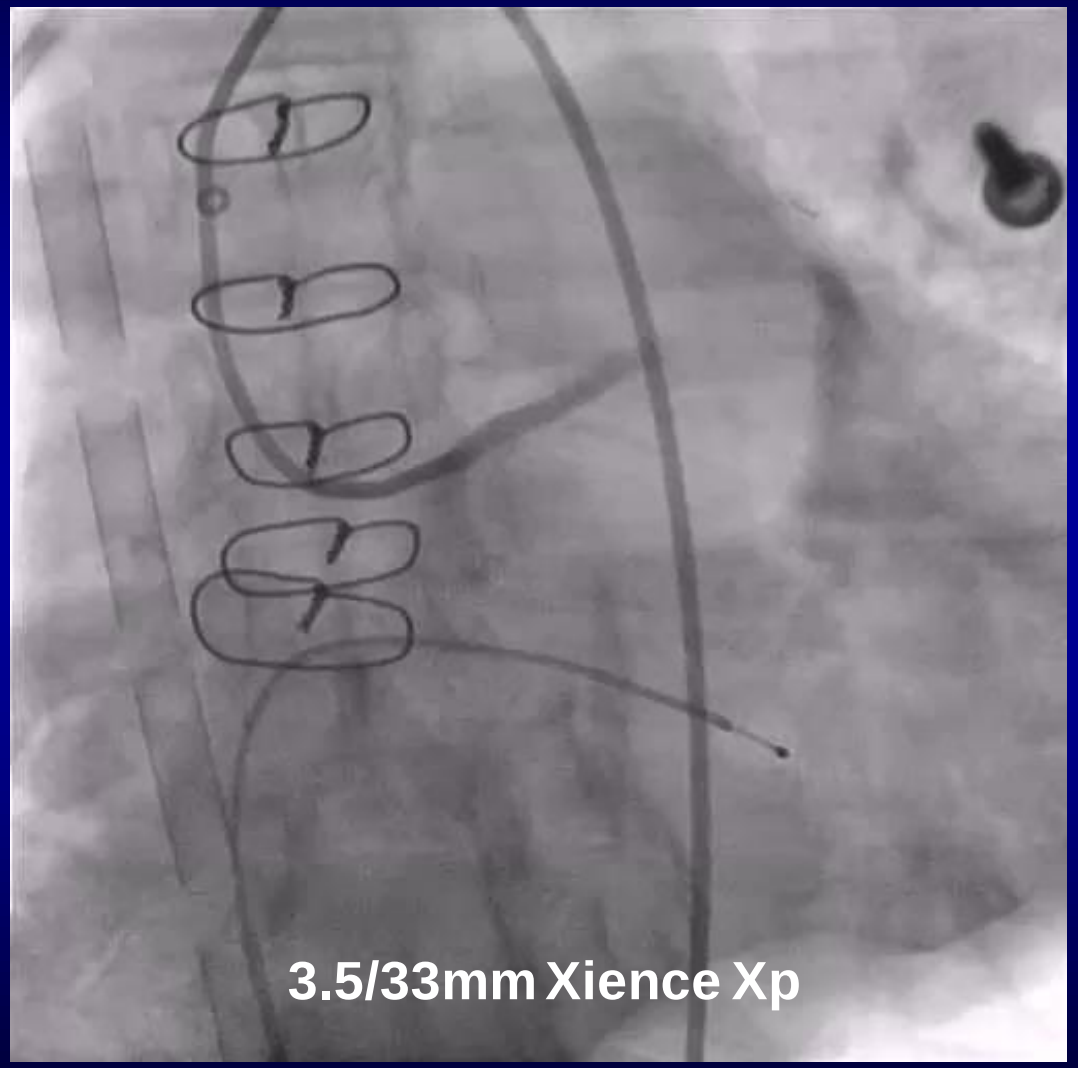

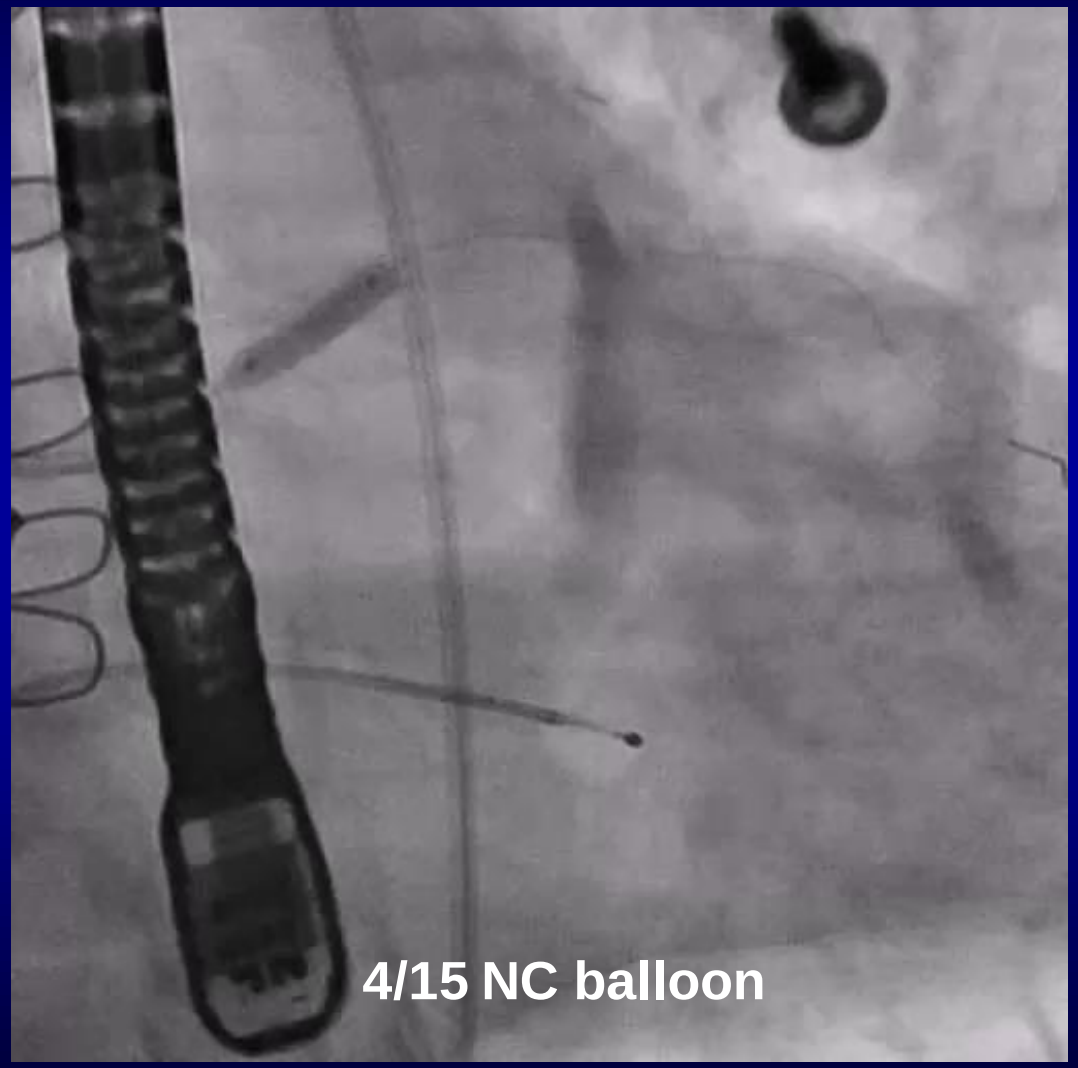

Restore of LM-LAD flow

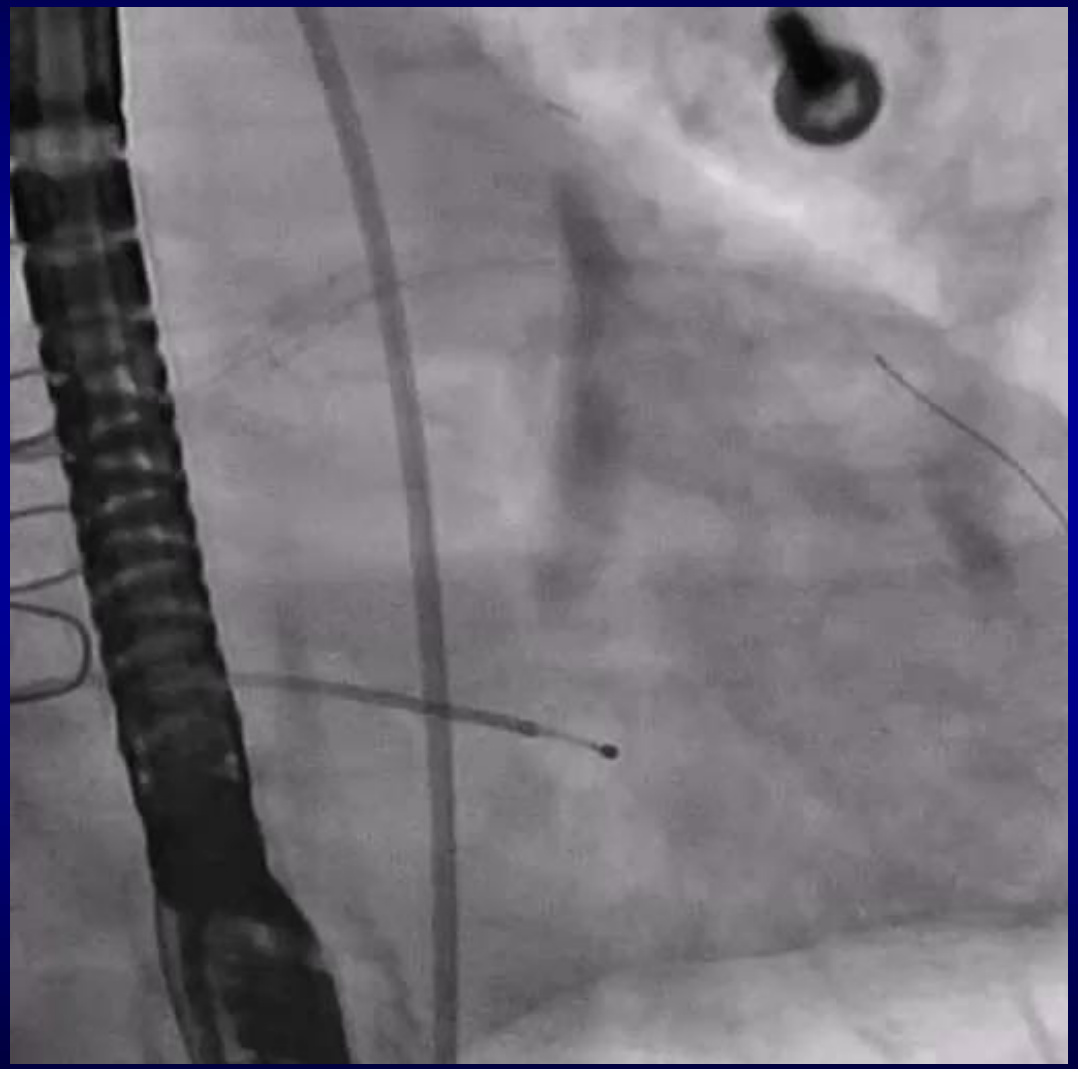

Rescue LCx

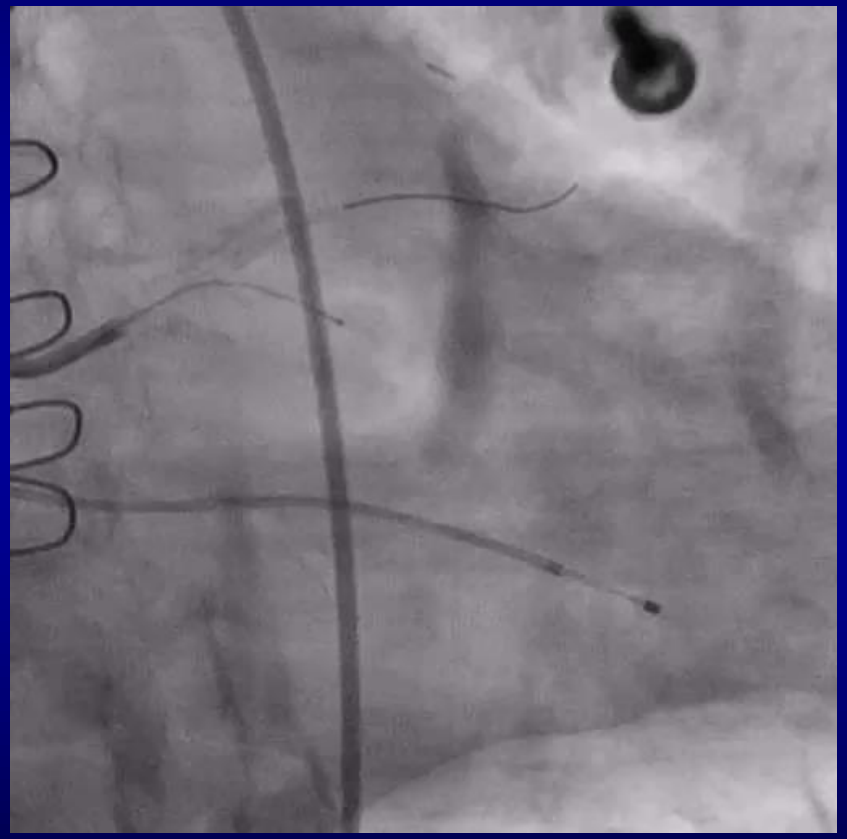

Fielder wire

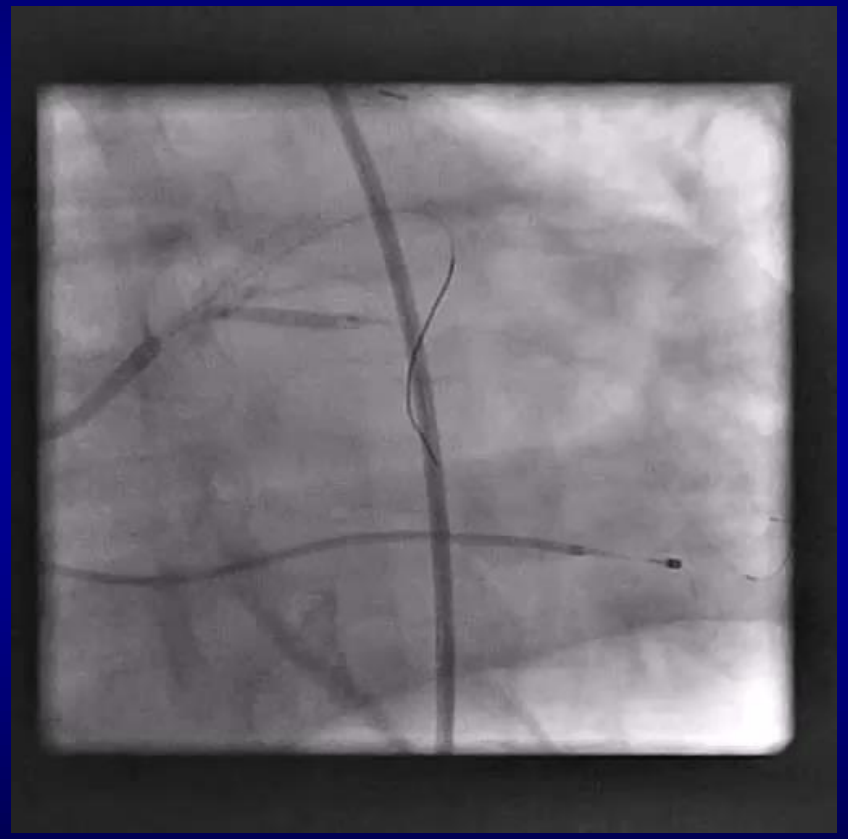

Mini TREK 2.0/15mm

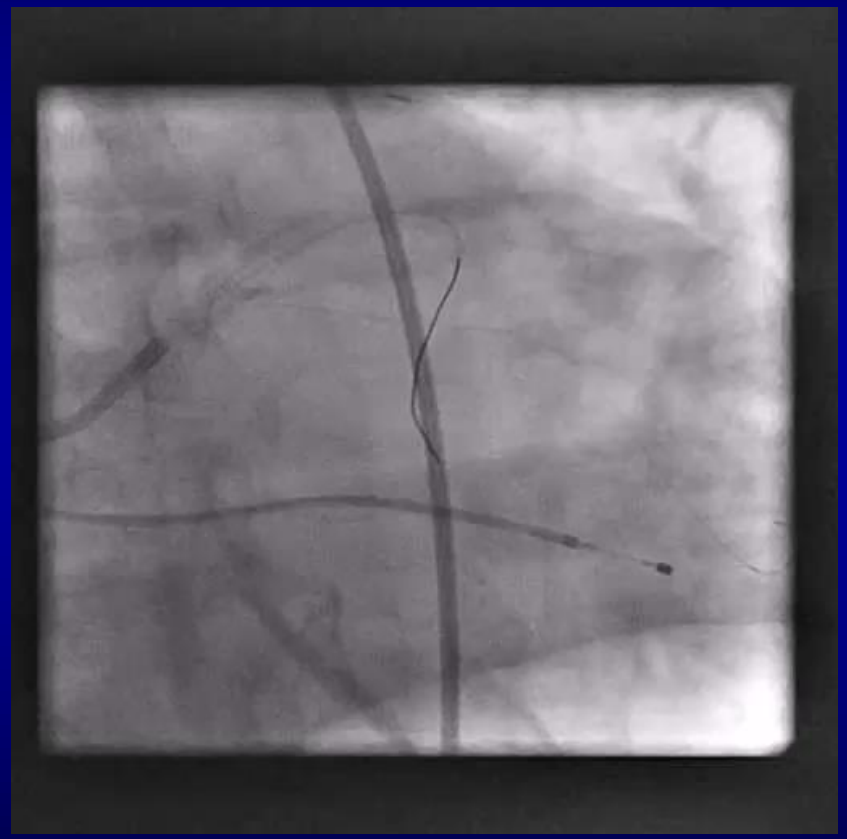

AngioSculpt 3.0/10mm

Final KBI

3.0/38mm Xience Xp in the LCx

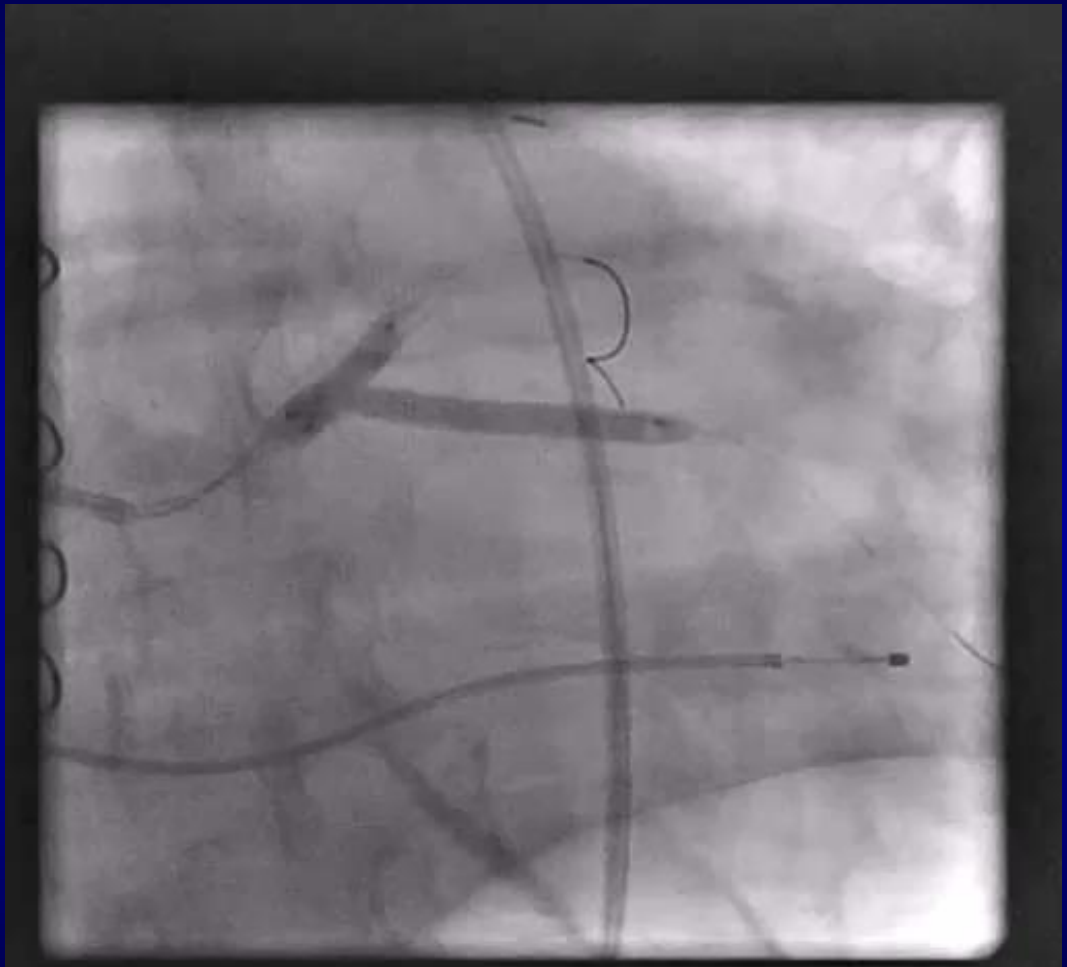

Final KBI

Final

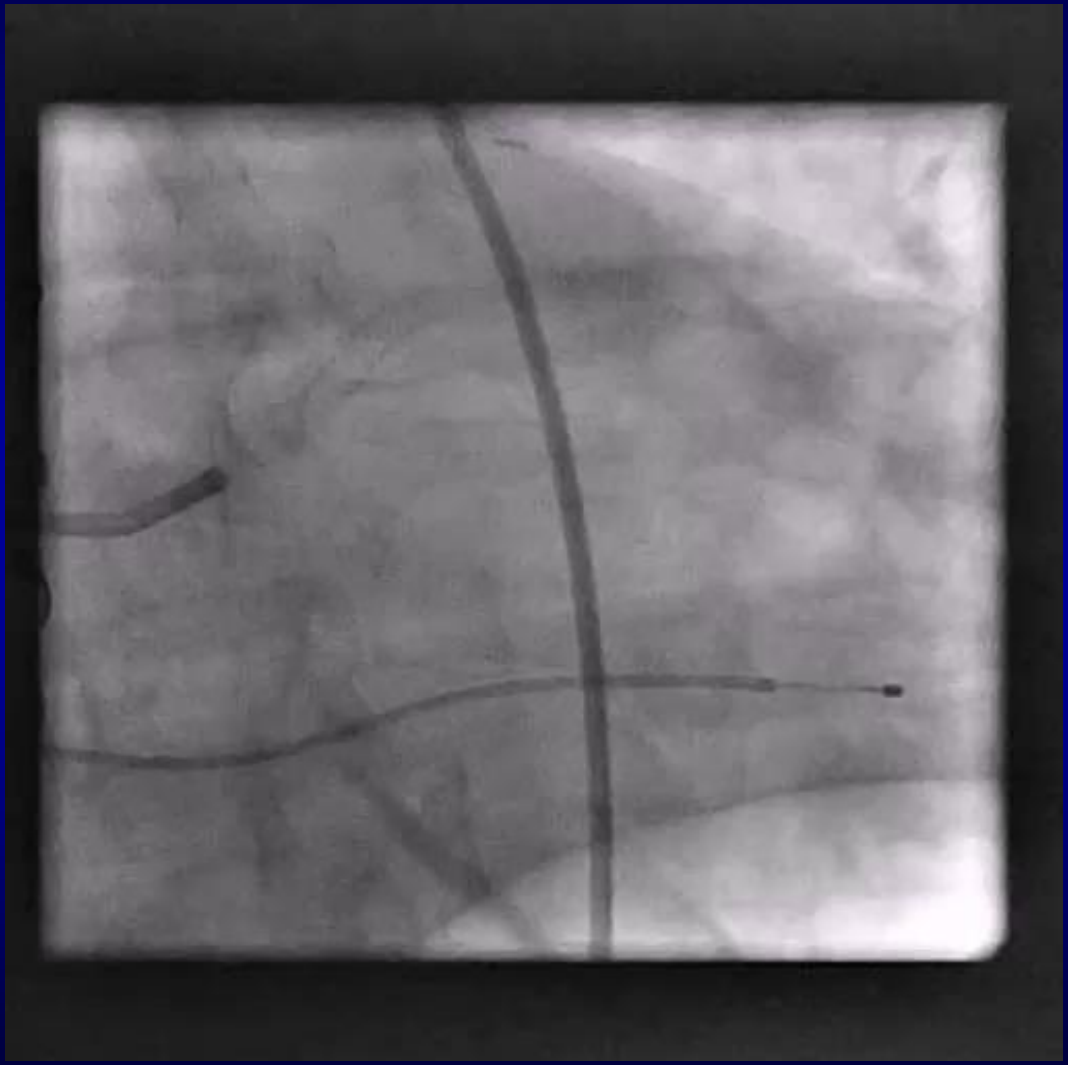

Subsequent Hospital Course and Outcome

- Patient gradually improved, ECMO cannulas removed after 2 days, recovered fully and finally discharged home after 15days with LVEF of 52% and no other neuro residual deficit or limitations
- On F/U at one year no further cardiac symptoms or restenosis

Learning Objective:

Cath lab catastrophe can happen even in the best hands and once occurs, a team effort of cath lab team and CT surgical team and use of LV assist (ECMO) devices, will give the chance to the patient for best possible outcomes; like this pt.

'Patient in the Mount Sinai cath Lab after CV collapse during PCI, survived with good outcome not because of luck but due to expertise of the operators and a system equipped and geared to take care of these anticipated cath lab catastrophes'

Spencer King, JACC Intervention Sept 2013

CCCLiveCases.org: June 18 2013

JACC: CARDIOVASCULAR INTERVENTIONS
VOL. 6, NO. 8, 2013
ISSN 1936-8798/$36.00
10.1016/j.jcin.2013.07.001

PUBLISHED BY ELSEVIER INC.

EDITOR'S PAGE

The Case for Live Case Demonstrations

Whether to perform live case demonstrations or not will continue to be discussed, but my view is that, as diligent as we must be to avoid complications, it is from these adversities that we learn the most.

The discussion of whether interventional cases should be demonstrated and
interventional cardiology itself. In fact, it precedes interventional cardiolog
"theater" was indeed a place for the "show." Demonstration has been acce
component of the educational process in our specialty. The dual objectives
demonstration, the care of the patient, and the instruction of others, are n
because the care of the patient must always be primary. I have discussed t
previously (1), and attempts at studying the safety and value (2) have gener
side of the worth of live cases, although such assessments are perhaps not wi
been witness to situations in which the safety of the patient did not seem to
goal, and this should never be repeated.

Believing that there is educational value in live case demonstrations, the American College of

year ago. These cases are widely viewed, and recently I was invited to return to Mount Sinai to participate in the 1-year anniversary procedure, to be performed by Drs. Samin Sharma and Annapoorna Kini. These high-volume operators often make complex cases look easy, given their expertise and the high-performance technology that is available to us. Indeed, many live cases

performed in training courses around the world look pretty routine. On this day, there was to be nothing routine. The selection of the patient was appropriate: a patient with significant angina

Spencer B. King III, MD, MACC

Editor-in-Chief, *JACC: Cardiovascular Interventions*

Percutaneous LV Assist Devices

IABP

PTVA: TandemHeart

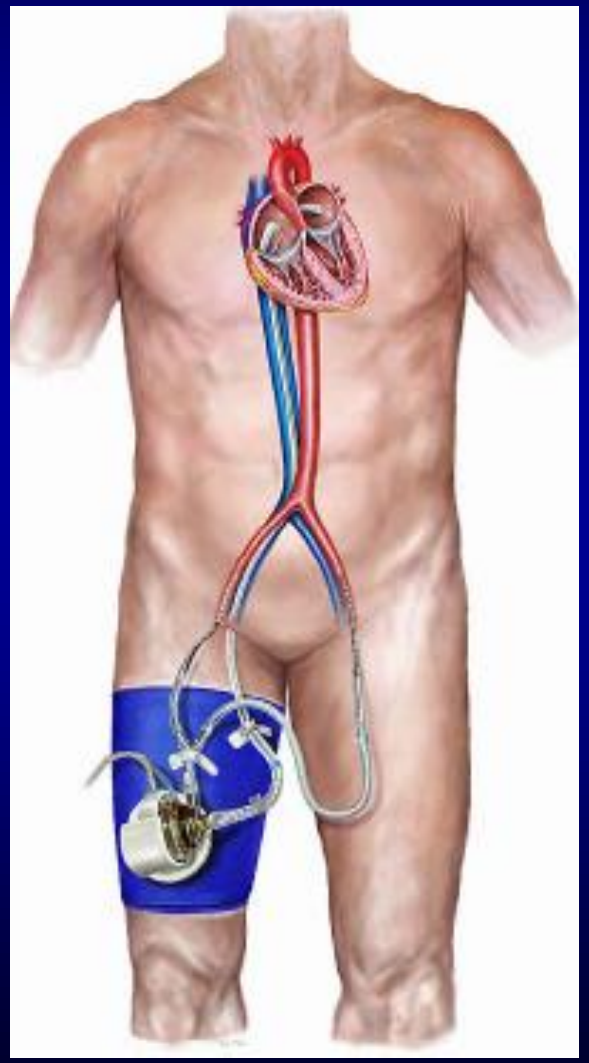

IMPELLA: Recovers 2.5

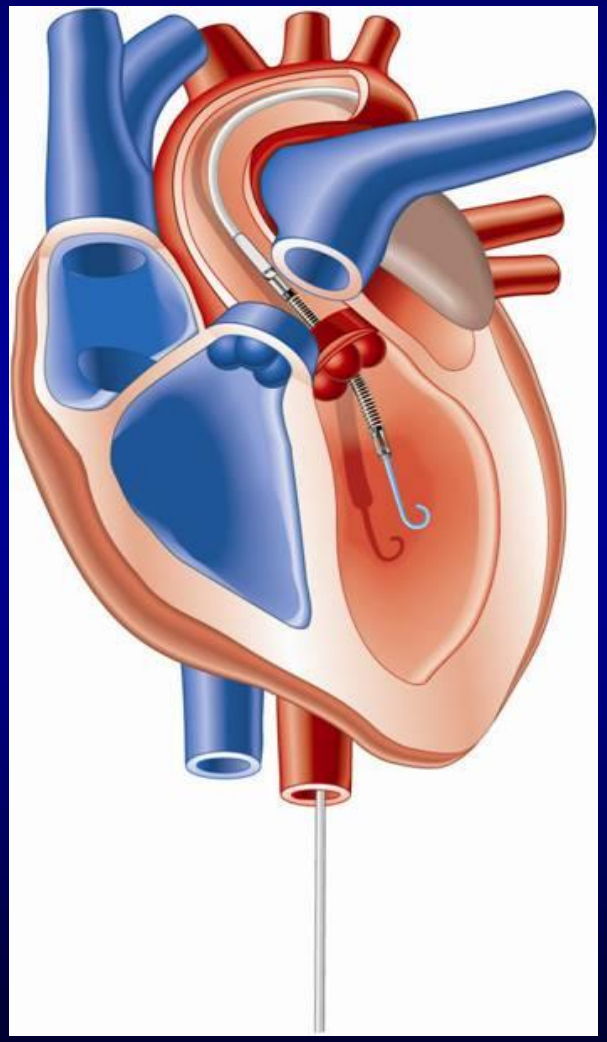

LV Support during High-Risk PCI: LVEF + Lesion Complexity

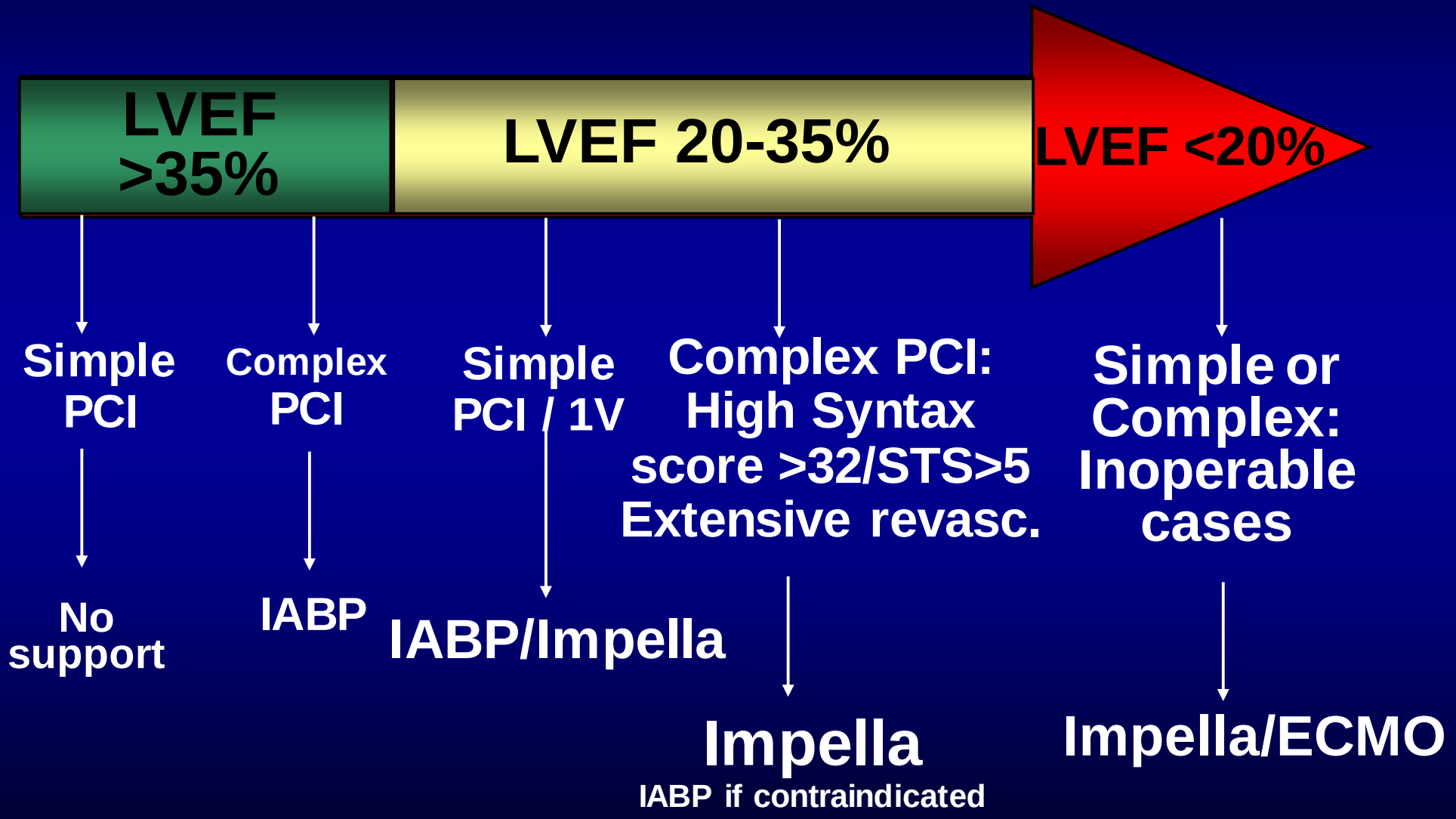

Portable Heart-Lung Support System (Cath Lab ECMO)

The CARDIOHELP System is the world's smallest portable heart-lung support system. It is ideal for use in critical care, cardiac catheterization laboratories, the operating room and trauma rooms. Furthermore, it is the perfect solution for safe and effective patient transport. As a result, there are now new opportunities and treatment possibilities for extracorporeal circulation for cardiac and or pulmonary support

Case #2 : 81yrs M

Presentation: Presents with progressive angina on exertion

Past Hx: HTN, HLD, CVA, Prior MI, Aspirin sensitive

Medications: ASA, Carvedilol, Lisinopril, Plavix

Cath: 3 V CAD ; pRCA 80%, RPDA- Total occlusion, Left Main-90%, Prox LAD- 80-90-%, Mid LAD- Subtotal Occlusion, D2-70-80%, OM1-90-95%, OM2 80-90%, EF= 30%. s/p Rota DES PCI of RCA/RPDA

Plan: High risk PCI of Left main and LAD

Left ventriculography

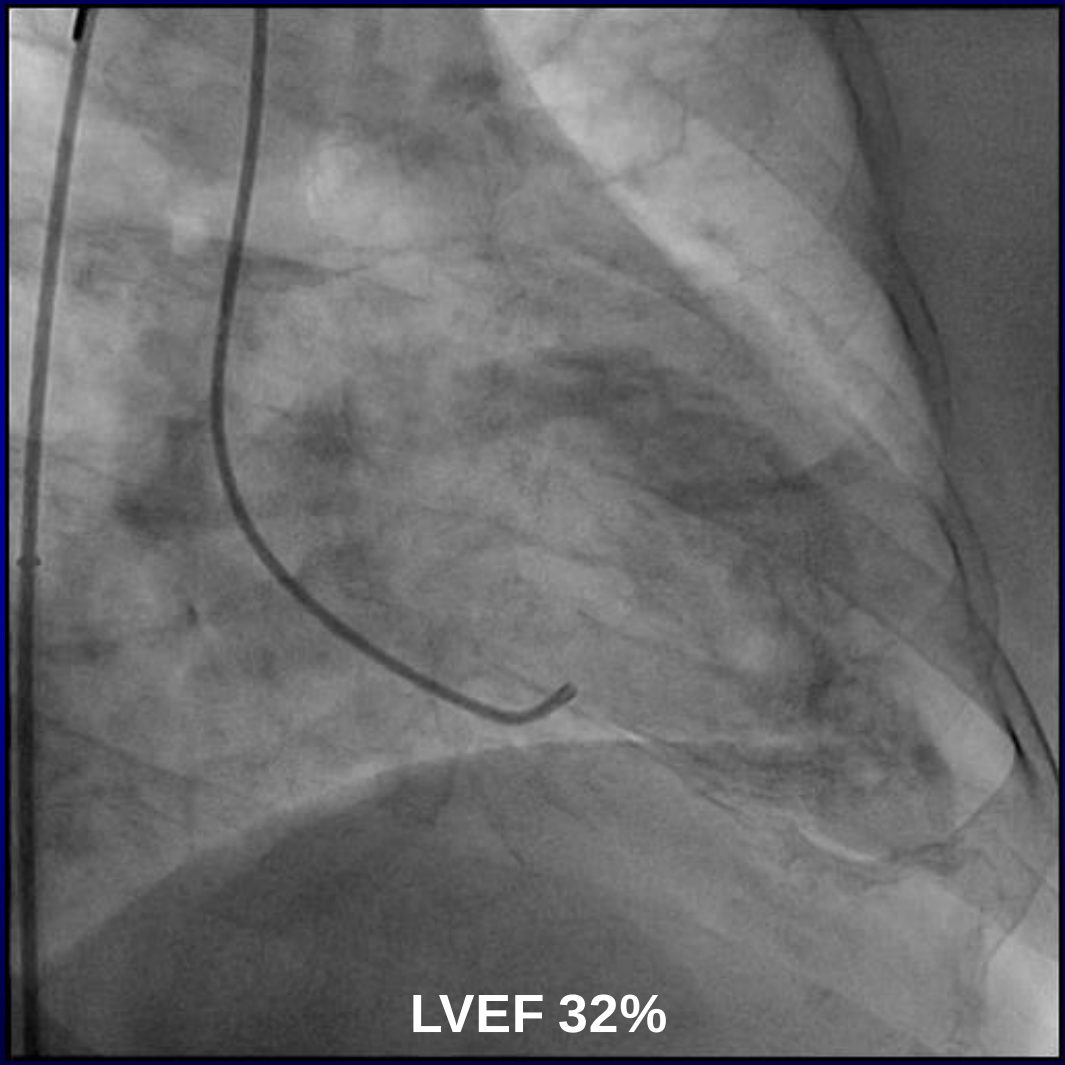

Initial angiography

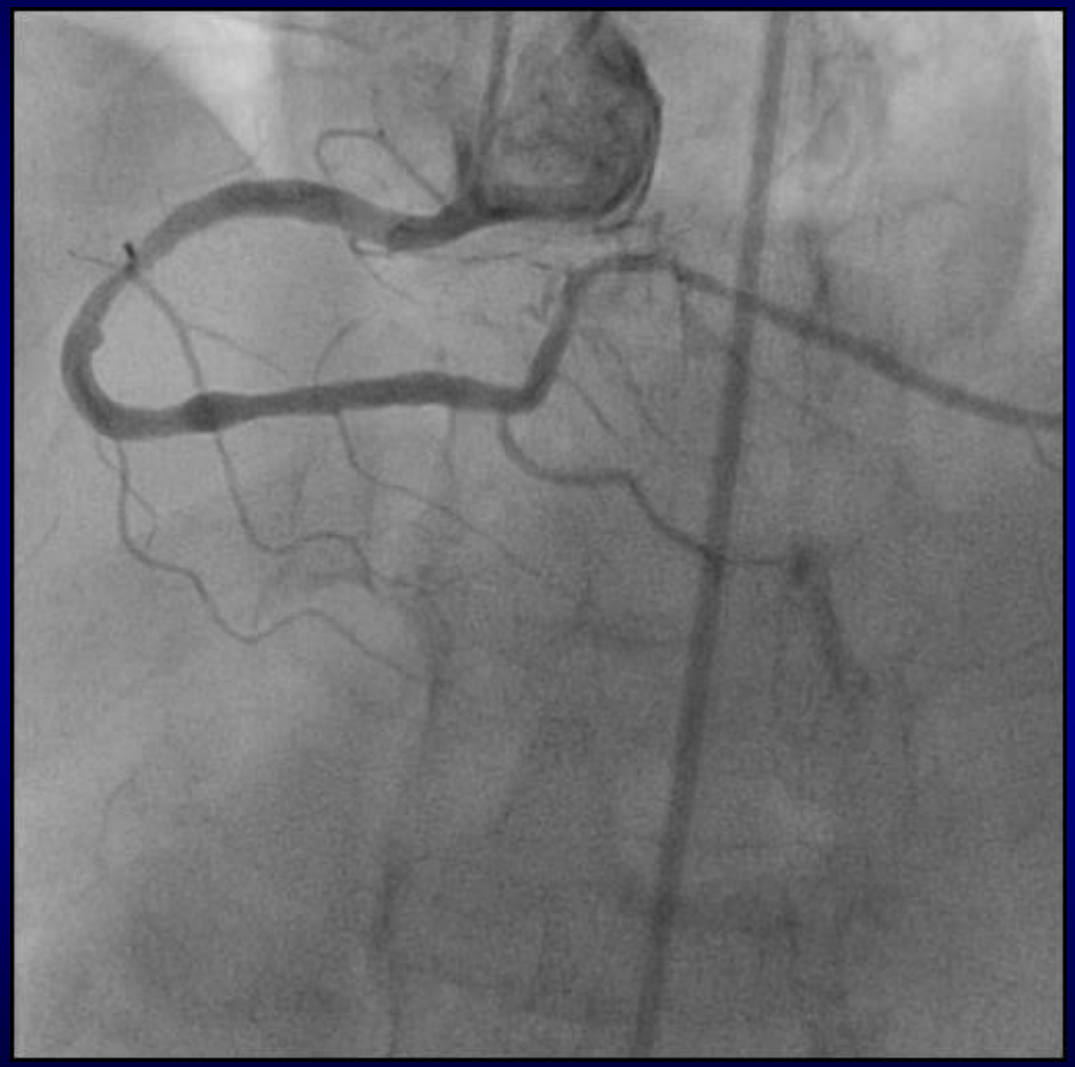

RCA

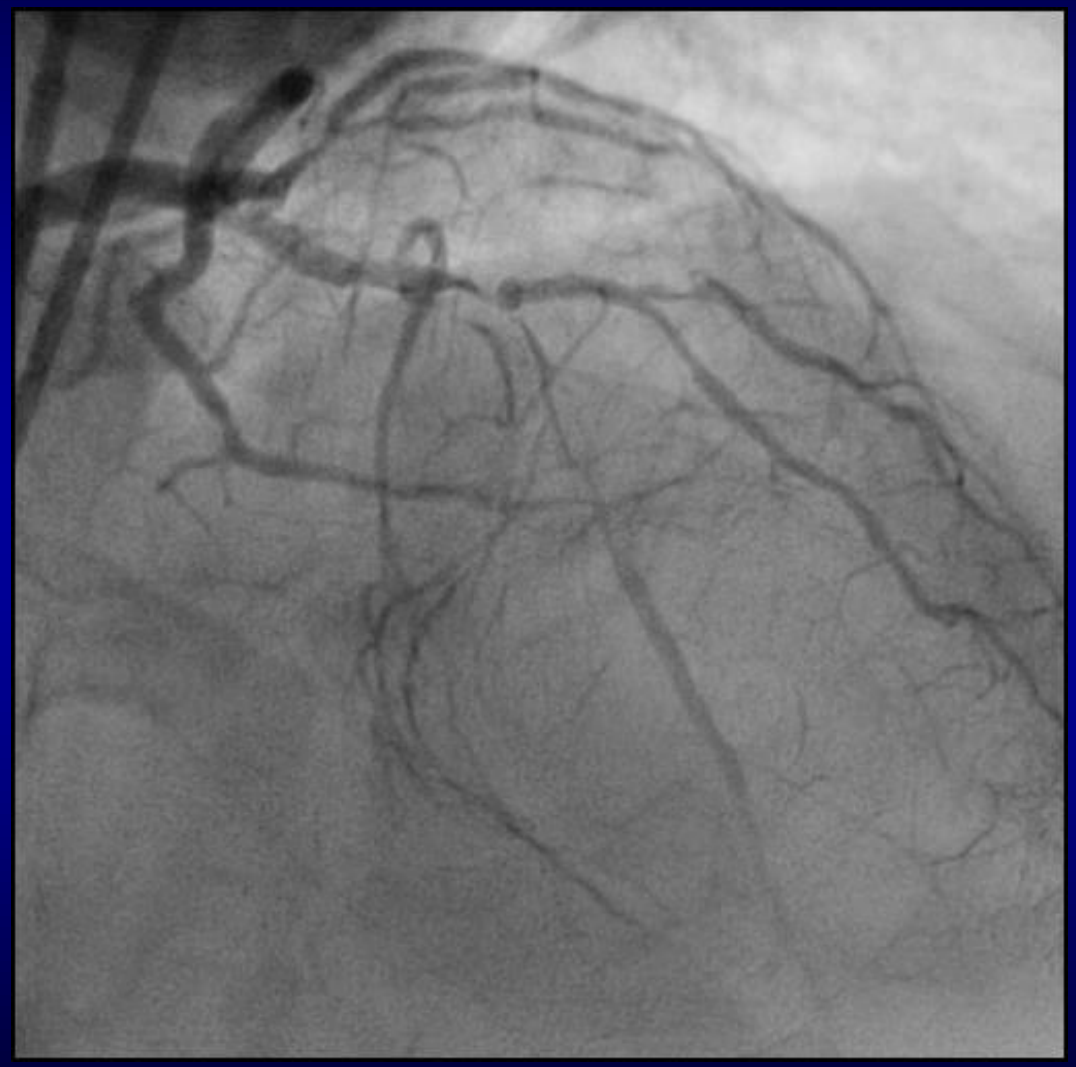

LCA

Left coronary angiography

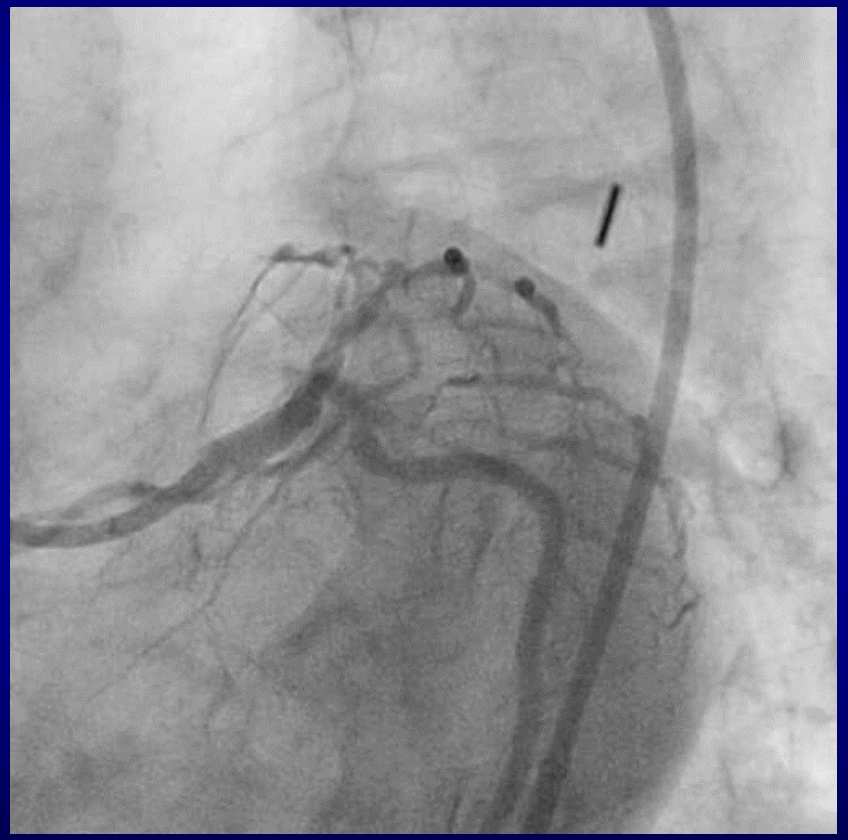

Spider view

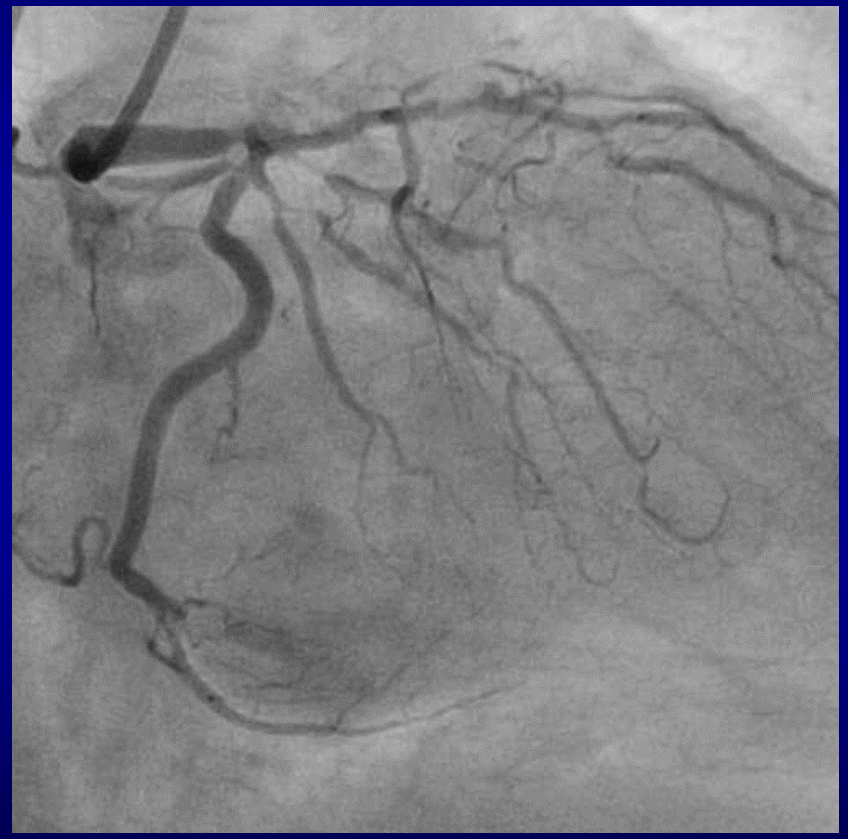

Caudal view

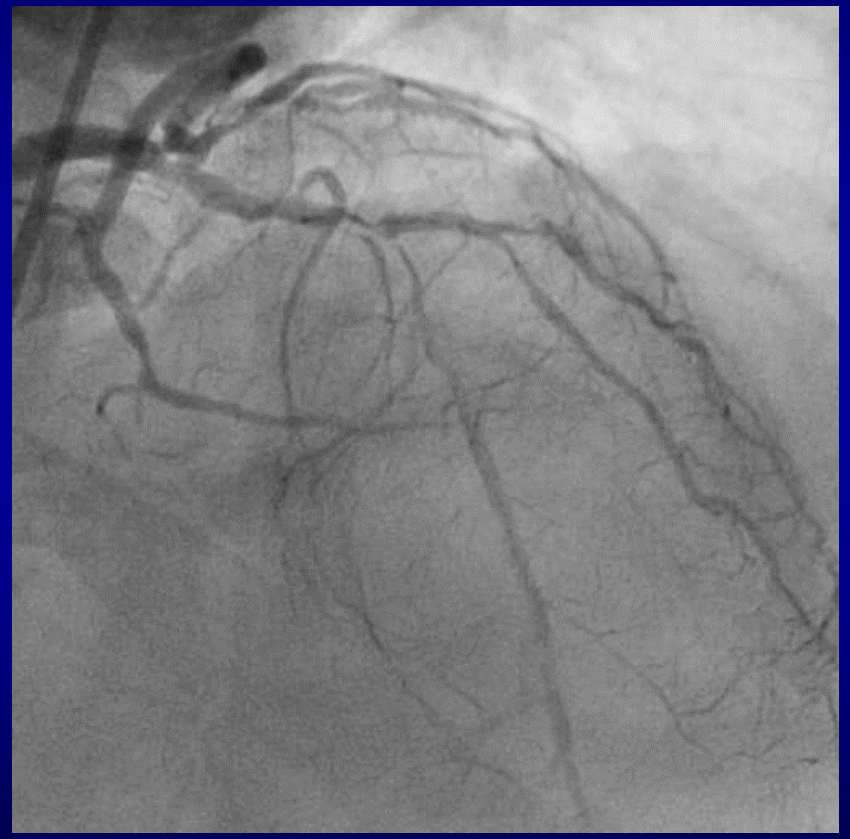

Cranial view

RA to proximal-mid LAD

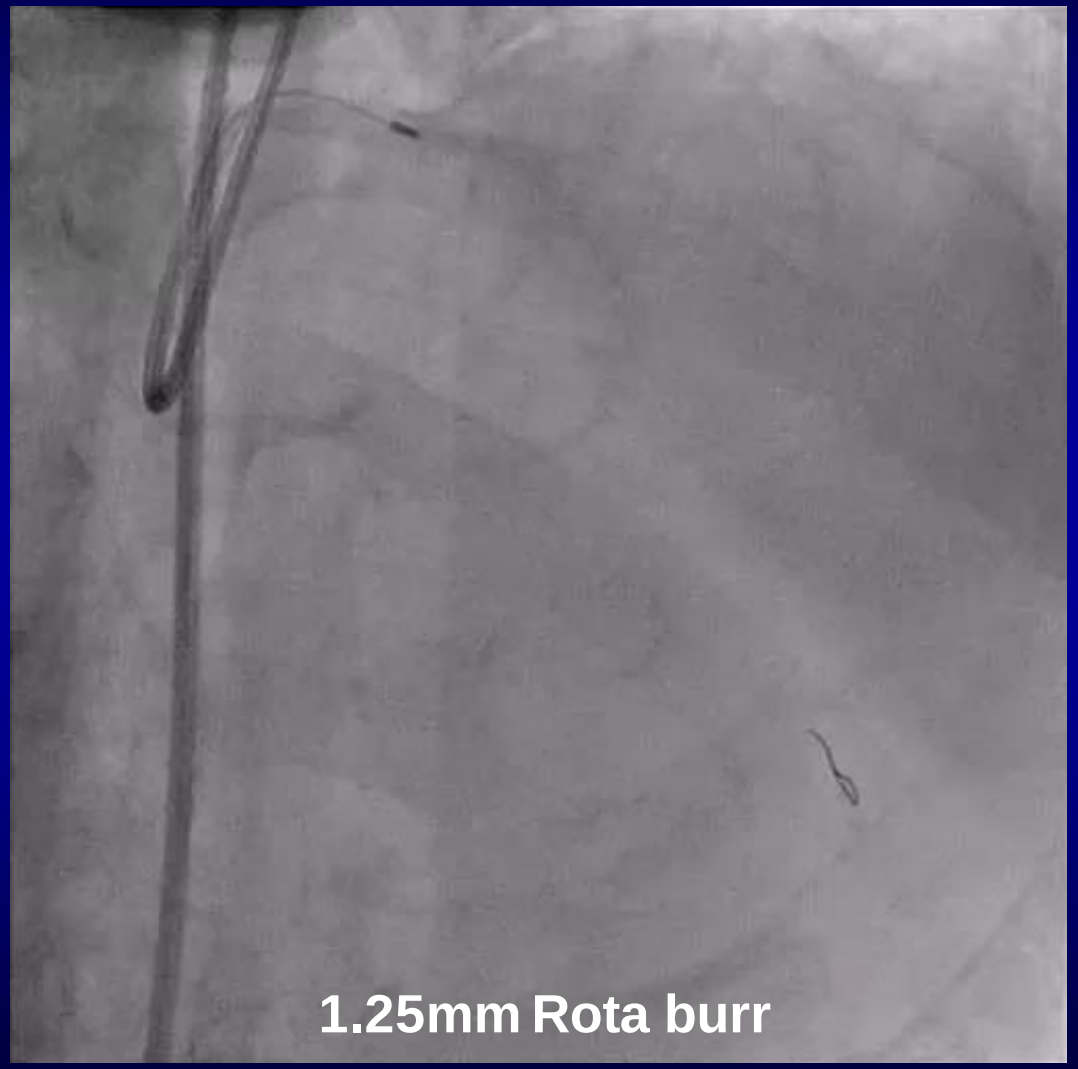

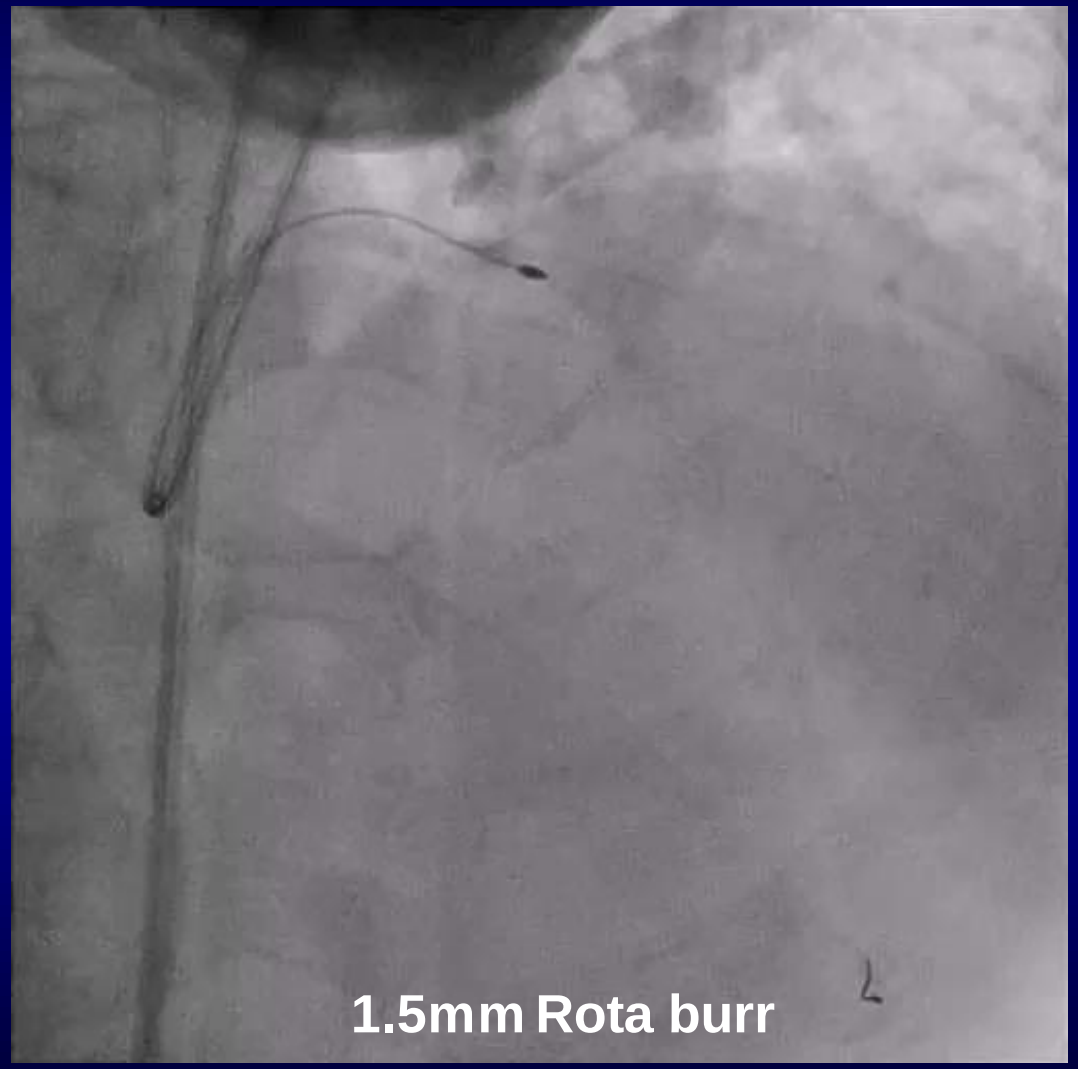

After RA

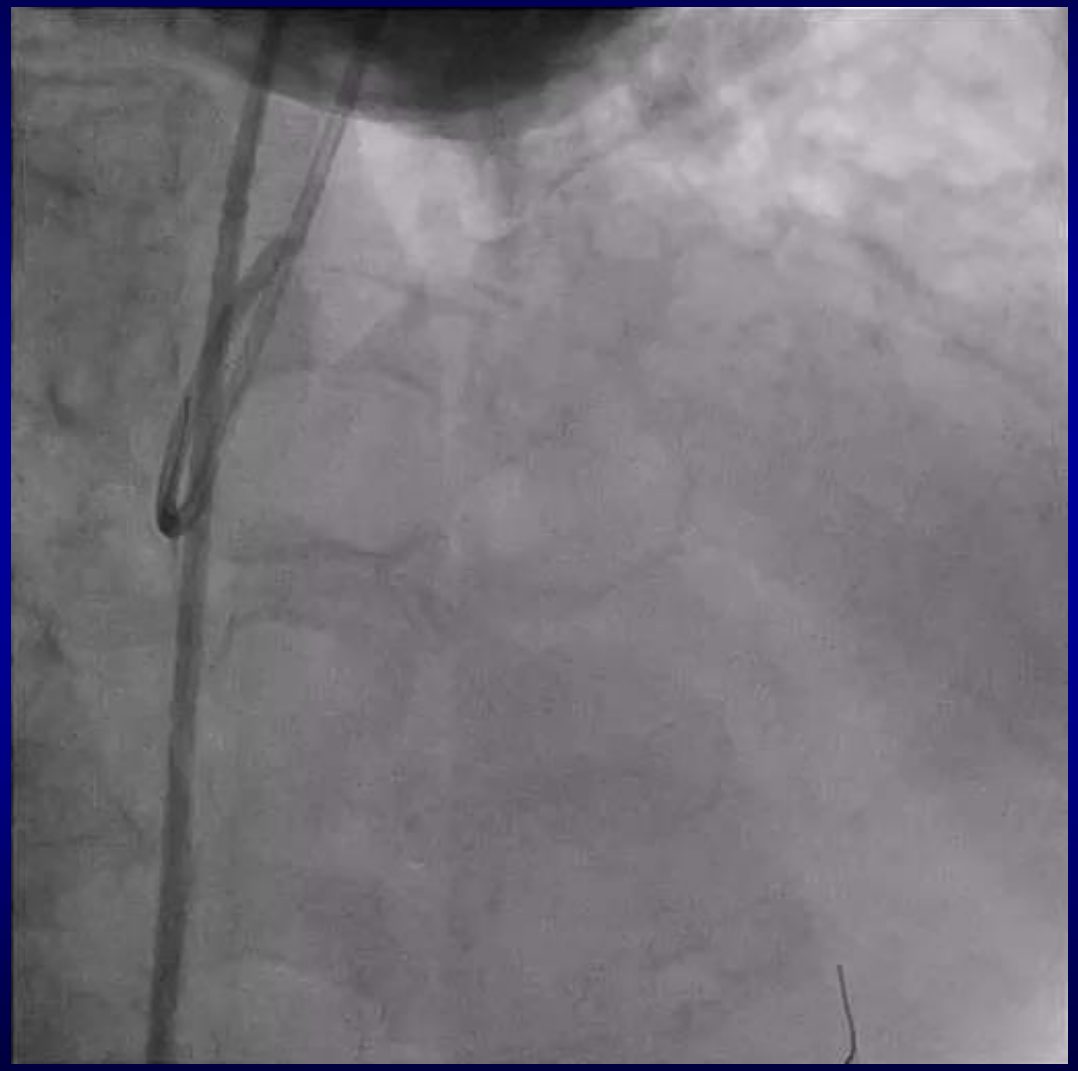

PTCA of mid-LAD

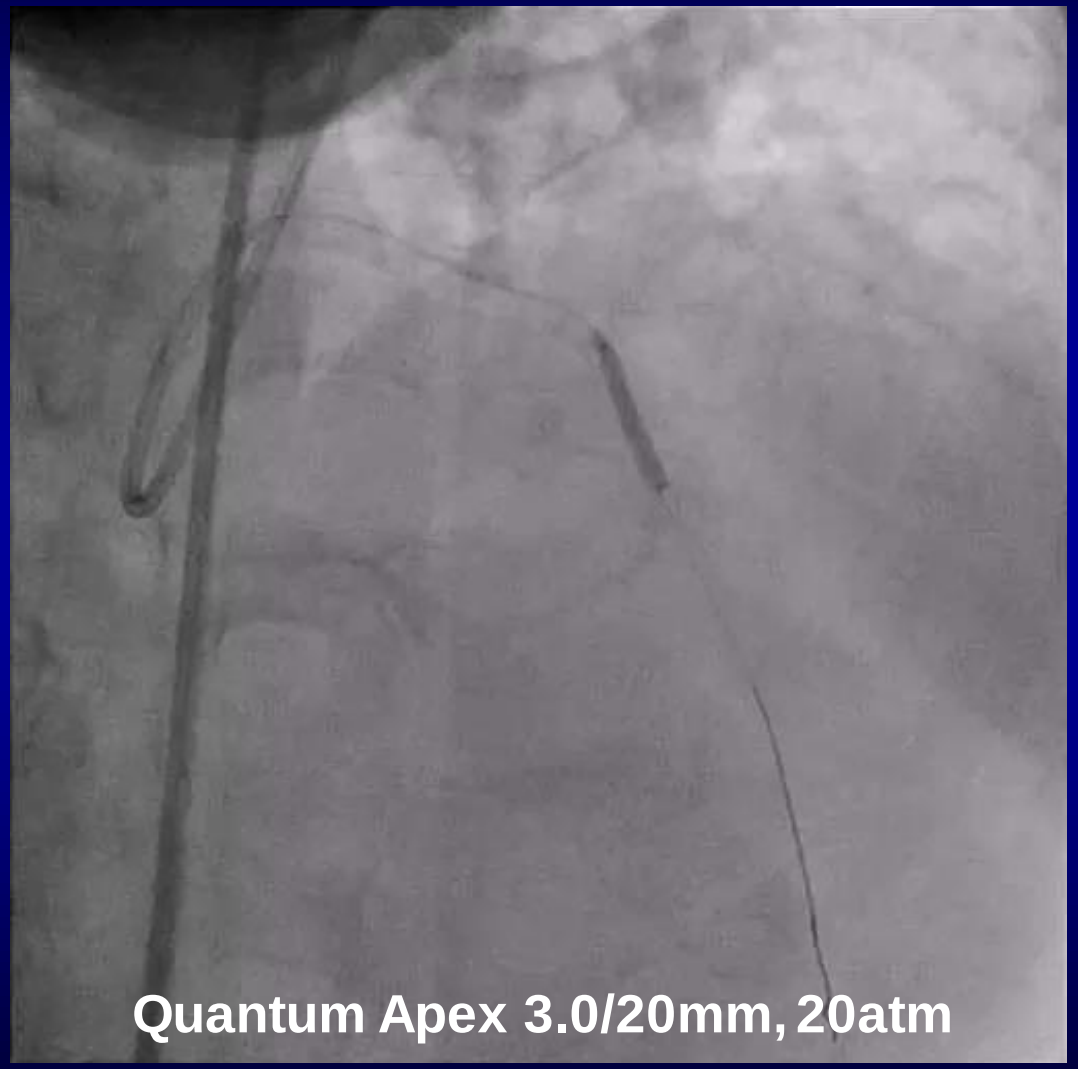

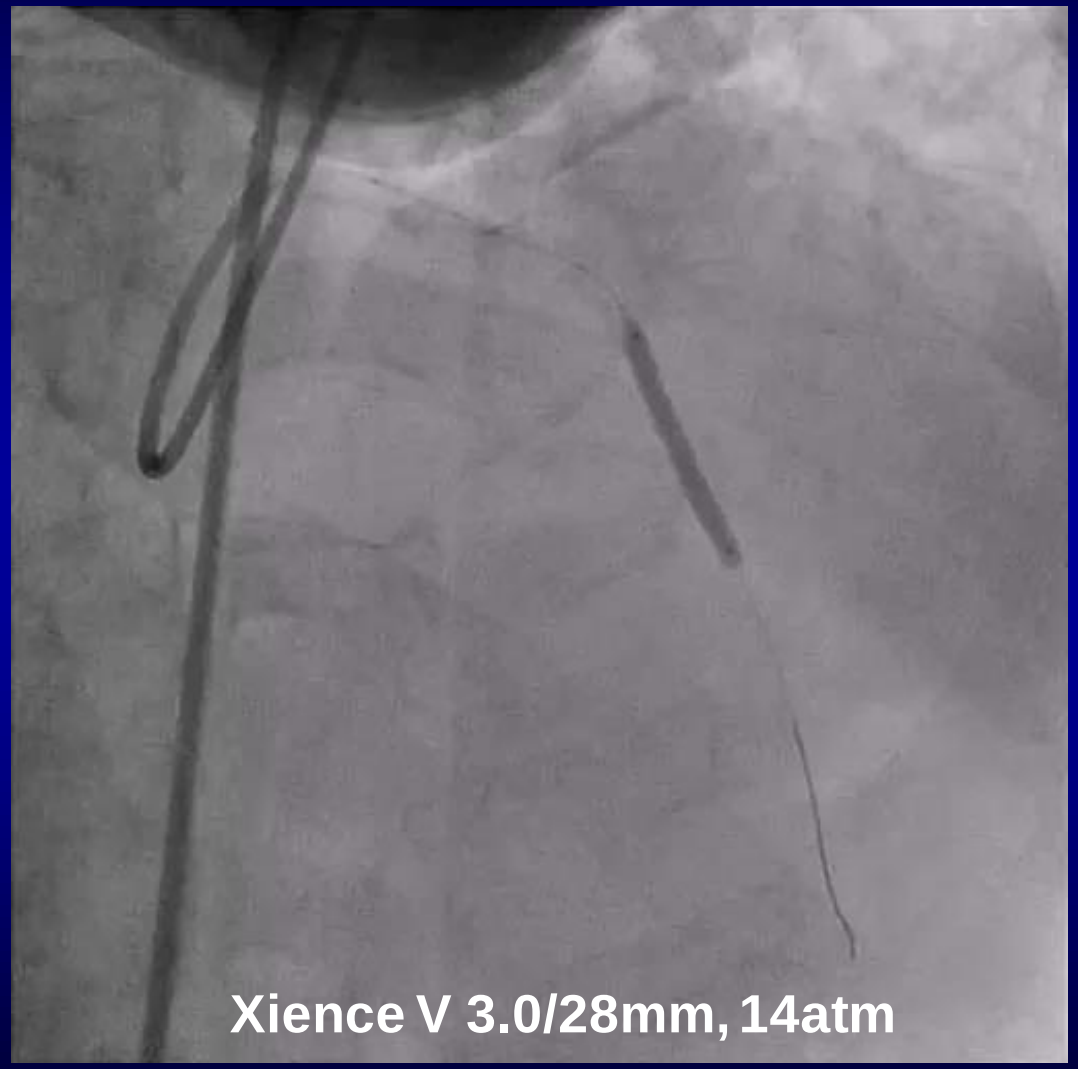

After mid-LAD stent

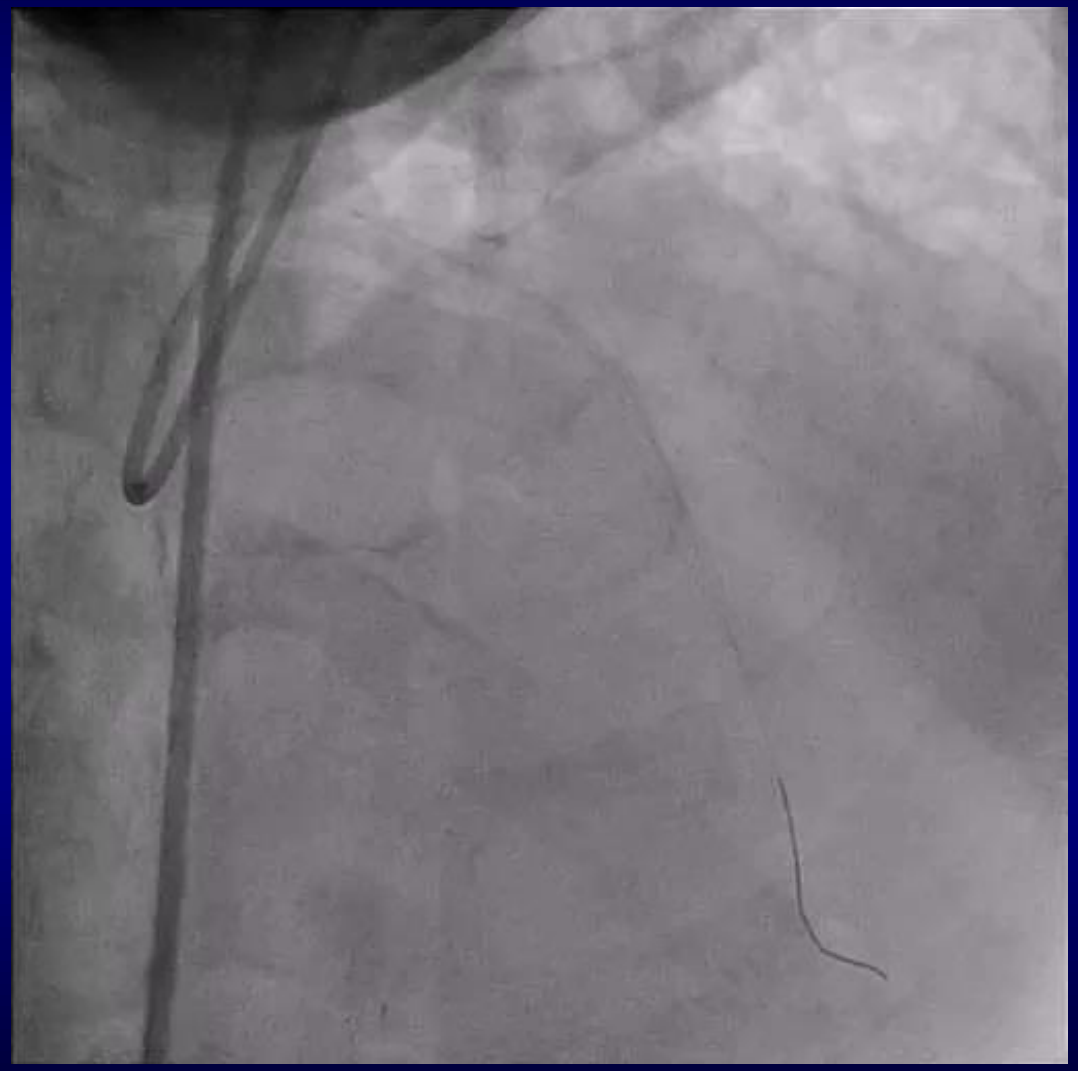

PCI to proximal-LAD/D1

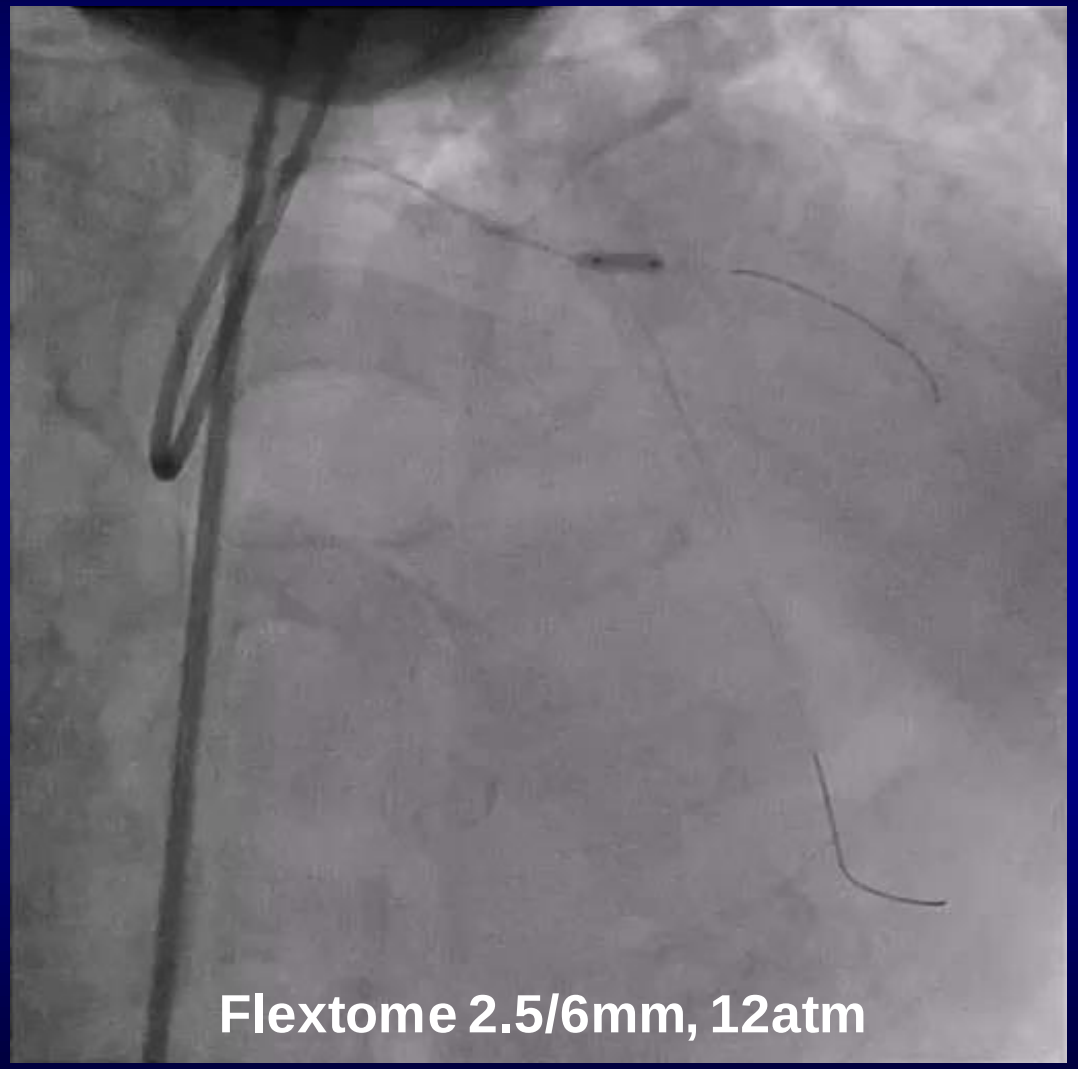

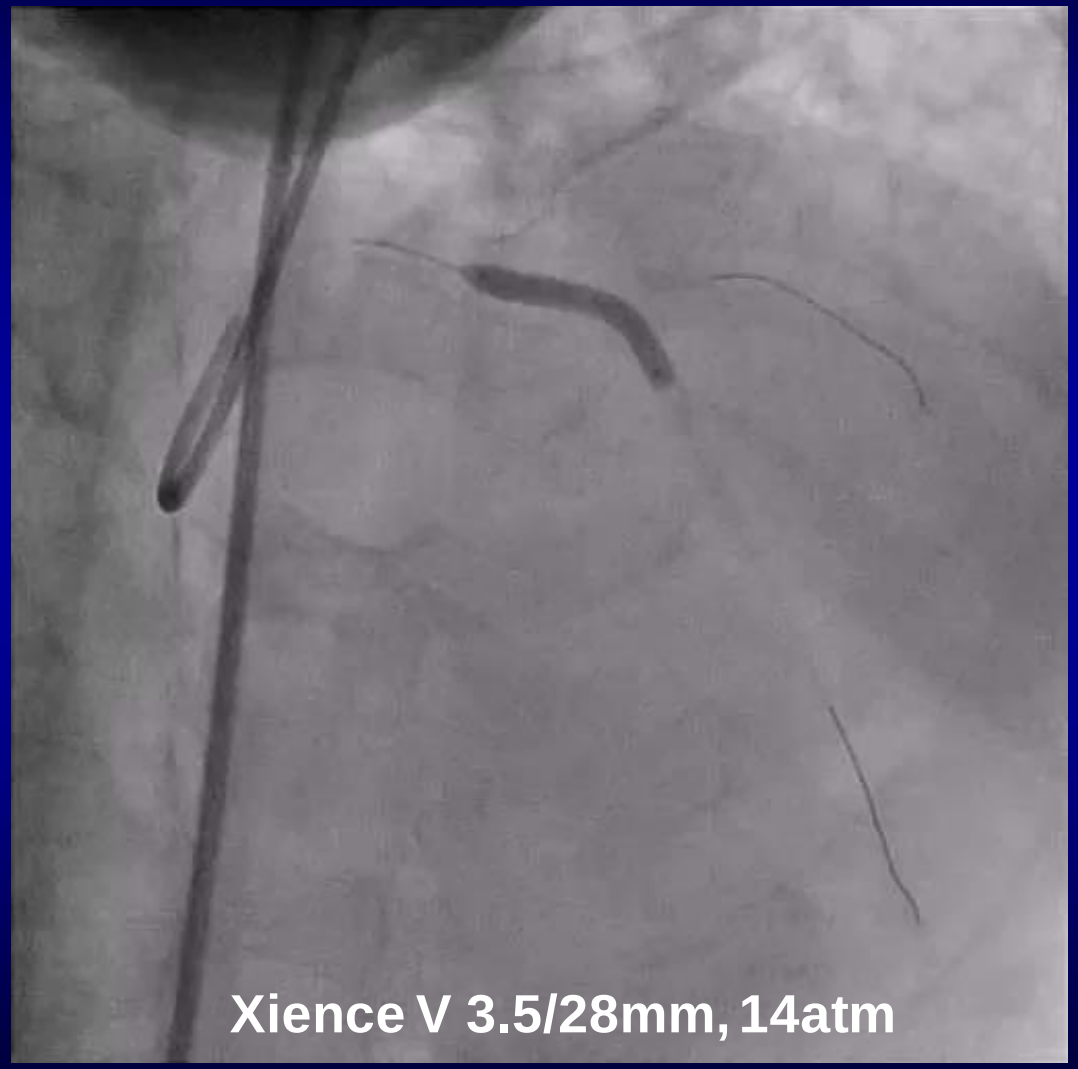

After prox-LAD stent

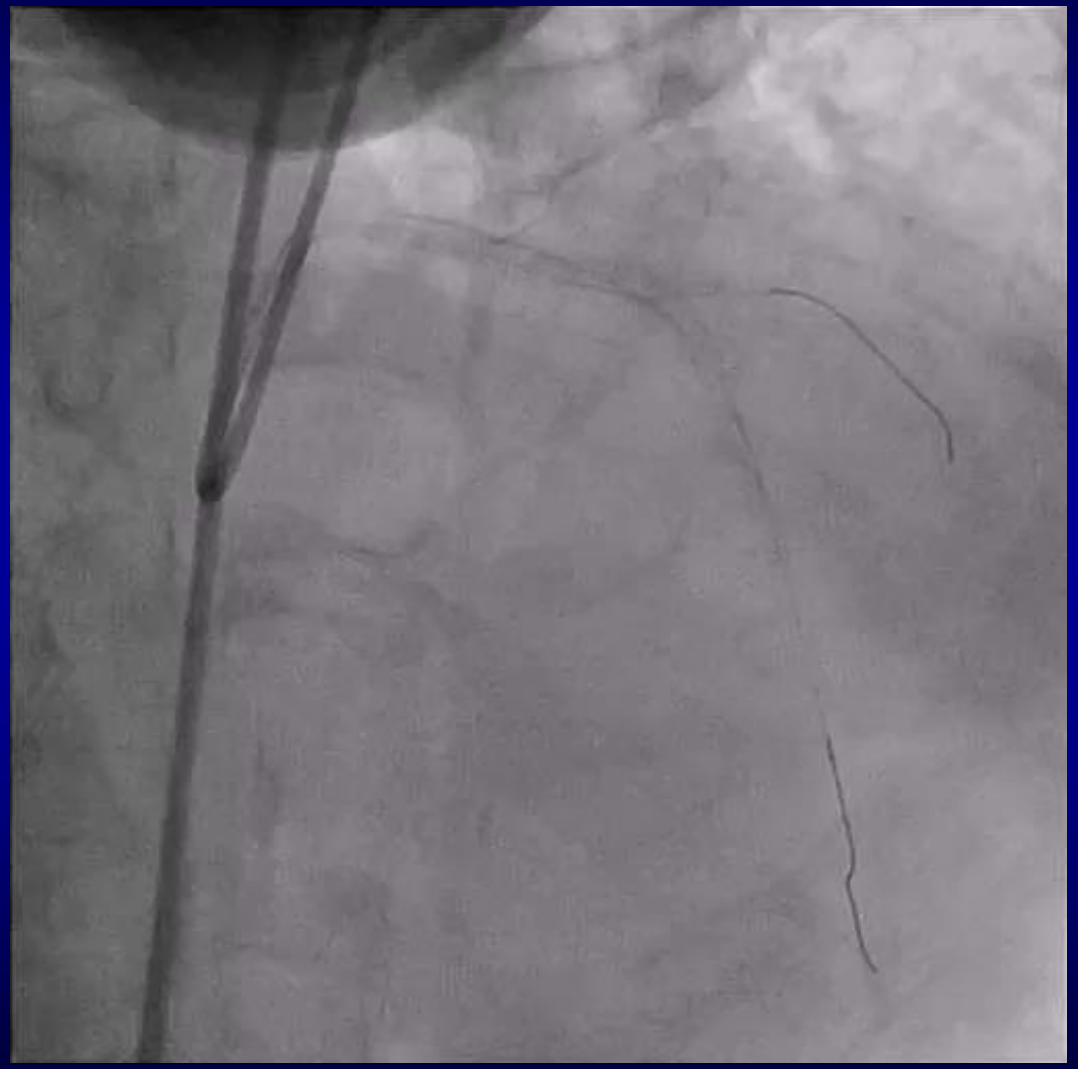

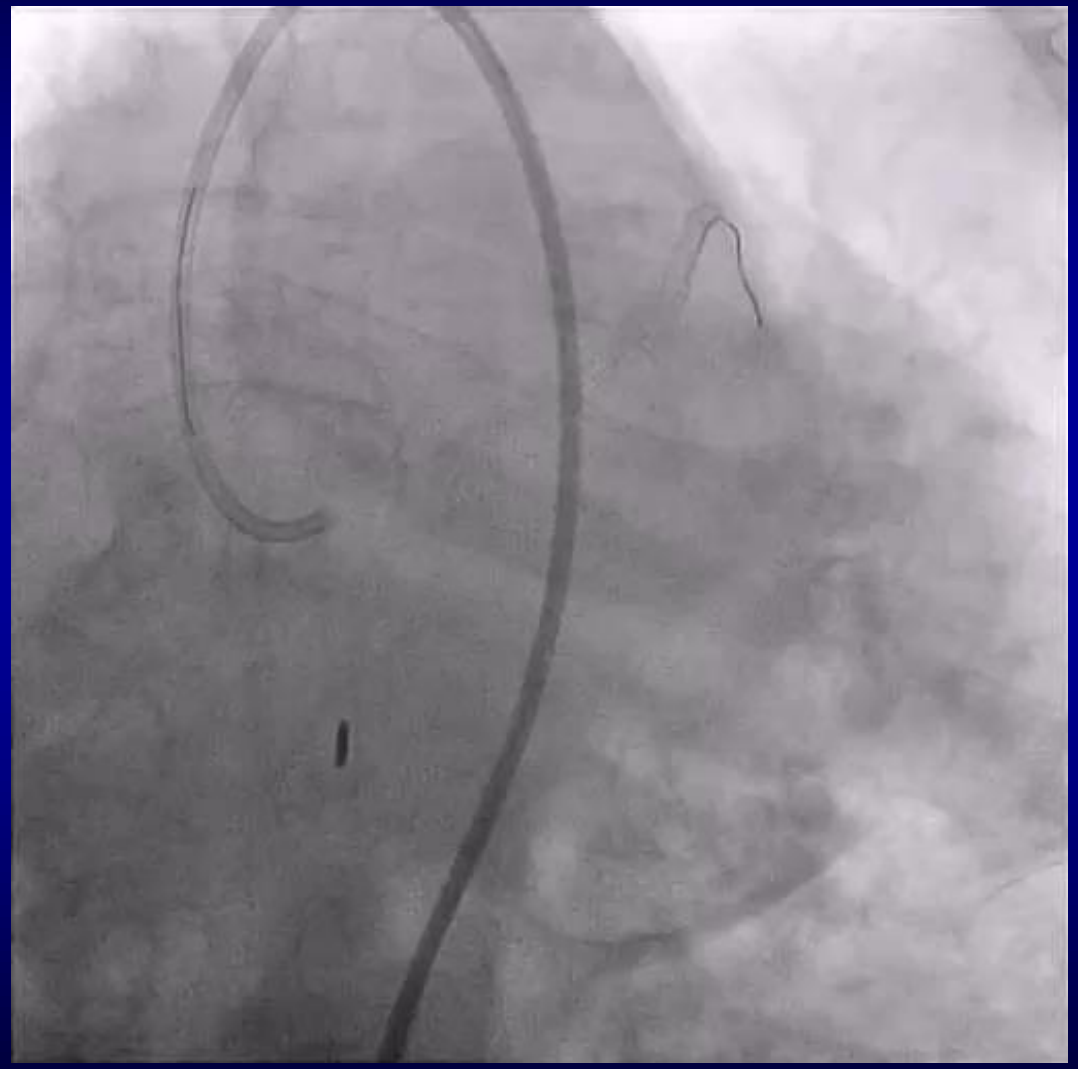

PCI to LM-LAD

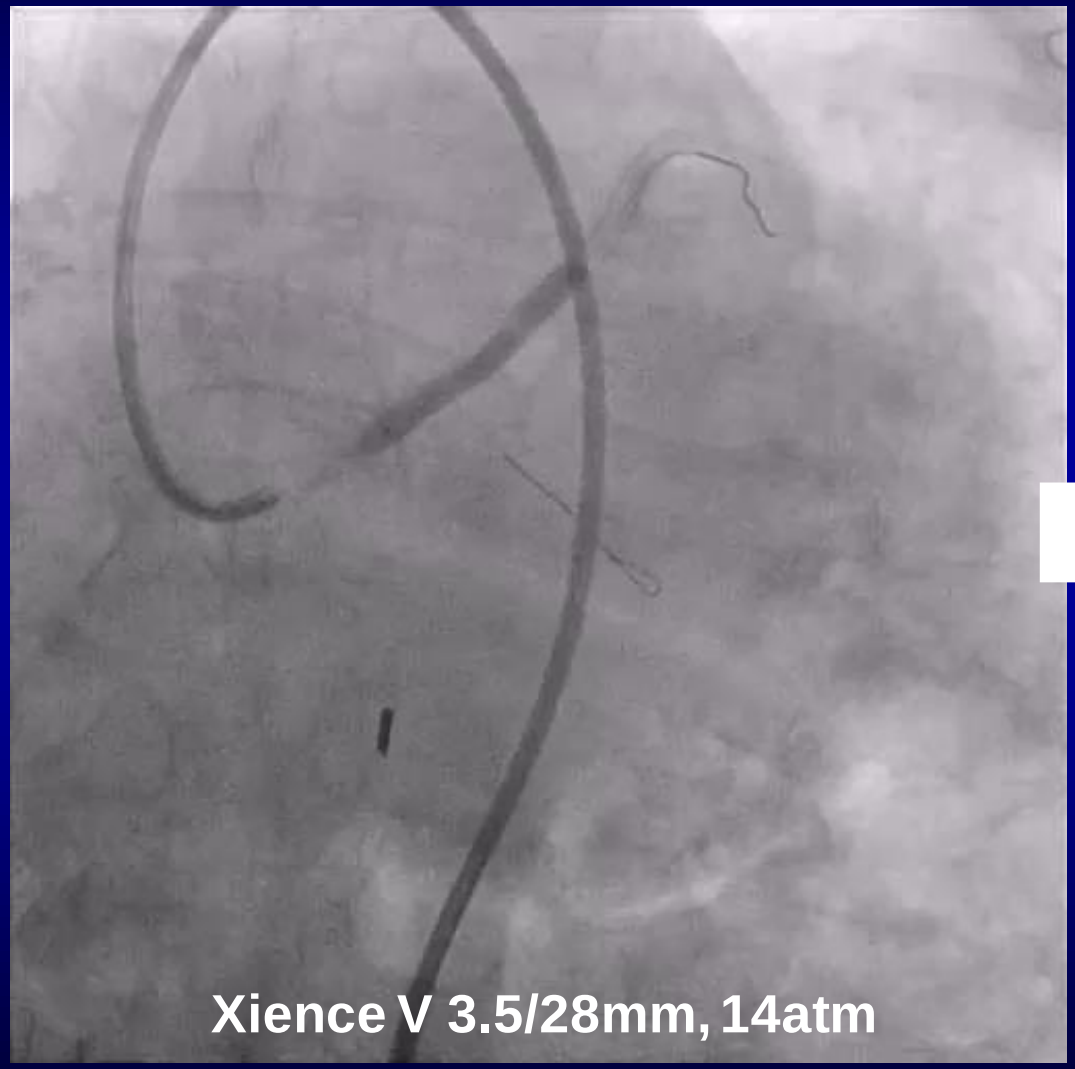

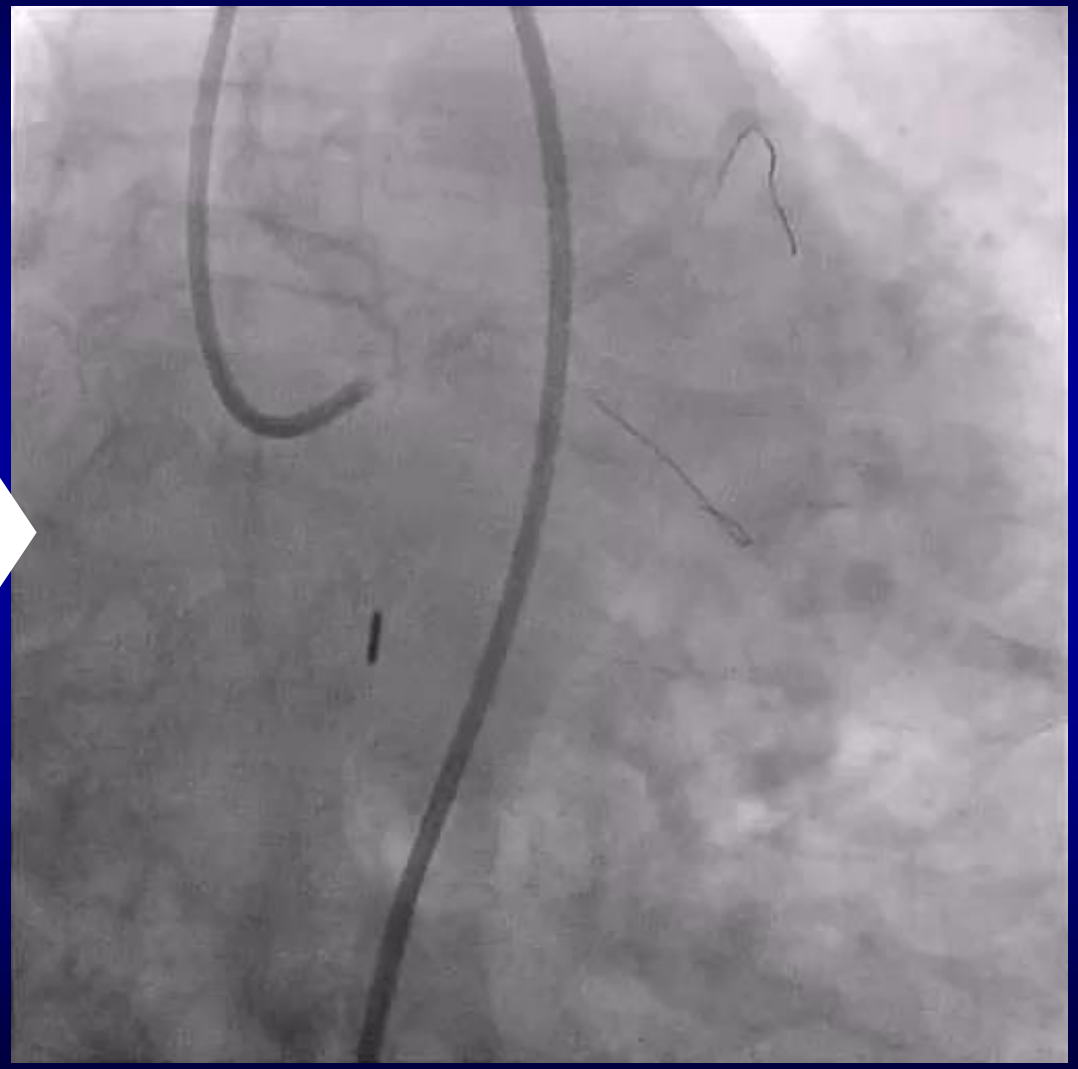

Post dilation to LM stent

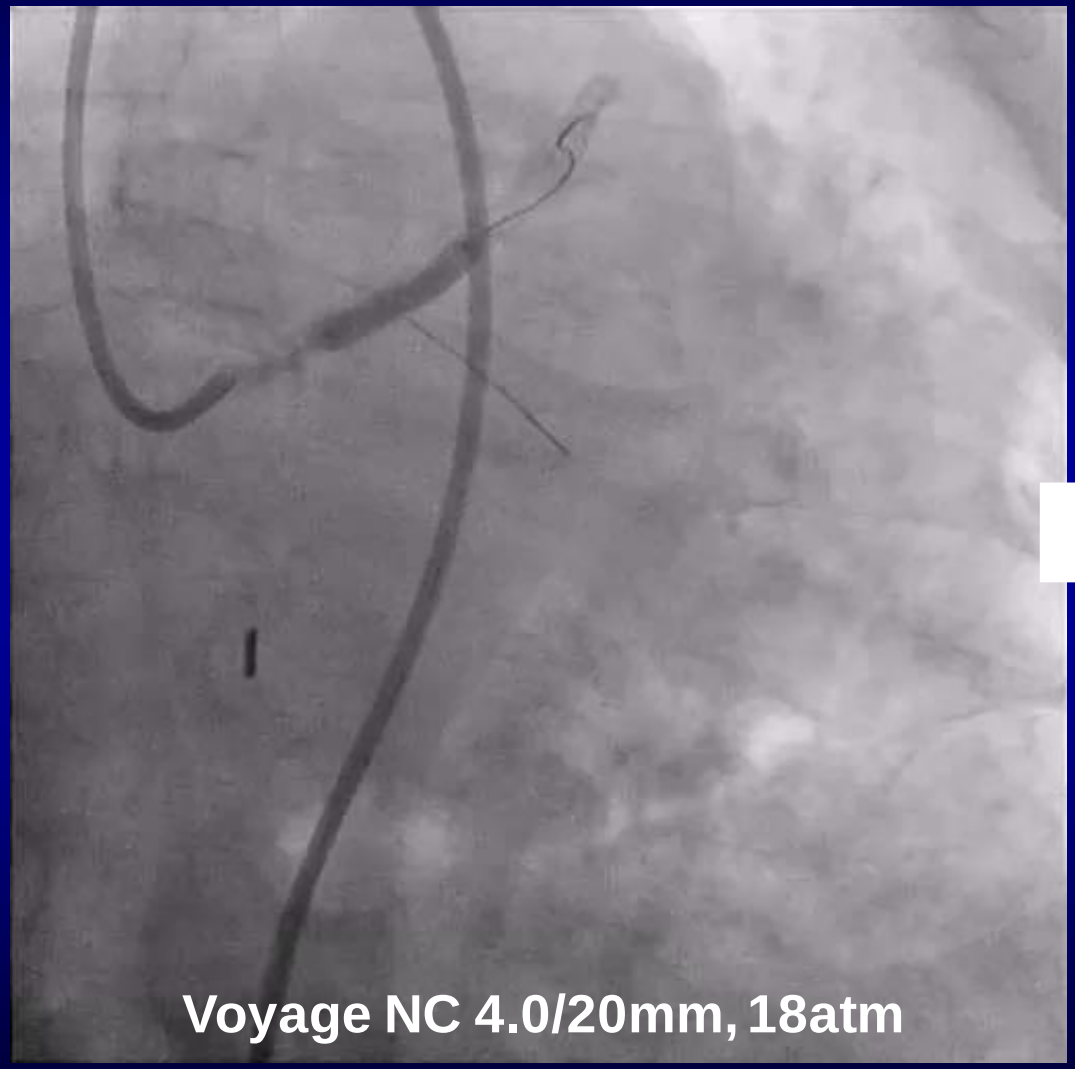

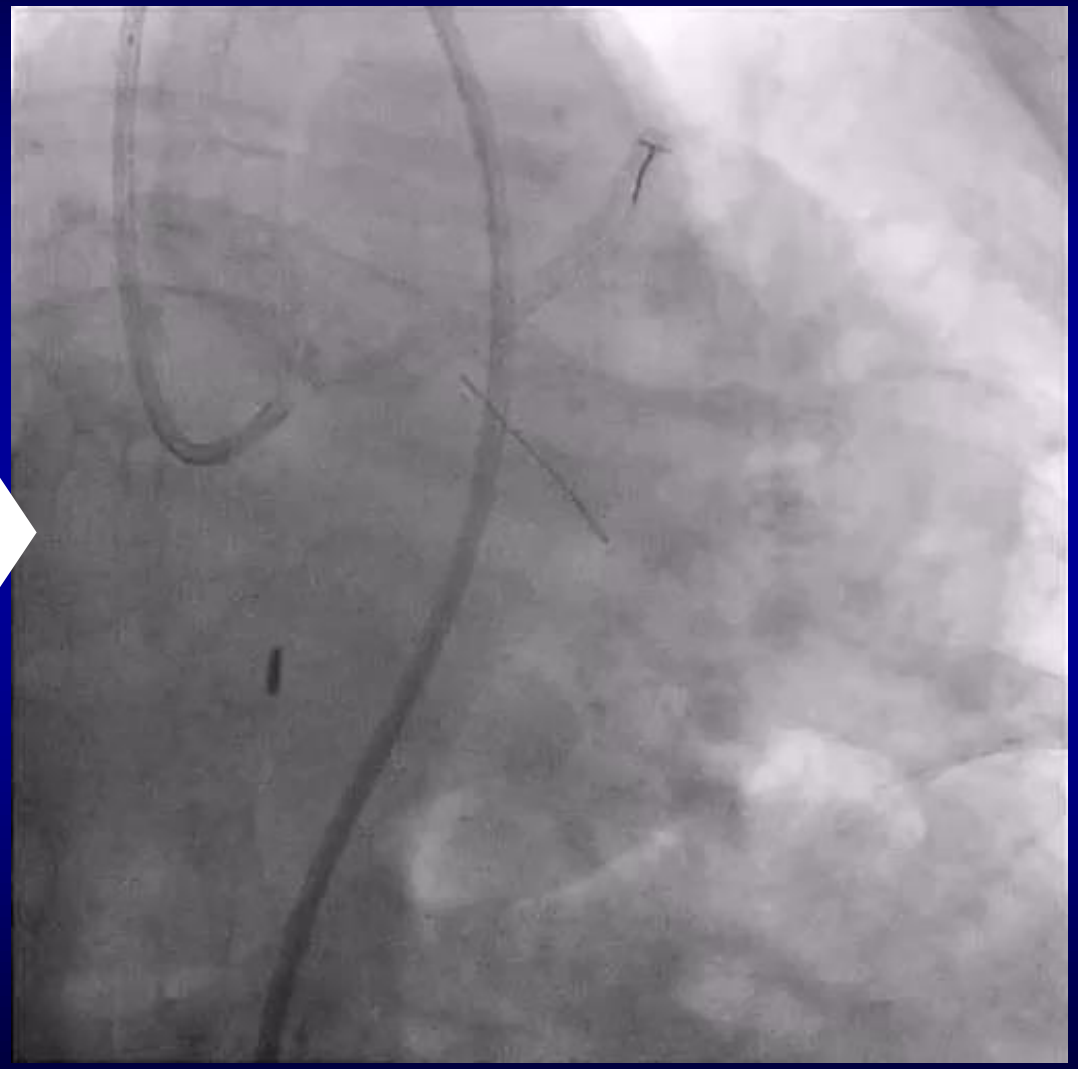

Post dilation again

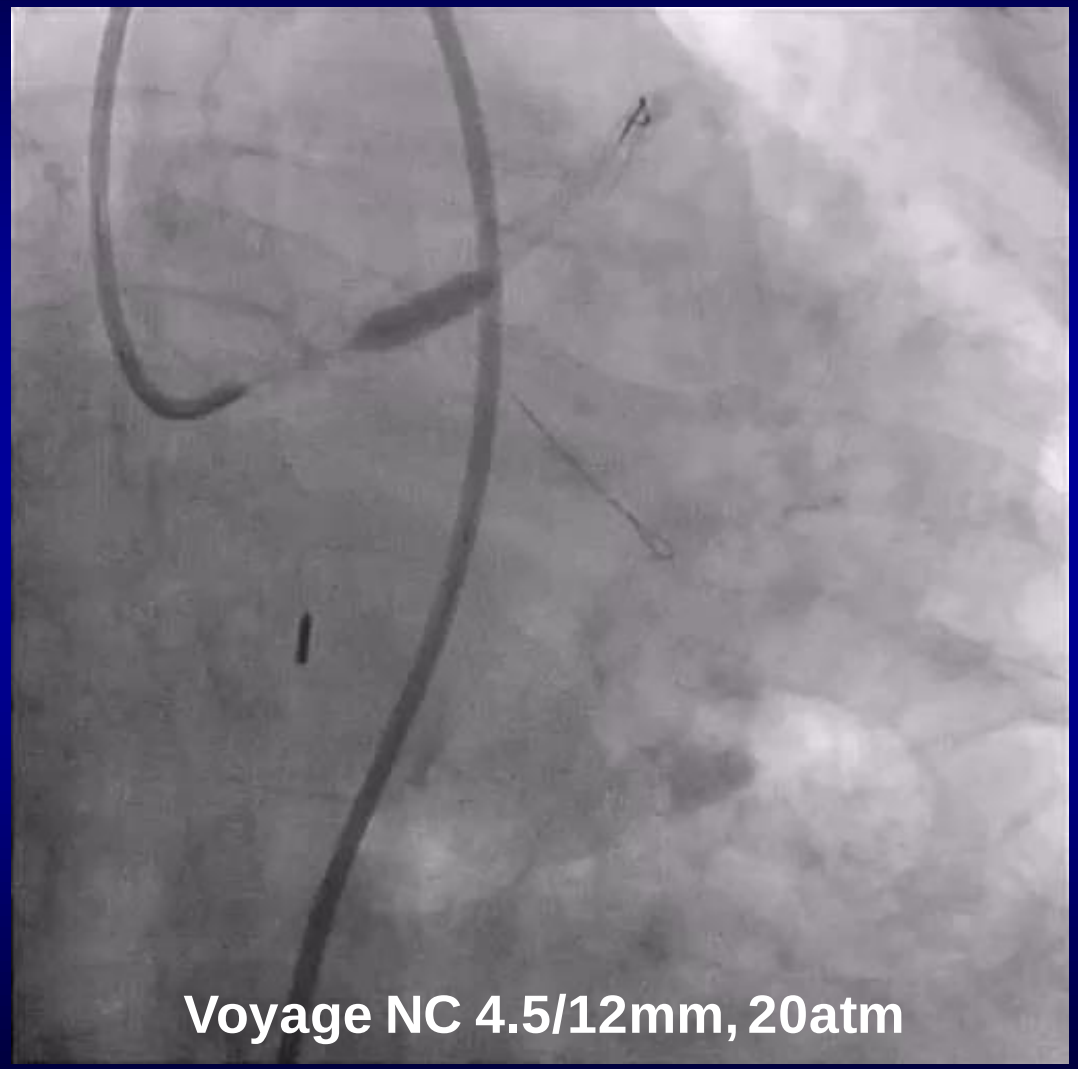

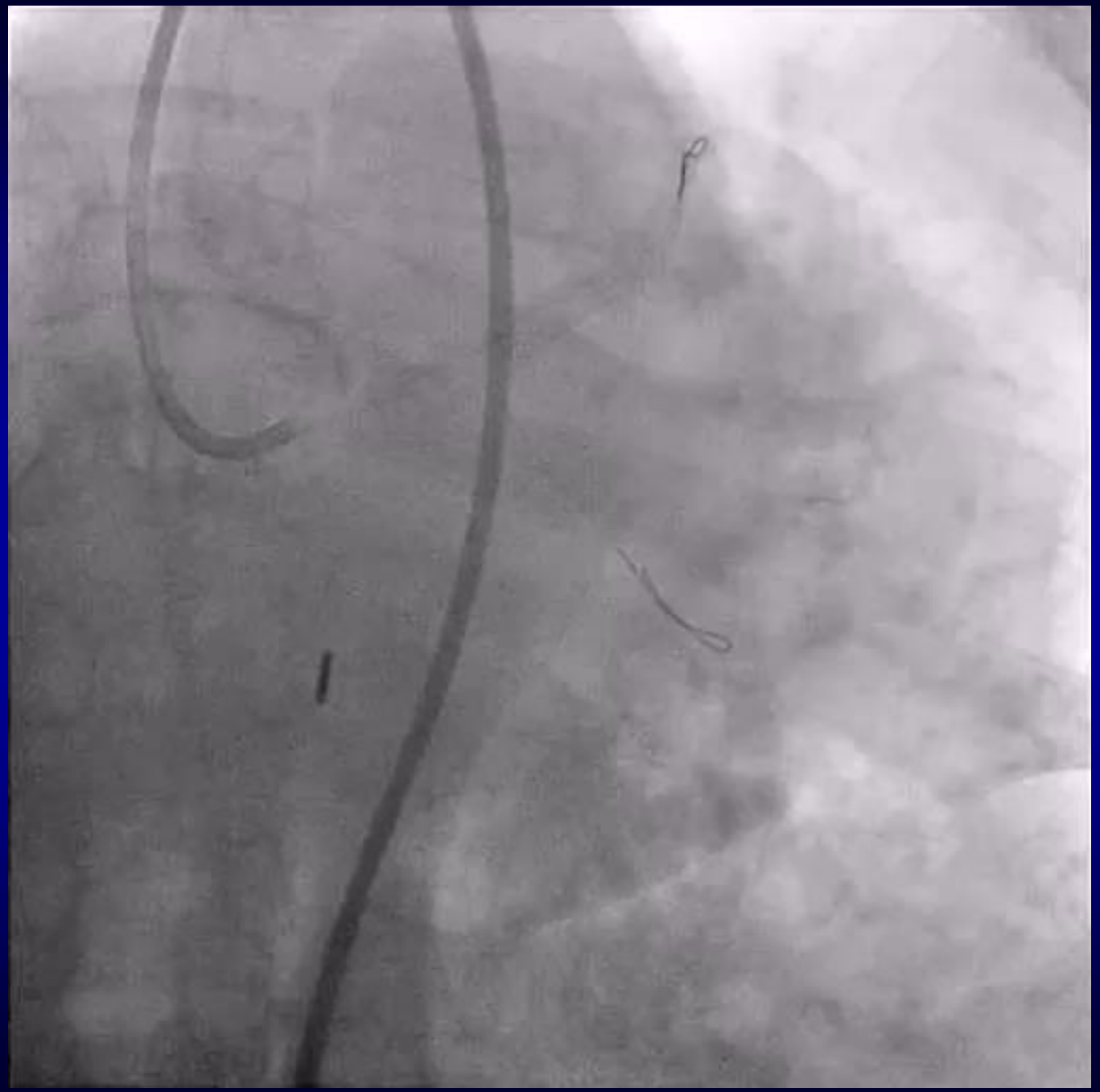

Balloon tamponade

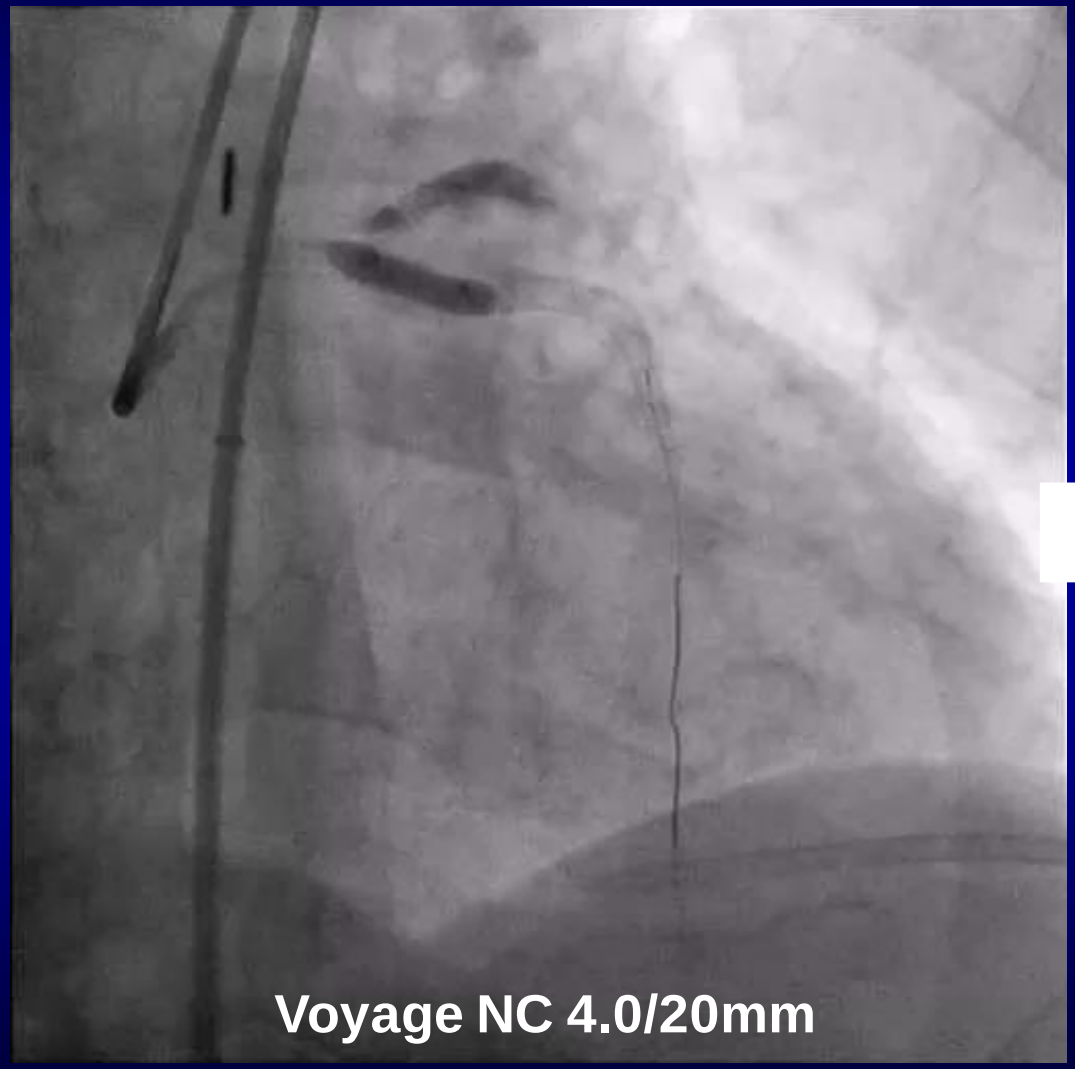

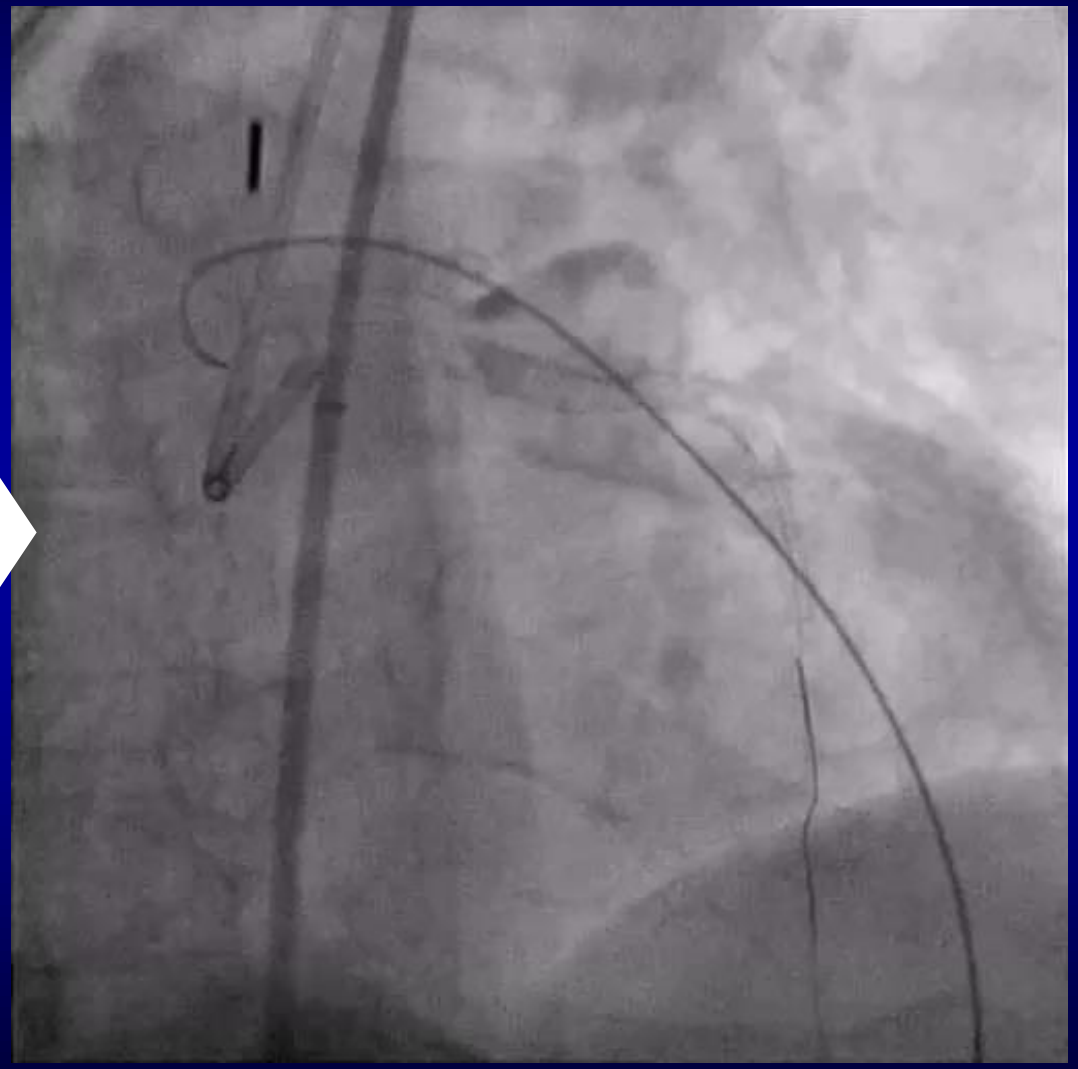

Covered stent

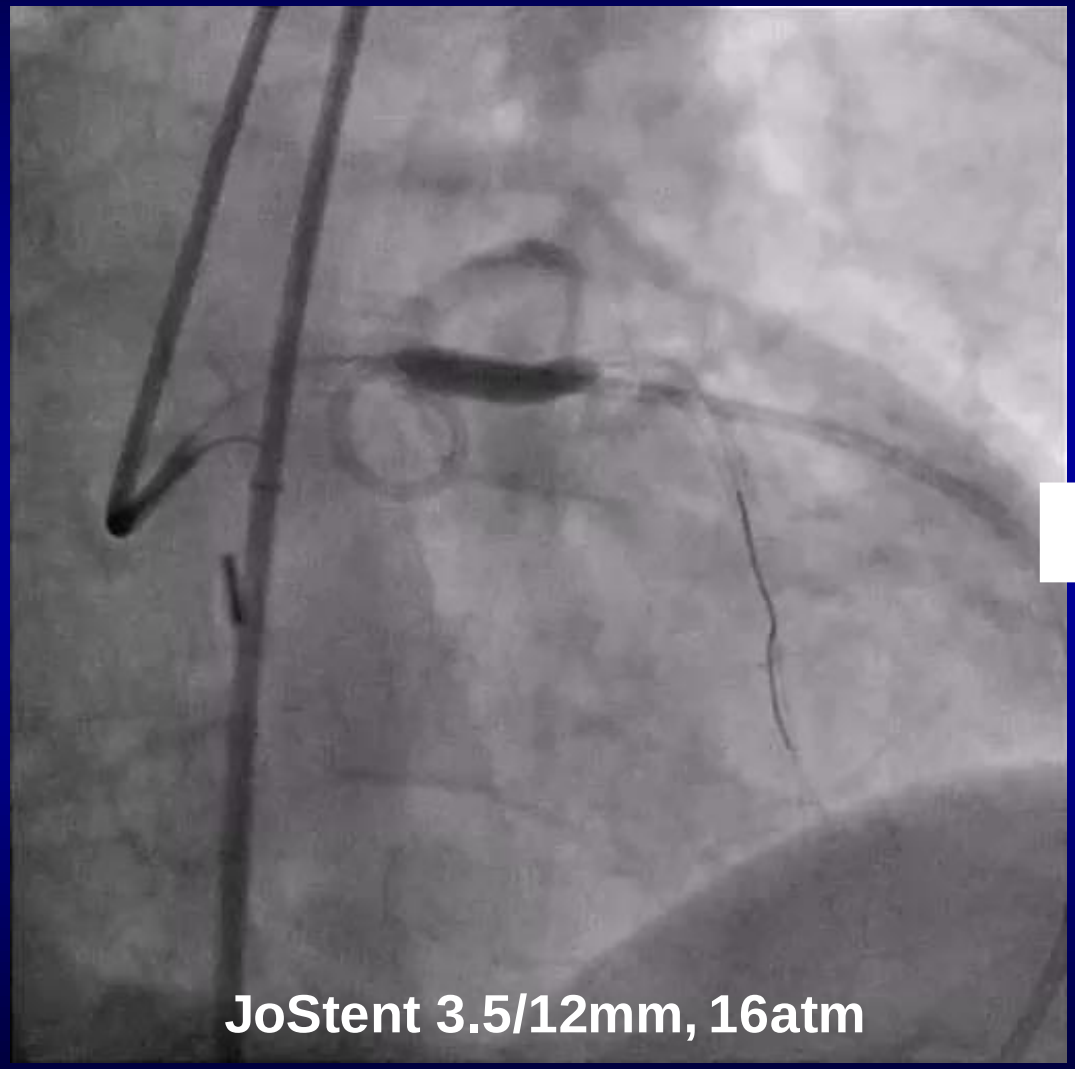

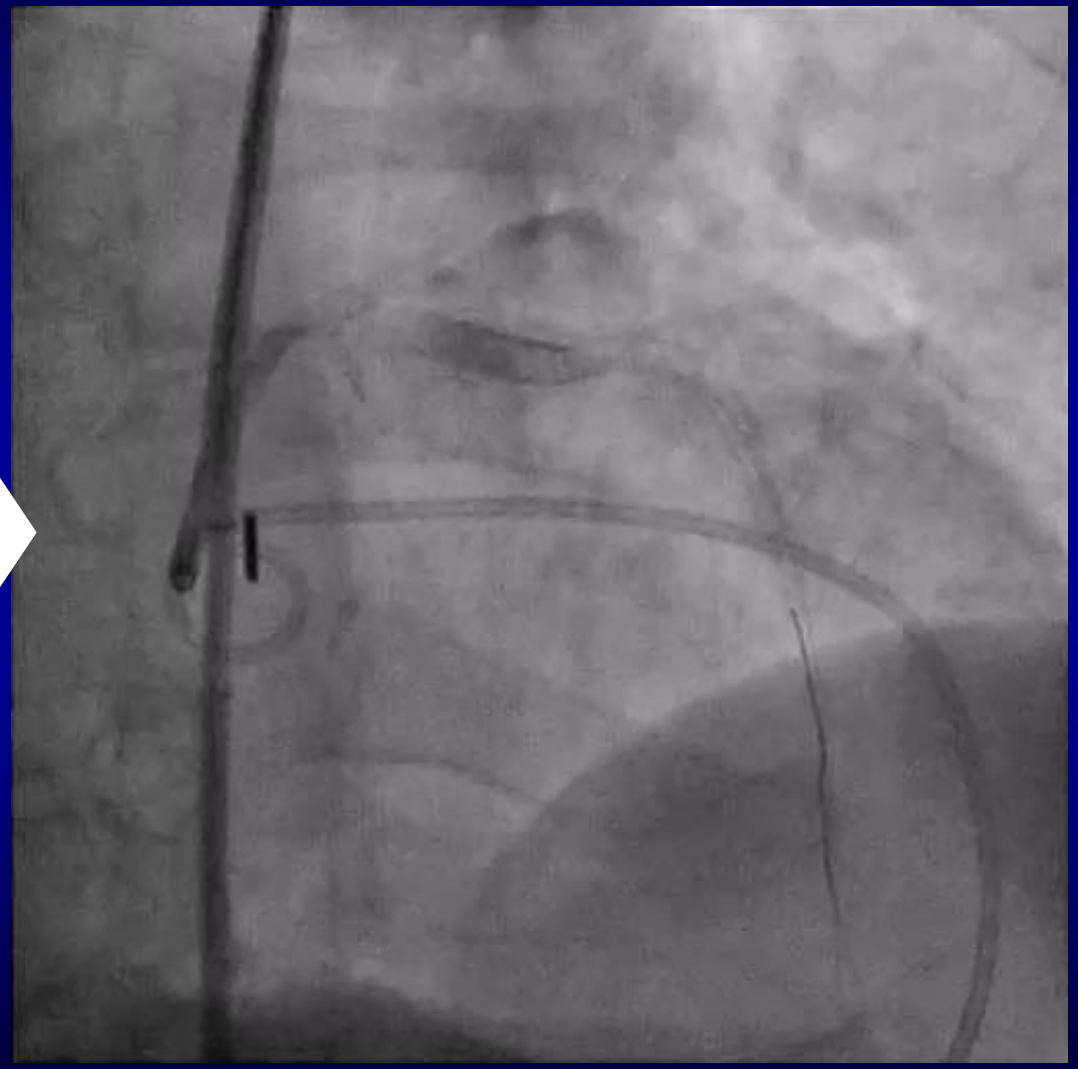

Final

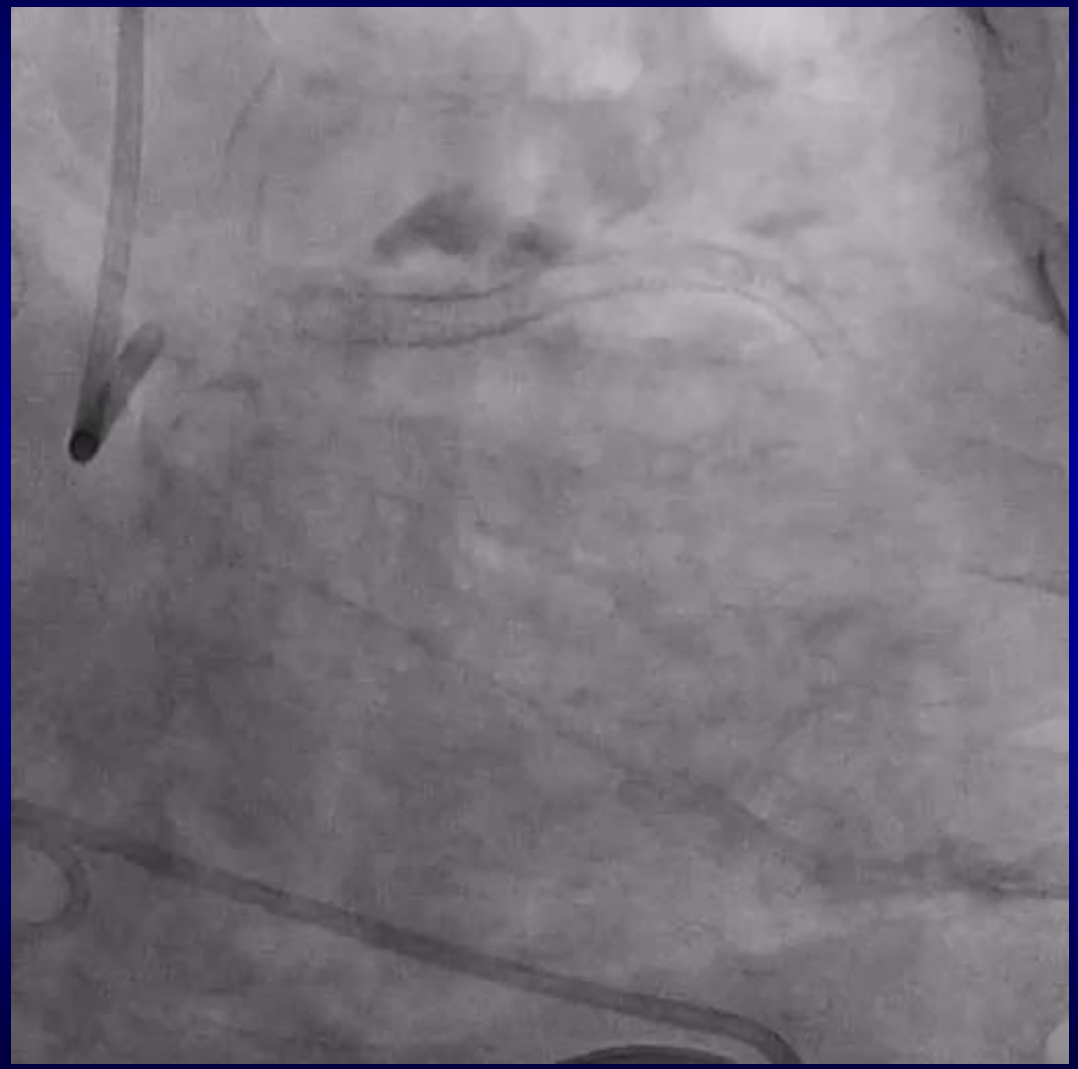

1 year follow-up

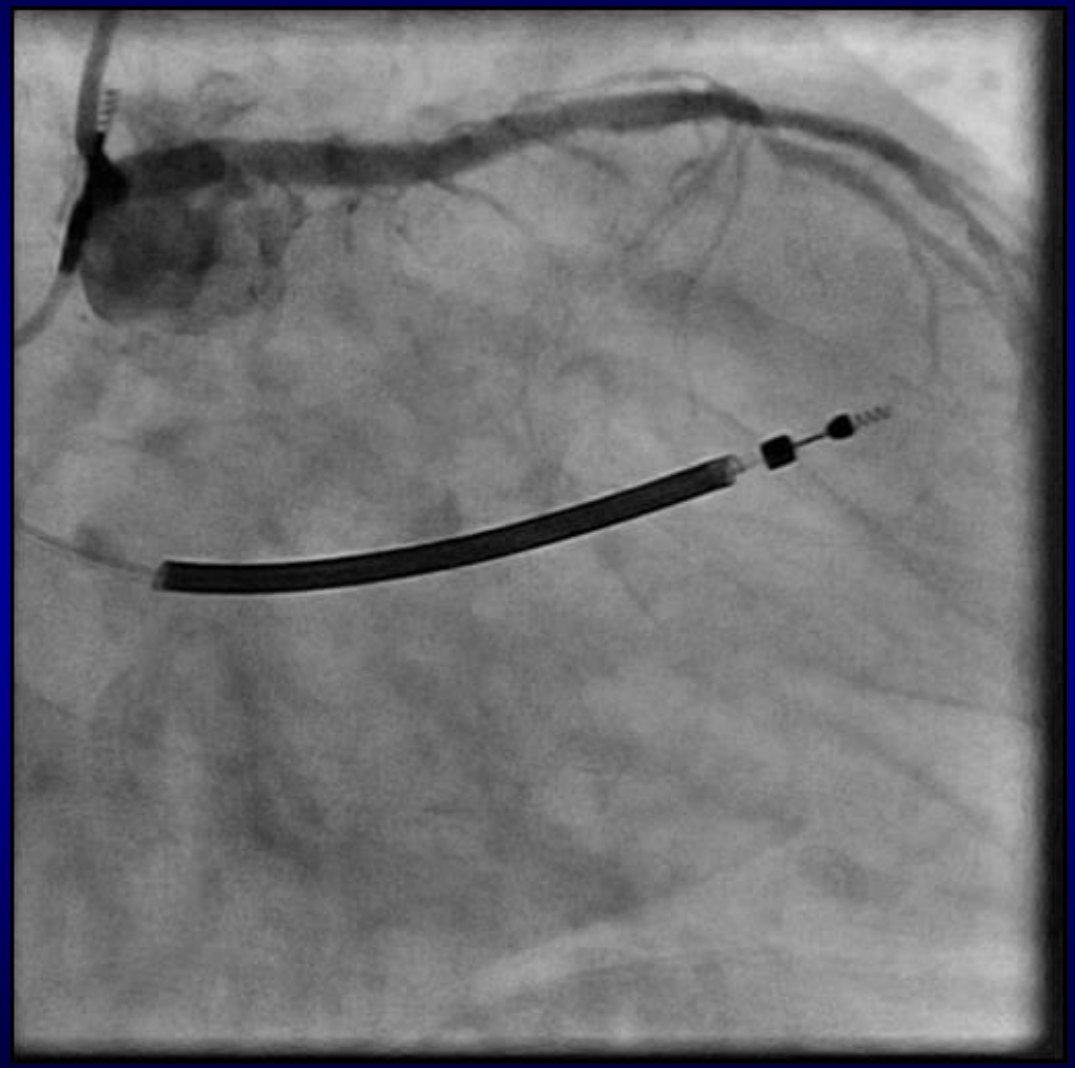

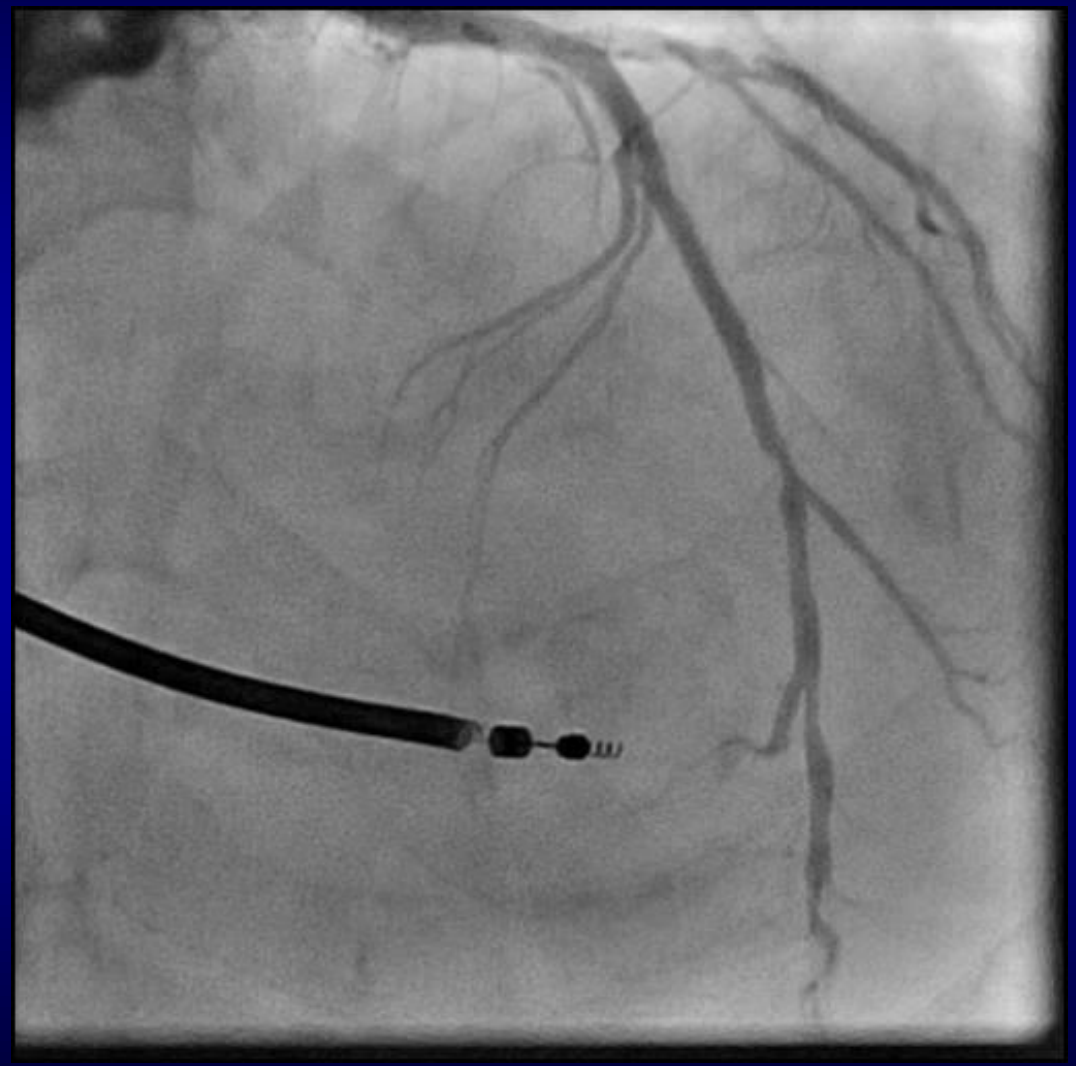

Rotational and Atherectomy (RA)

Indications

- Calcified lesion
- Undilatable lesion
- Unexpanded stent
- Diffuse long lesion
- In-stent restenosis
- Bifurcation lesion

Limitations

- Perforation
- Slow flow / No flow
- Burr entrapment
- Peri-procedure MI
- Wire bias and dissection
- Technically challenging

Coronary Perforation

Prevention ***- meticulous attention to guidewire position, careful and appropriate sizing of the balloon or stent prior to inflation, and avoiding over dilation or high pressure inflation exceeding the balloon's burst pressure***

Management **- Clinical suspicion should rise if patient develops sudden onset of acute/sharp chest pain or have sudden explained severe hypotension, particularly when inflating balloon or deploying a stent. If clinical suspicion arises, pull balloon immediately into the guide and perform angiography to confirm diagnosis.**

Management of Coronary Perforation

- The first aim is to prevent cardiac tamponade by immediate balloon inflation [SDS or the balloon present in the guide] proximal or at site of perforation at the lowest pressure possible. Usually 2-4 atmospheres for about 5-10 minutes is sufficient. However, may need to go to higher pressure and or longer duration to achieve hemostasis. Assess for hemostasis throughout intervention by injecting contrast at regular intervals

- Consider anticoagulation reversal- Decision to reverse needs to be balanced against potential risk of acute thrombosis, especially is a stent was just deployed. Heparin reversal: protamine sulfate 1mg IV/100 units of UFH (to achieve activated clotting time of <150s). Bivalirudin reversal: fresh frozen plasma is preferred and it results in partial reversal

- Aggressive treatment with intravenous fluids, atropine, vasopressors, mechanical circulatory support may be required if hemodynamics deteriorate. Call CT surgery for backup

- Emergent bedside echocardiogram should be obtained. If patient has significant effusion with tamponade physiology, perform emergent pericardiocentesis.

Case #3: August 21st 2018 CCCLive Case #110 73yrs M

Presentation:

Pt with known CAD and prior PCI in 2011, presented with CCS Class IV angina and palpitation due to new onset Afib requiring successful cardioversion. A cardiac cath on February 26, 2018 revealed 3 V+LM CAD: 60% distal LM bifurcation, 90% proximal calcified LAD, 80% D1, 90% D2, 95% prox LCx with Syntax score 34 and LVEF 50%. After Heart team discussion, CABG was declined due to significant pulmonary fibrosis and multi-vessel staged PCI was recommended. Pt underwent successful DES PCI of prox RCA (Promus Premier 4x16mm) and discharge home the same day. Subsequent stress MPI revealed mod anterolateral ischemia

Prior History: Hypertension, Hyperlipidemia, Chronic Afib, BPH, Pulmonary fibrosis, s/p PCI to RCA-RPL 2011

Medications: Once daily dosage except Apixaban BID

Clopidogrel 75mg, Apixaban 5mg, Losartan 50mg, Atorvastatin 40mg, Lanoxin 0.25mg, Metformin XL/Sitagliptin 1000mg/50, Sotalol 80mg, Finasteride 5mg

Case #3: Aug 21st 2018 CCC Live Case #110 73yrs M

SYNTAX Score: 34

Cardiac Cath 2/26/18: Right Dominance

III V +LM calcific CAD and LVEF 50%

LM: 60% distal bifurcation

LAD: 90% proximal calcified lesion, 80% D1, 90% D2

LCx: 95% prox LCx, moderate size

RCA: 90% prox RCA, patent stent in RPL

Pt then underwent DES PCI of RCA and did well and discharged home the same day. A f/u stress MPI revealed +ETT & moderate antero-lateral ischemia and EF 60%

Plan Today:

Planned for staged PCI of complex PCI of LM/LAD-D2/LCx bifurcation using rotational atherectomy and multiple DES

Case #3: 73yrs M

CCC Live case #110

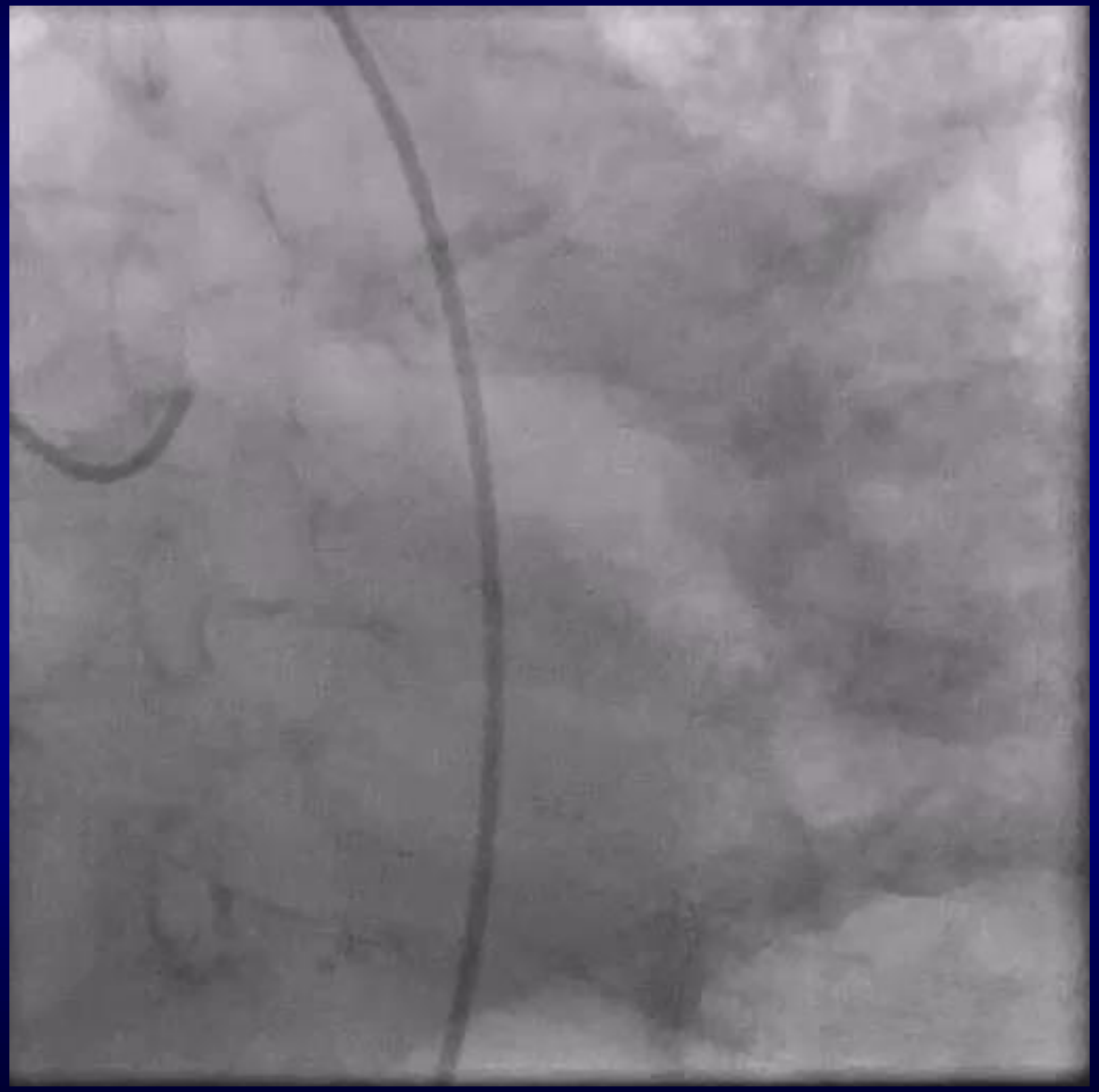

73yrs M – CCCLiveCases. #110

Guidelines for Safe Rota:

- 140,000-150,000 rpm
- Gradual advancement and slow, pecking motion
- Short 20 second runs with pauses in between
- Avoid deceleration greater than 5,000 rpm

After removal of entrapped burr

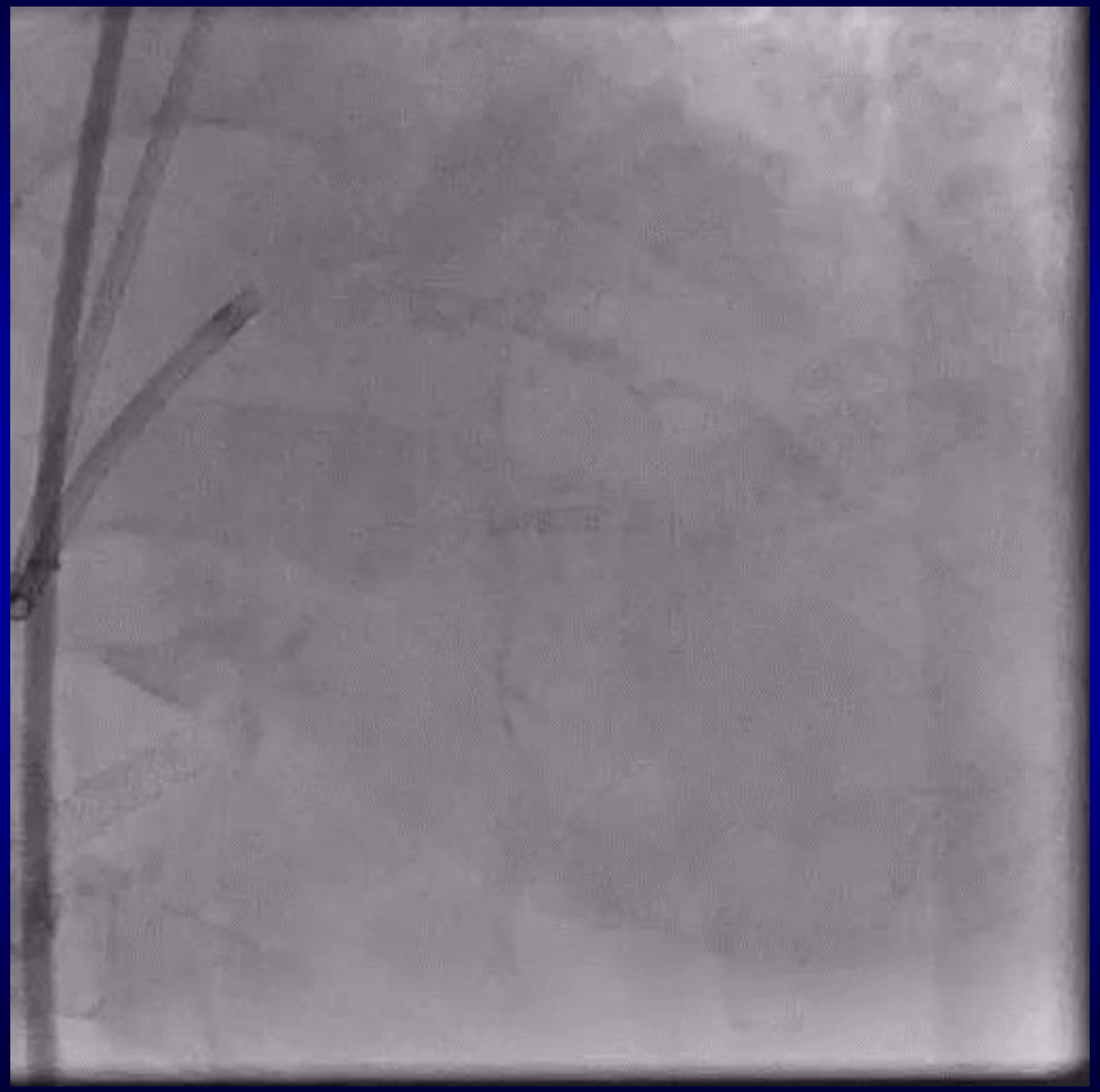

Final angiogram

Steps to Remove the Stuck Rota Burr

1) Apply forceful pull on the Rota wire with guide disengaged.
2) Administer high dose of vasodilators and aggressively pull the Rota burr.
3) Second arterial access and advance Fielder wire and a small (1~1.25mm) balloon distally, inflate at the level of Rota burr, then aggressively pull the Rota burr.
4) Advance Guide extension catheters on the Rota Burr: →

Steps to Remove the Stuck Rota Burr

Steps of Guide extension catheter

<u>7Fr Guide extension</u>: → Cut the Rota burr shaft at the connection outside the body, then advance 7Fr guide extension on the shaft till the Rota burr and pull aggressively.

<u>6Fr Guide extension</u>: → Cut the Rota burr and aggressively pull the Teflon covering sheath.

→ once done, then advance 6Fr Guide extension on the shaft till the Rota burr and pull aggressively.

RA: Cath Lab Setup and Technical Aspects

Circulation
Cardiovascular Interventions

American Heart Association

North American Expert Review of Rotational Atherectomy

Authors:
Samin K. Sharma, MD [1]*; Matthew I. Tomey, MD [1]; Paul S. Teirstein, MD [2]; Annapoorna S. Kini, MD [1]; Arthur B. Reitman, MD [3]; Arthur C. Lee, MD [4]; Philippe Généreux, MD [5]; Jeffrey W. Chambers, MD [6]; Cindy L. Grines, MD [7]; Stevan I. Himmelstein, MD [8]; Craig A. Thompson, MD [9]; Ian T. Meredith, MBBS, PhD [10]; Aparna Bhave, PhD [9]; and Jeffrey W. Moses, MD [11]

Key Elements of Optimal RA Technique

Maximum burr-to-artery ratio of 0.4 to 0.6
Rotational speed of 140 000 to 150 000 rpm, with higher speeds reserved for cases in which burr cannot cross lesion despite optimal technique
Gradual burr advancement using pecking motion
Short ablation runs up to 20 s in duration
Avoidance of decelerations exceeding 5000 rpm
Final polishing run at completion of atherectomy

Preparatory Steps for RA

Confirm optimal antiplatelet and anticoagulant therapy
Confirm appropriate position of RotaWire across lesion
Open and prepare noncompliant balloon sized 1:1 with reference vessel diameter
After assembly and connection of device, verify free flow of flush solution
Ensure proper gas pressure (500 psi in tank and 80–110 psi in console)
Verify free movement of the advancer knob
Backload the burr onto the RotaWire and apply WireClip torquer to back end
Check and optimize speed outside the body
Lock advancer knob
Ensure hemostatic valve is not closed too tightly
Advance burr via guide as associate withdraws wire to maintain stable wire position
Three steps to remove system tension
1. Unlock and gently advance and retract advancer knob
2. Disengage hemostatic valve and gently advance and retract drive shaft
3. Tap on foot pedal while on Dynaglide (low rotational speed) mode

Sharma, Tomey, Teirstein, Kini et al., Circulation CV Intervention 2019;12:e007448

Case #4: From ComplicAID WebApp

Clinical Presentation

63 year old male who presented with chest pain (CCS Class 3),and was referred for PCI of the LM trifurcation. Stress MPI: Mild anterolateral ischemia and moderate posterior scarring. Prior Cardiac Catheterization: Ostial LM 70-80%, distal LM 60-70% stenosis, proximal LAD 70-80% stenosis, D1 90% stenosis, OM1 total occlusion and fills via SVG, LPL 60-70% stenosis, proximal RI 70-80% stenosis, proximal RCA 80-90% stenosis and fills retrograde via SVG; SVG-Y graft to RPDA and OM1 (patent), LIMA to LAD known to be occluded. LVEF 53%.

Case #4: From ComplicAID WebApp

Past Medical History

HTN, HLD, DM, Former Tobacco Use, CAD s/p 3-Vessel CABG and Multiple PCI's, ESRD on iHD, PVD s/p Fem-Pop Bypass and Bilateral Toe Amputations, BPH

Medications

Home Medications: Aspirin, Clopidogrel, Rosuvastatin, Carvedilol, Valsartan-Hydrochlorothiazide, Isosorbide Monnitrate, Clonidine, Doxazosin, Insulin

Abrupt Vessel Closure: Pre-procedure EKG

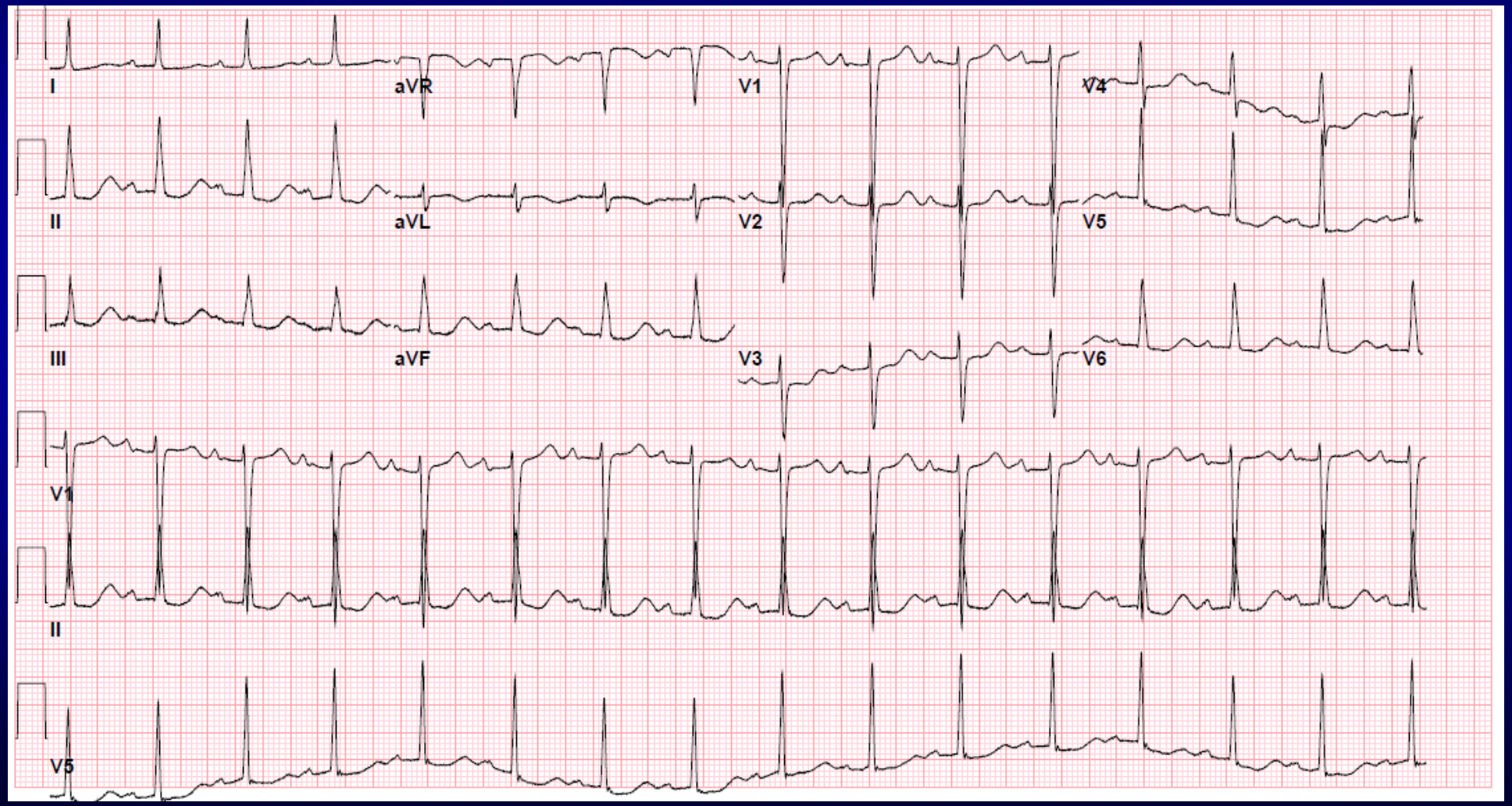

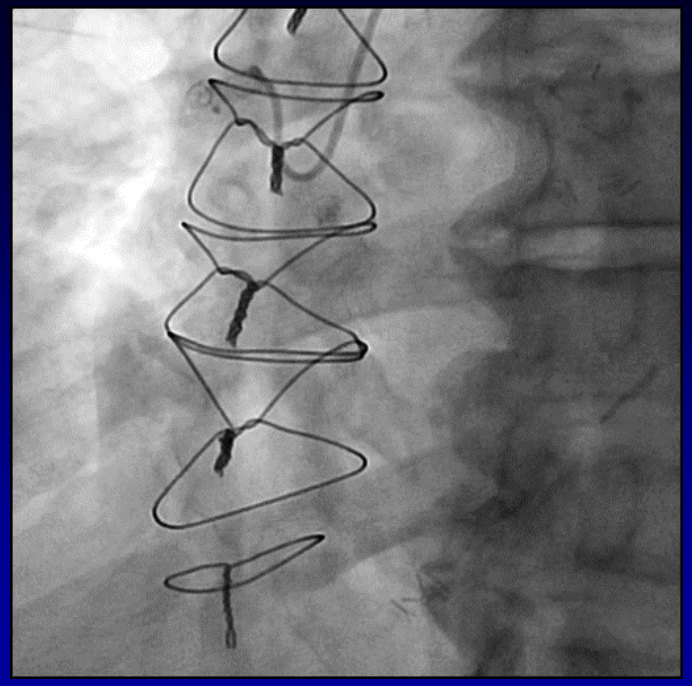

- Patent radial artery Y graft to the right posterior descending artery (RPDA) and to the first obtuse marginal branch (OM1).

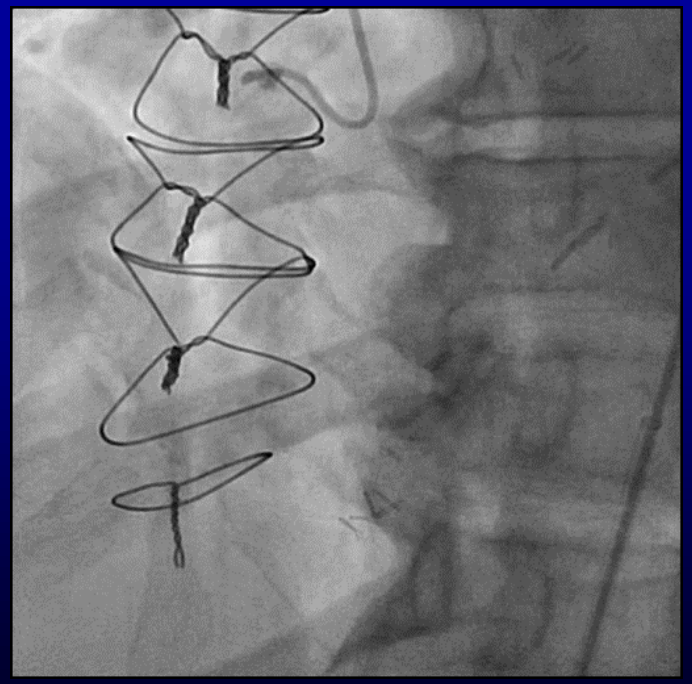

- Right coronary artery (RCA) angiography
  - no obstruction in the right coronary artery (RCA).

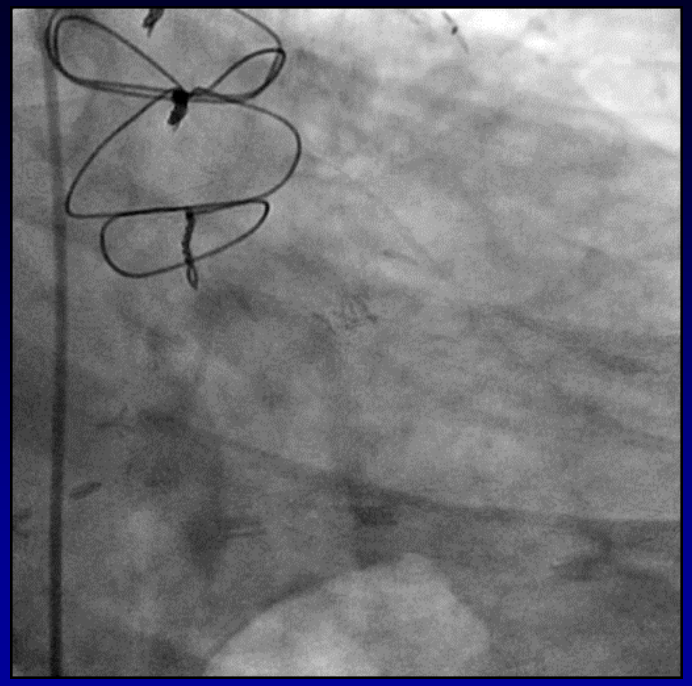

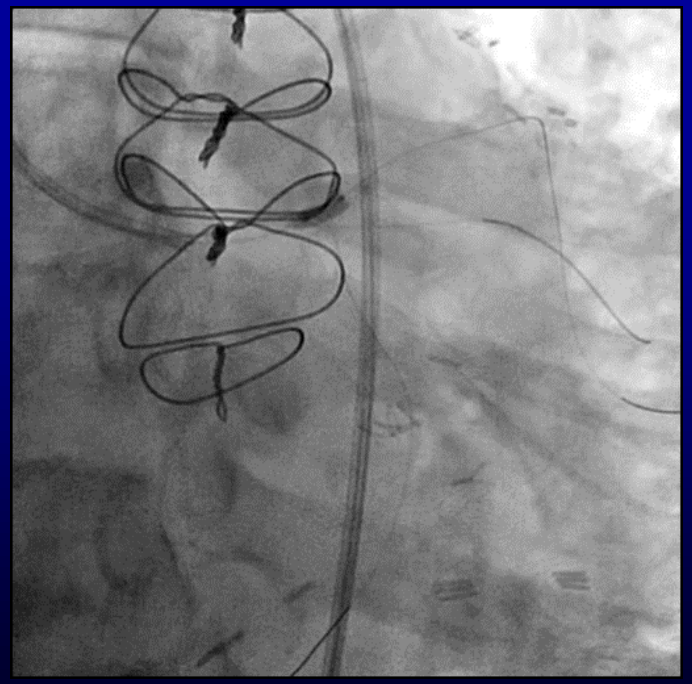

- Left coronary artery angiography - distal left main (LM) (60-70%) trifurcation lesion with 70-80% stenoses in the ostial segments of the left anterior descending (LAD), left circumflex (LCx) and ramus intermedius (RI).
- Wiring of LM trifurcation followed by cutting balloon angioplasty of the LAD with a Flextome 3.0/6mm balloon.

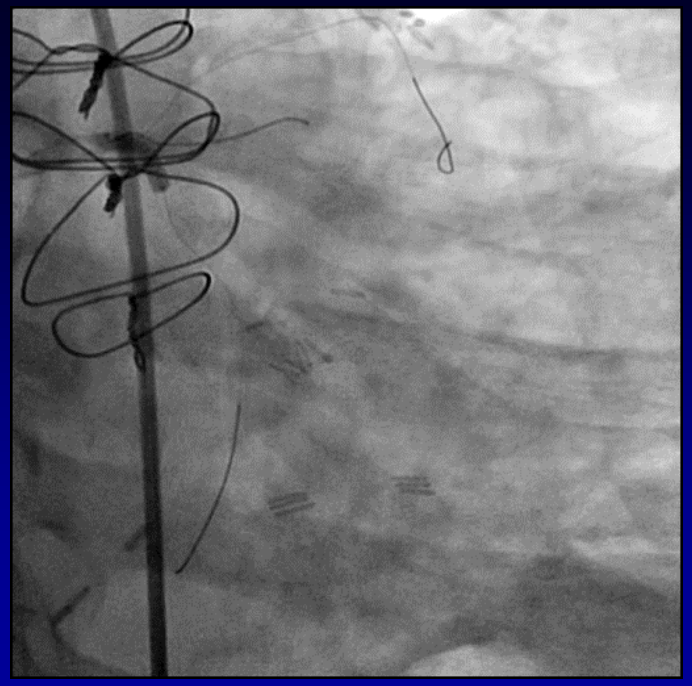

- Pre-dilatation of the LCx lesion with a Trek 2.5/15mm balloon.

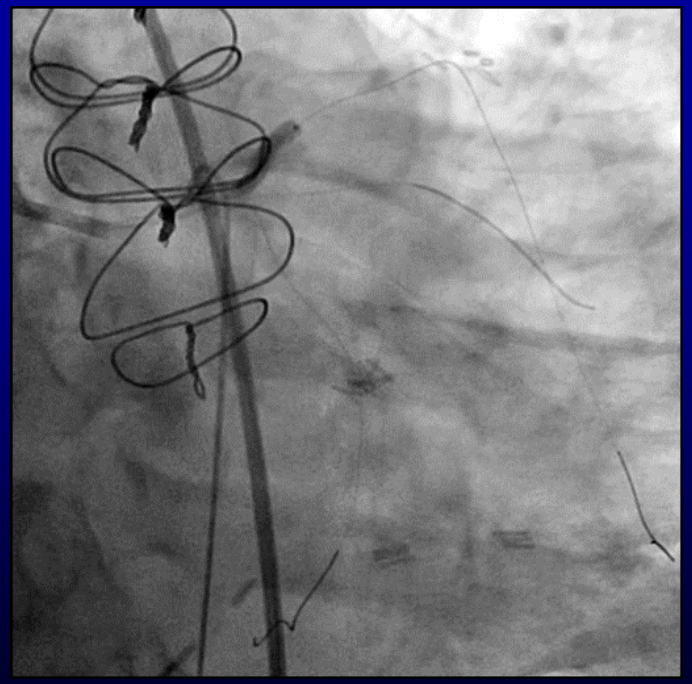

- Pre-dilatation of the proximal LAD lesion with a Quantum Apex 3.0/12mm balloon.

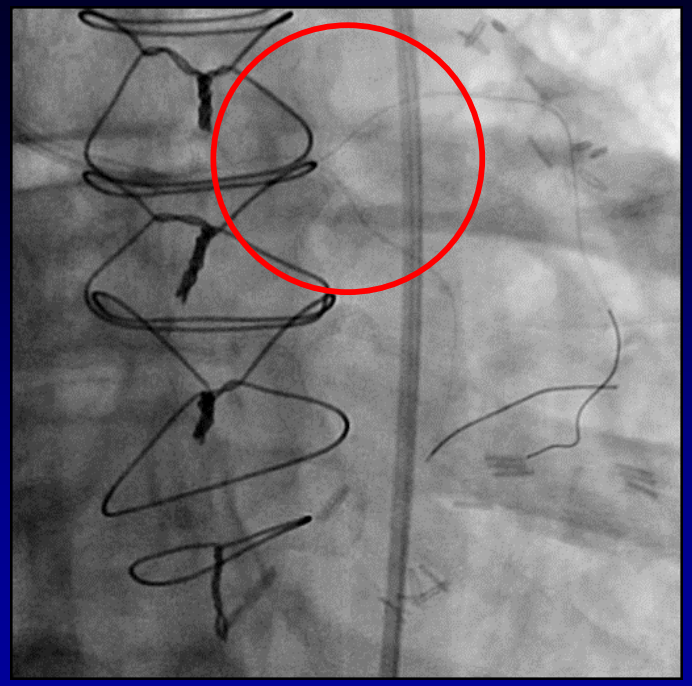

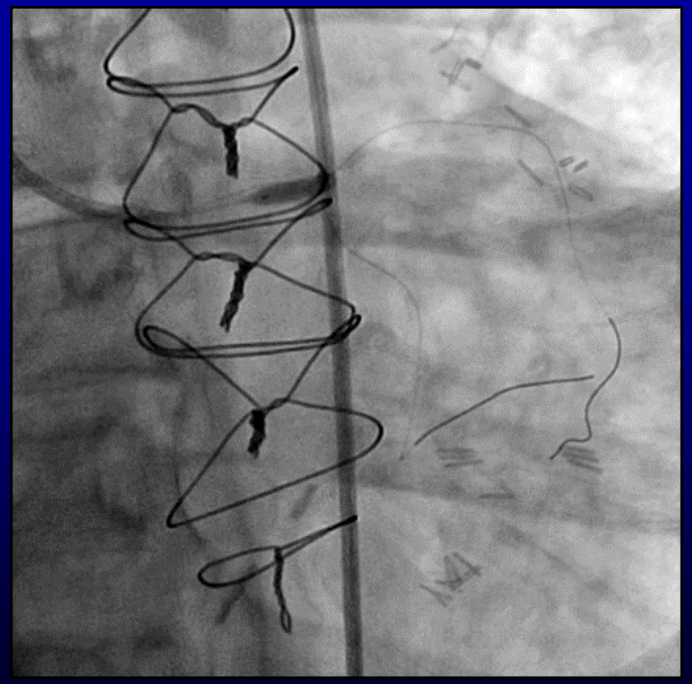

- After lesion pre-dilatation, patient has circulatory collapse, and IABP was emergently placed. Angiography of the LCA showing that abrupt vessel closure (AVC) was most likely due to thrombus. Patient developed VT/VF, treated with a single debrillator shock of 200 J.

- IC vasodilators were administered through the guide catheter without improvement in flow. This was followed by serial balloon inflations of the LM trifurcation performed with a Quantum Apex 3.0/12mm balloon.

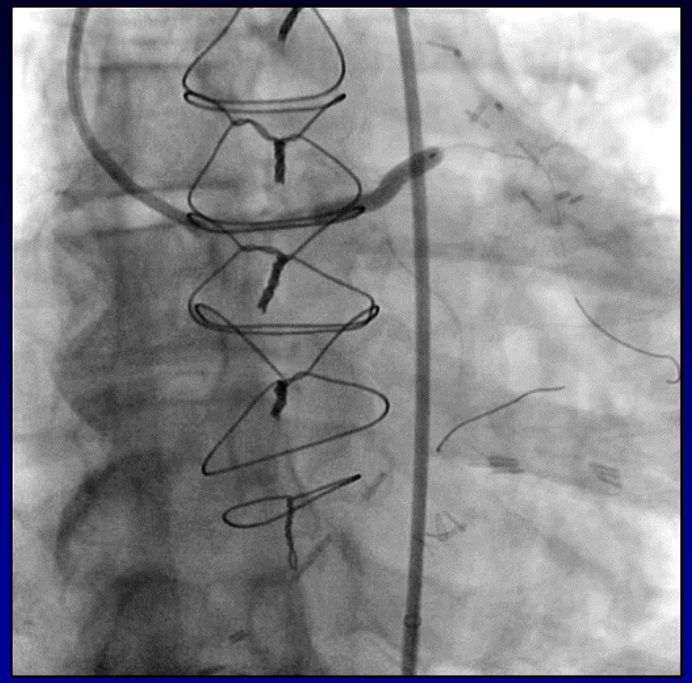

- Deployment of a Xience Xpedition 3.25/23mm stent in the LM extending into the proximal LAD.

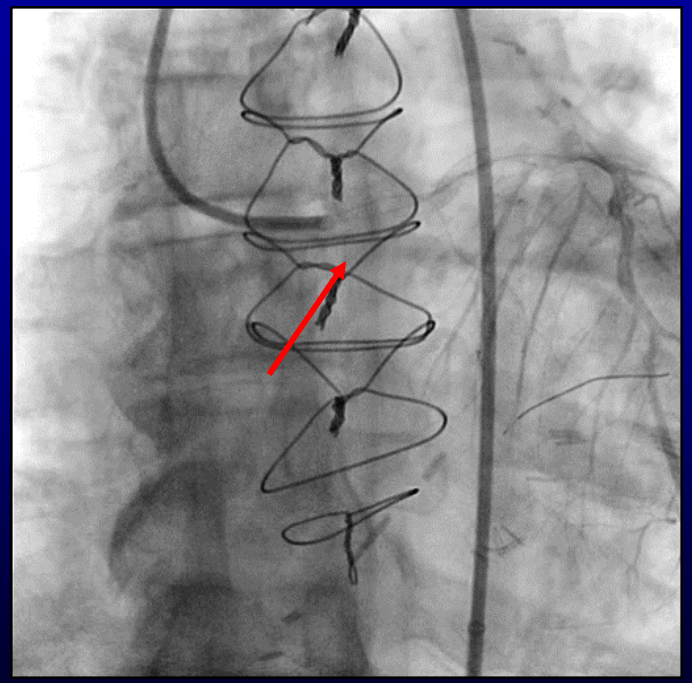

- Angiography of the LCA after stent placement showing restoration of TIMI 3 flow in the LAD. However, the procedure was further complicated by stent jailing of the RI and LCx.

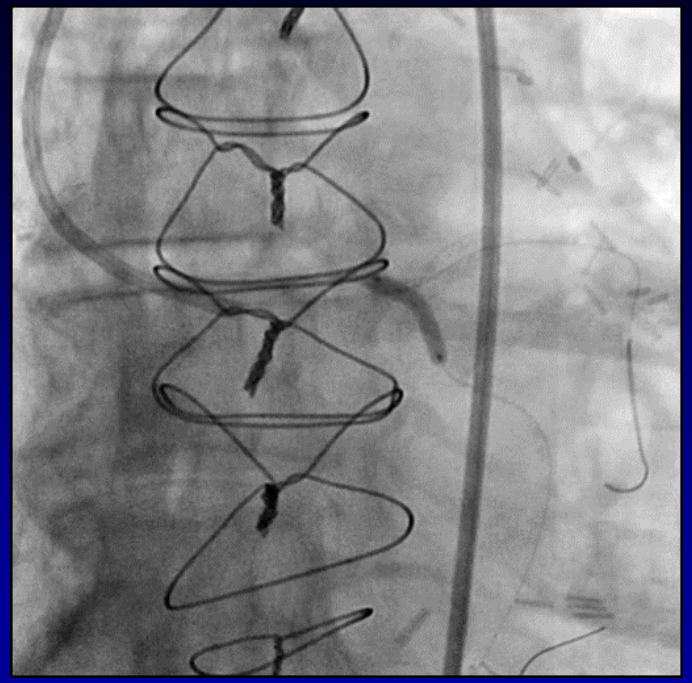

- Balloon dilatation of the ostium of the LCx with a Trek 2.5/15mm balloon.

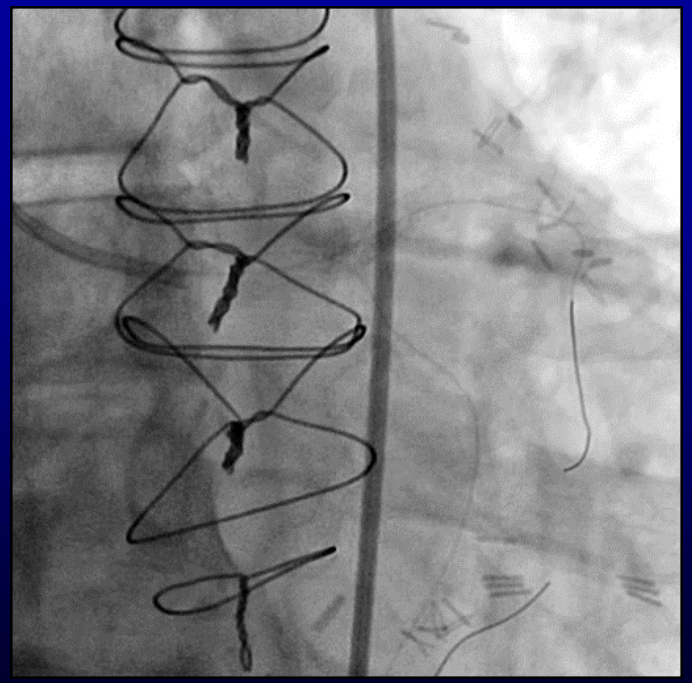

- Angiography of the LCA after balloon dilatation of the LCx ostium showing restoration of flow.

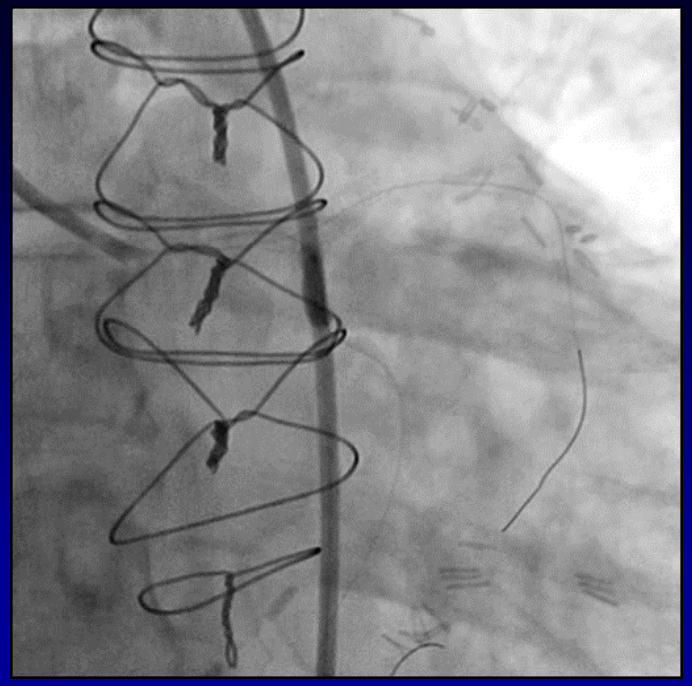

- Deployment of a Xience Xpedition 3.0/12mm stent in the proximal LCx.

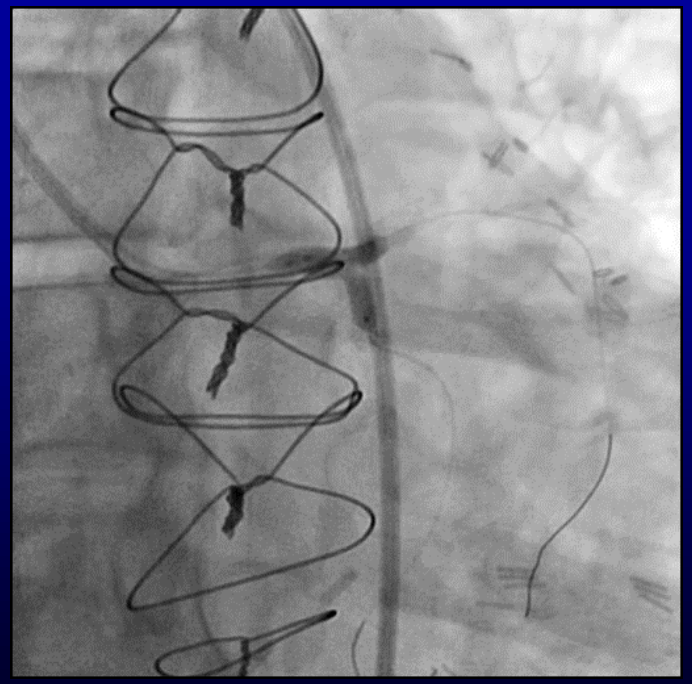

- Kissing balloon inflation (KBI) of the LAD and LCx with Trek NC 3.5/12mm and Trek NC 3.0/12mm balloons respectively.

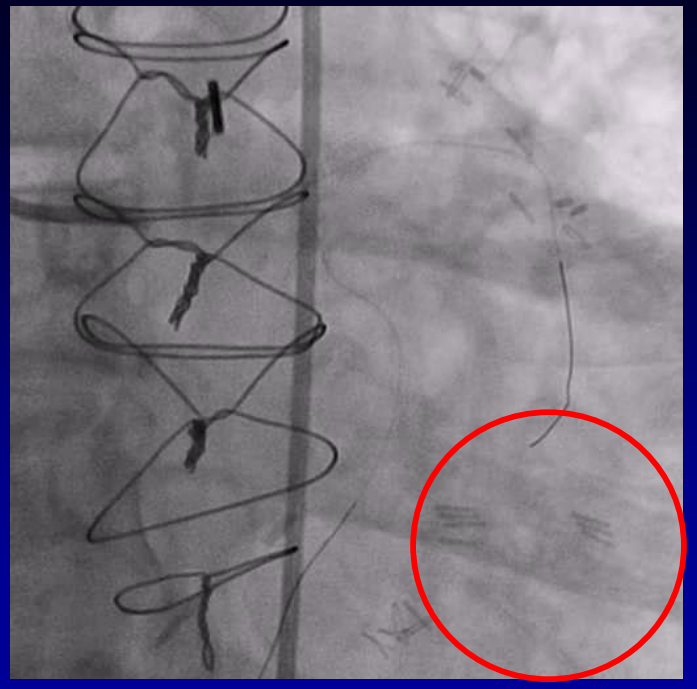

- Angiography of the LCA after KBI concerning for embolization of thrombus in the distal LAD.

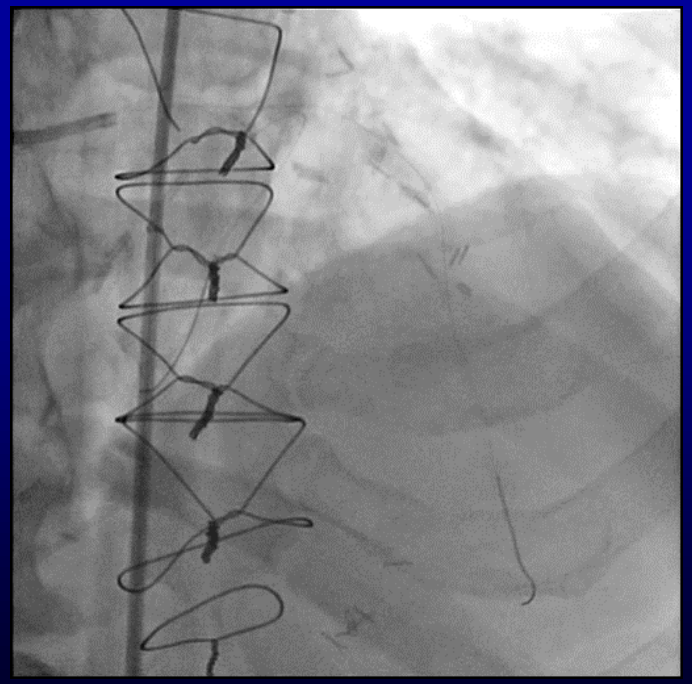

- Angiography of the LAD after wiring across the thrombus showing restoration of flow (TIMI 3).

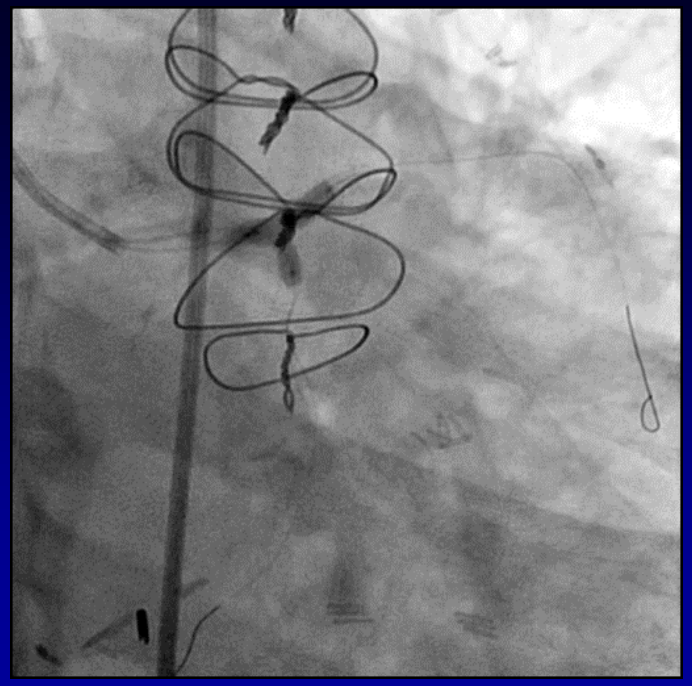

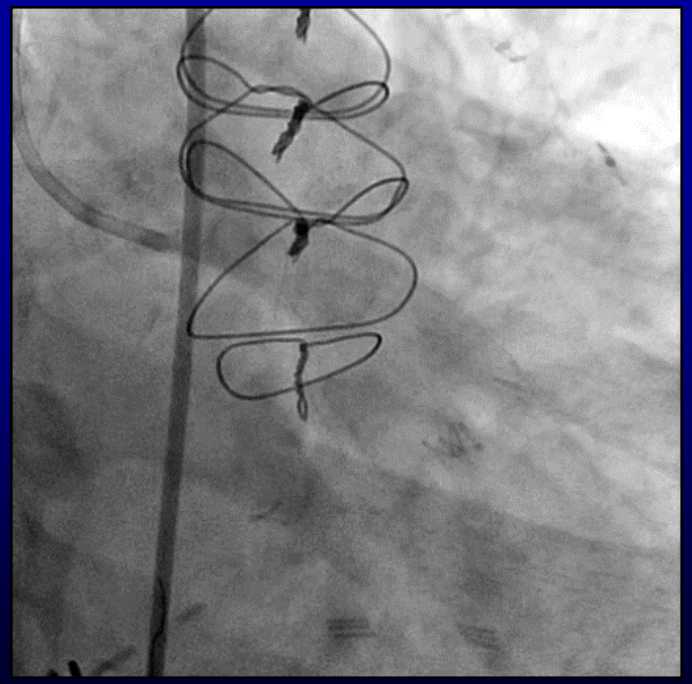

- Repeat KBI of the LM-LAD and LCx performed using the same balloons.
- Final angiography of the LCA showing successful intervention of the LM-LAD and LCx. Troponin-I peaked at 38.2 ng/mL and CK-MB peaked at 16.9 ng/mL.

Abrupt Vessel Closure: post-procedure EKG

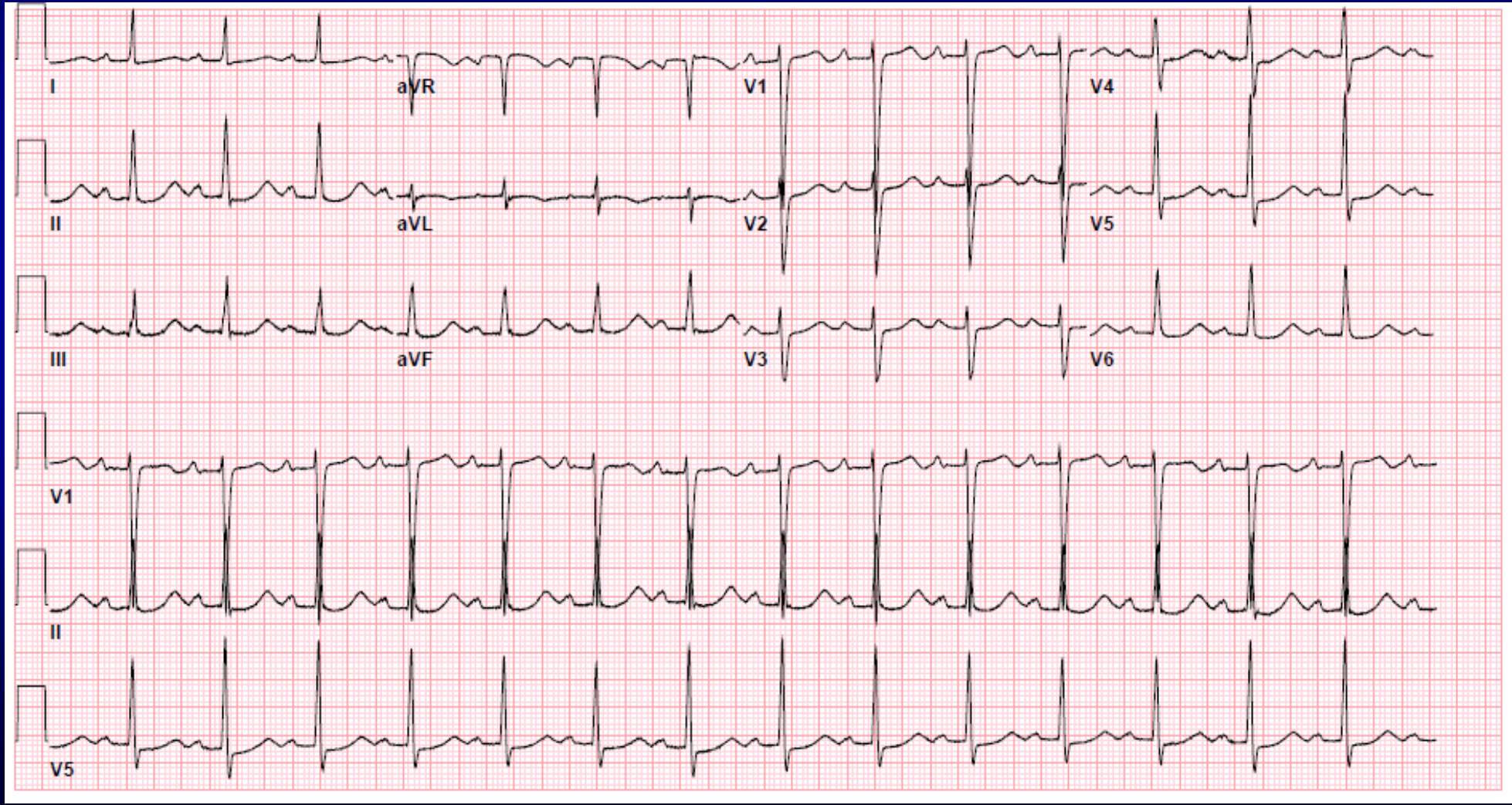

CardiologyApps.com/ComplicAID

Home - Cardiology Apps

cardiologyapps.com

Home | The Apps | About Us | Contact Us | Search Site

- ComplicAID
- STEMIcathAID
- CalcificAID
- TAVRcathAID
- OCTAID
- TransceptAID
- BifurcAID

About ComplicAID

ComplicAID is an educational website containing select cases designed to teach complications of PCI. Every case details the steps that led up to the complication, as well as key take-away points on how to manage and avoid such complications in the future. Explore cases involving dissections, perforations, and atherectomy as well as less common complications such as longitudinal stent deformation, vasospasm, and air embolism.

Access the Web App

Our Latest Mobile Apps

CalcificAID

CalcificAID guides medical professionals through the calcification.

TAVRCathAID

The TAVRcathAID app utilizes adoption of innovative teaching styles via smartphone

OCTAID

The OCTAID app is an educational tool which has been developed as a means to teach intra-coronary

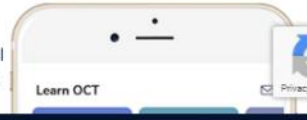

https://cardiologyapps.com/complicaid/

10:01 AM
8/20/2020

ComplicAID – Abrupt Vessel Closure

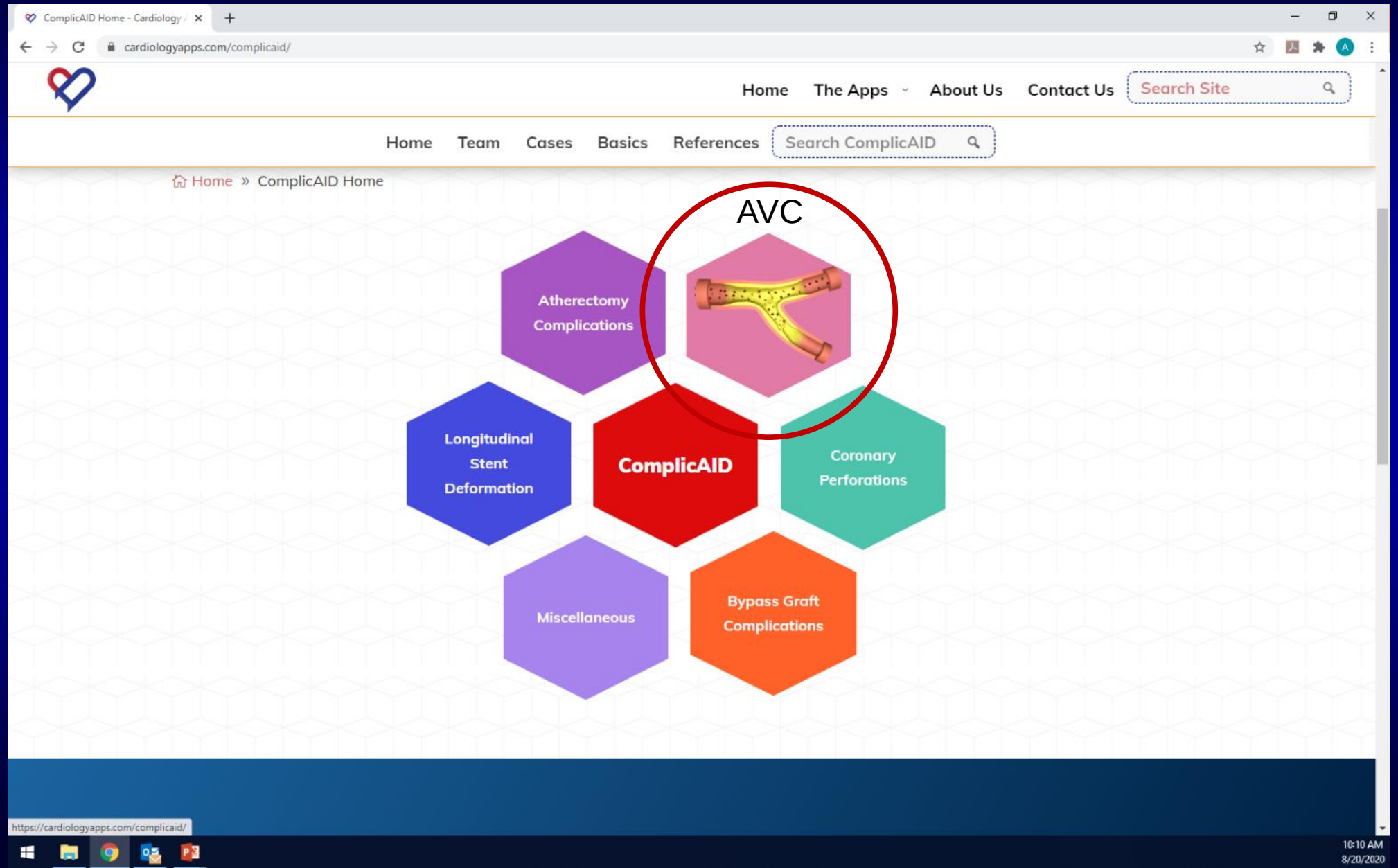

Abrupt Vessel Closure - Case Examples

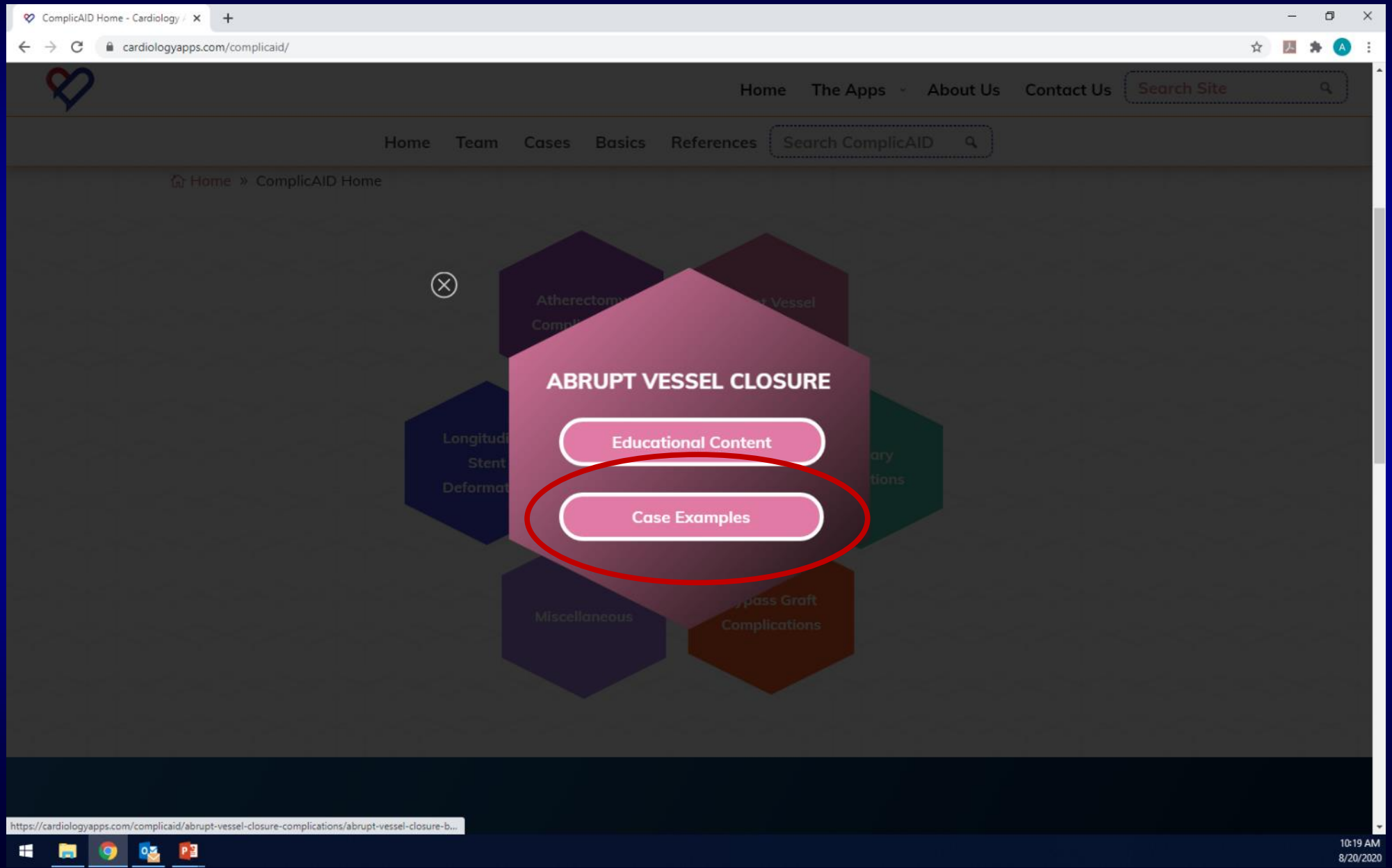

Coronary Dissections

Abrupt Vessel Closure Complicat

cardiologyapps.com/complicaid/abrupt-vessel-closure-complications/

Home The Apps About Us Contact Us Search Site

Home Team Cases Basics References Search ComplicAID

Home » ComplicAID Home » Abrupt Vessel Closure Complications Charts

Abrupt Vessel Closure

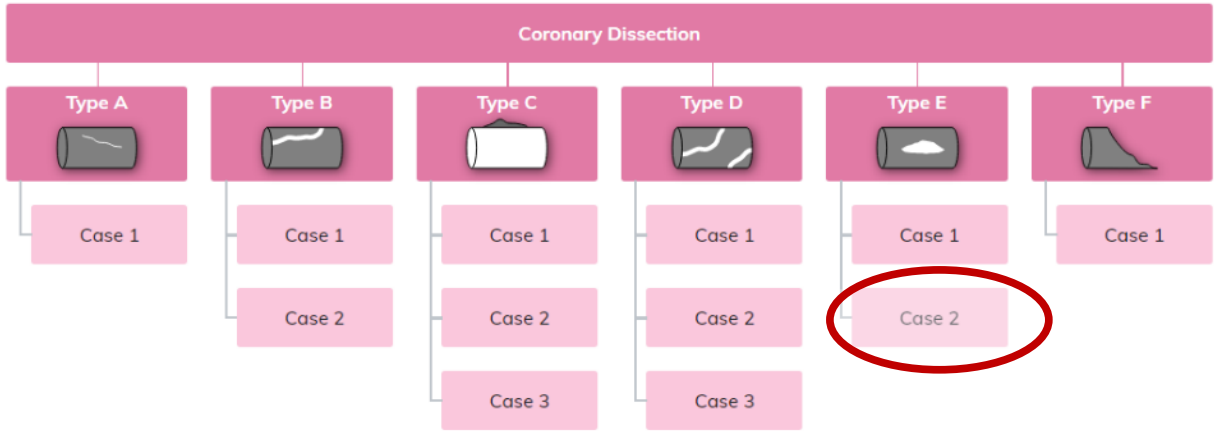

10:43 AM
8/20/2020

Relevant Educational Content

Dissection Type E - Case 2 - Card

cardiologyapps.com/complicaid/complicaid-case-reviews/dissection-type-e-case-2/

Home | The Apps | About Us | Contact Us | Search Site

Home | Team | Cases | Basics | References | Search ComplicAID

Home » ComplicAID Case Reviews » Dissection Type E – Case 2

Coronary Dissections

Submit a Case

Educational Content

Dissection Type E – Case 2

Clinical Presentation

- 50-year-old male who presented with chest pain (CCS Class III).

Past Medical History

- HTN, HLD, DM2, GERD
- LVEF 60%

Clinical Variables

- Prior Cardiac Catheterization: Anomalous RCA with mid RCA 90-95% stenosis, mid LAD 60-70% stenosis, D1 50-60% stenosis. S/p successful PCI of RCA.

Medications

- Home Medications: Aspirin, Clopidogrel, Atorvastatin, Isosorbide mononitrate, Valsartan, Amlodipine, Metformin, Pantoprazole
- Adjunct Pharmacotherapy: Clopidogrel, Bivalirudin

10:45 AM
8/20/2020

CardiologyApps.com/ComplicAID

Mount Sinai Heart

Dissection Type E - Case 2 - Card

cardiologyapps.com/complicaid/complicaid-case-reviews/dissection-type-e-case-2/

Home | The Apps | About Us | Contact Us | Search Site

Home | Team | Cases | Basics | References | Search ComplicAID

Home » Co

Submit a Case

Educational Content

Dissection Type E –

Clinical Presentation

- 50-year-old male who pres

Past Medical History

- HTN, HLD, DM2, GERD
- LVEF 60%

Clinical Variables

- Prior Cardiac Catheterizatio

of RCA.

Medications

- Home Medications: Aspirin,
- Adjunct Pharmacotherapy:

ABRUPT VESSEL CLOSURE (AVC)

- AVC is the commonest major complication of PCI[8]
- Incidence - 0.3% [used to be 3% in pre-stent era][9]
- Risk factors:[10]
  - Proximal vessel tortuosity
  - Diffuse lesion
  - Pre-existing thrombus
  - Degenerated vein graft
  - Extremely angulated lesion
  - Unstable angina
  - Multivessel disease
  - Female gender
  - Chronic renal failure
- Common causes:[10]
  - Coronary dissection
  - Intracoronary thrombus formation
  - Native thrombus (or atheroma) embolization
  - Air injection

10:47 AM
8/20/2020

Case #5 from ComplicAID WebApp

Present Clinical Presentation - 50-year-old male who presented with chest pain (CCS Class III). Prior Cardiac Catheterization: Anomalous RCA with mid RCA 90-95% stenosis, mid LAD 60-70% stenosis, D1 50-60% stenosis. S/p successful PCI of RCA. LVEF 60%

Prior History - HTN, HLD, DM2, GERD

Medications - Home Medications: Aspirin, Clopidogrel, Atorvastatin, Isosorbide mononitrate, Valsartan, Amlodipine, Metformin, Pantoprazole

Case #5 from ComplicAID WebApp
Pre-procedure EKG

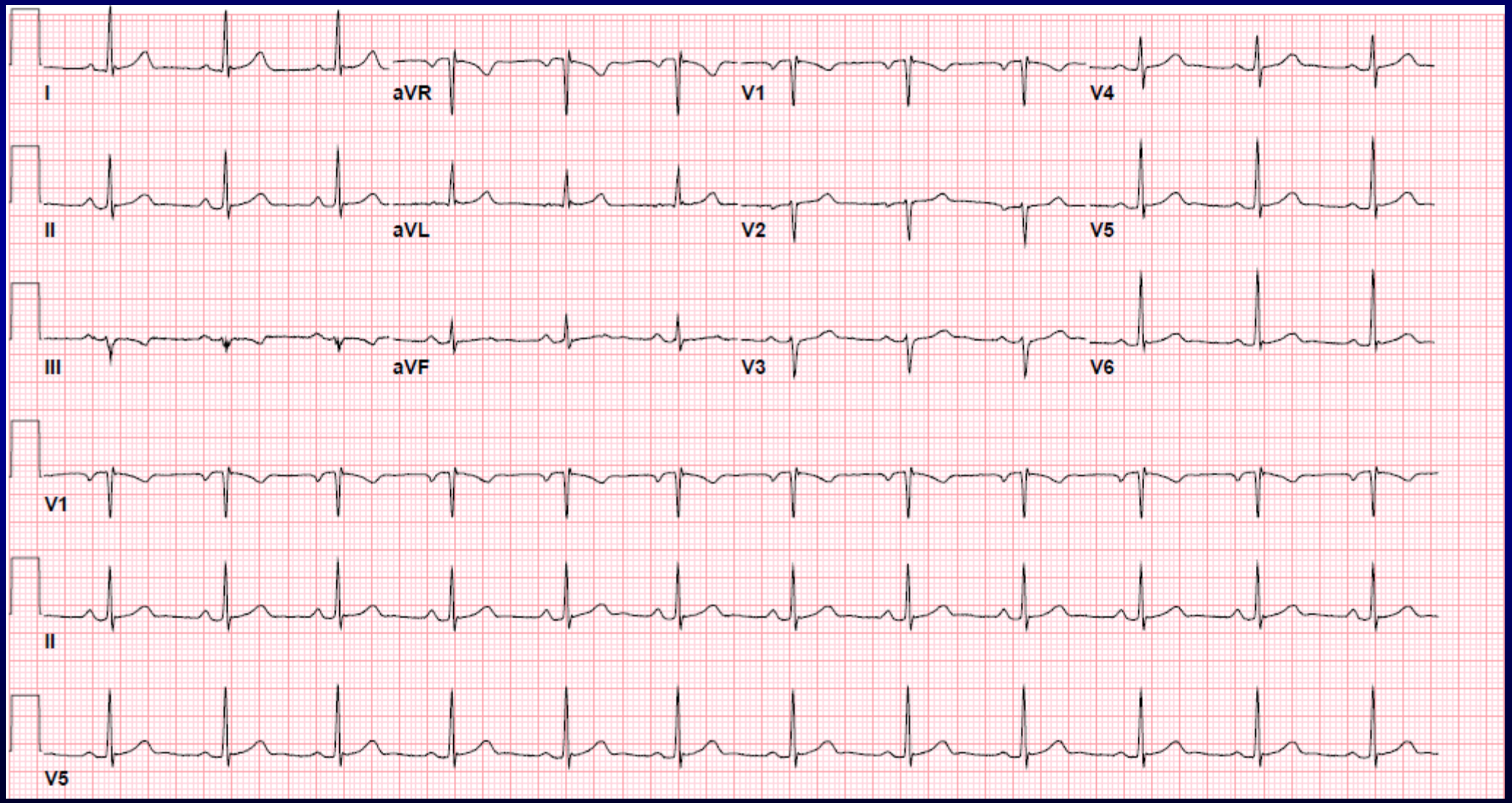

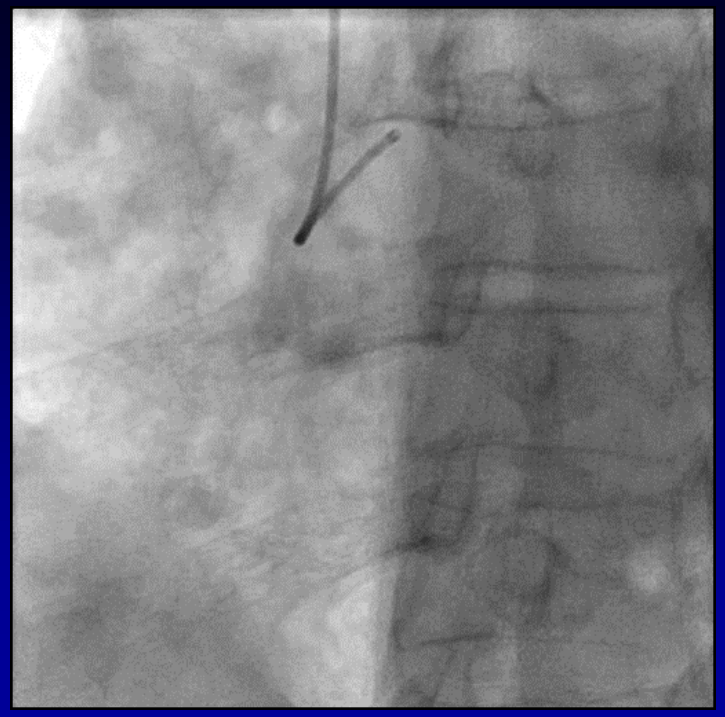

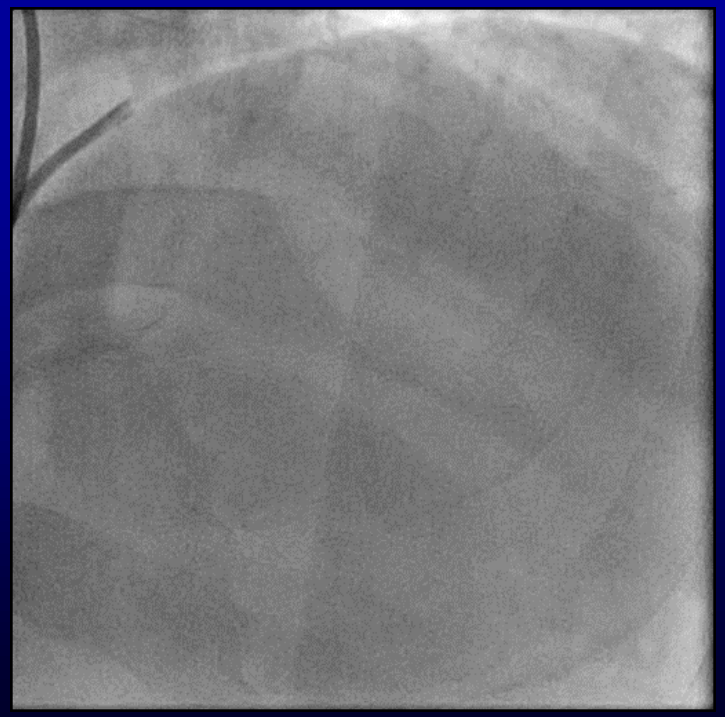

- Right coronary artery (RCA) angiography
  - patent stent in the mid RCA

- Left coronary artery angiography
  - 70-80% mid left anterior descending (LAD) lesion and 50-60% stenosis in the first diagonal branch (D1)

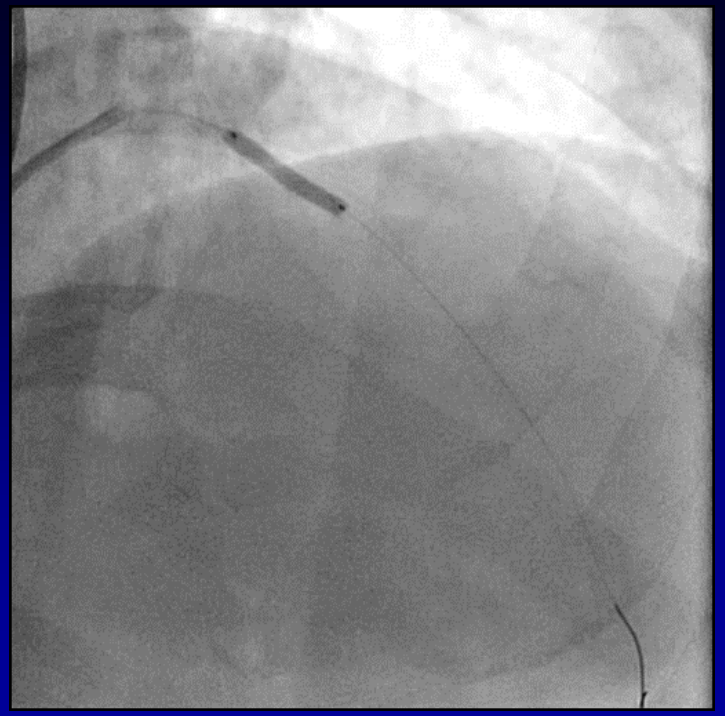

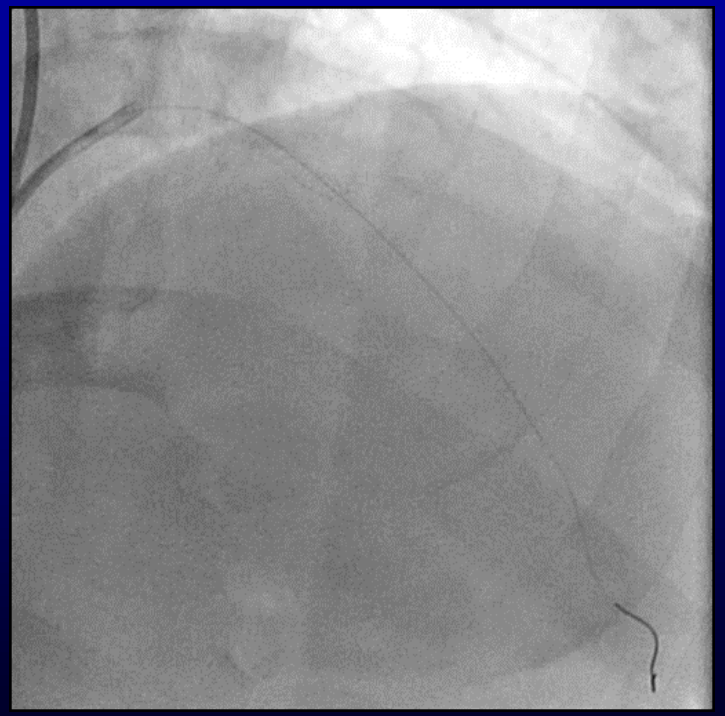

- Deployment of a Xience Alpine 3.0/18m m stent in the mid LAD.

- Angiography of the LAD after stent placement.

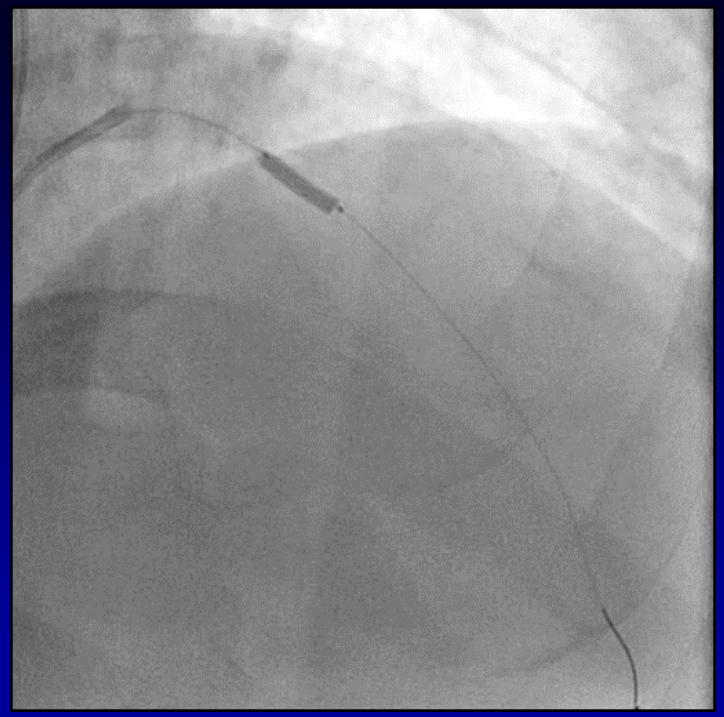

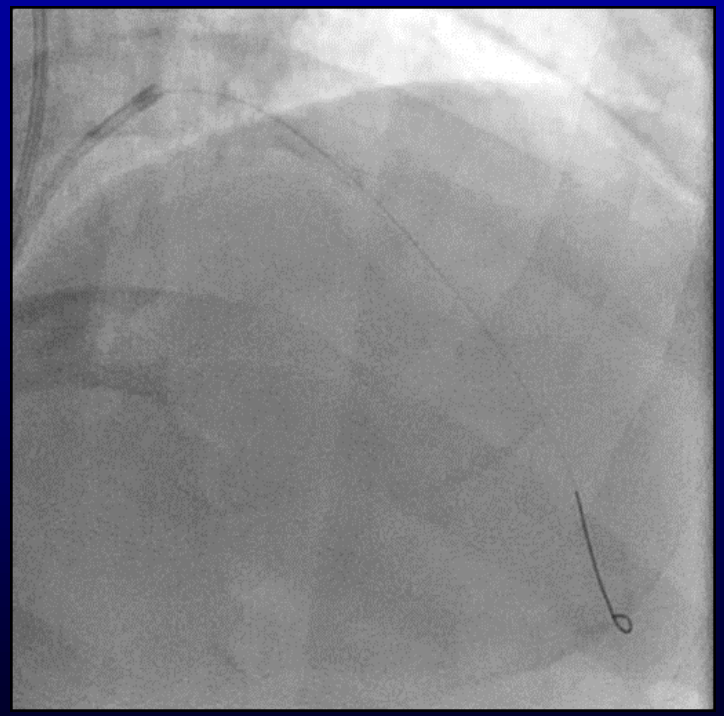

- Post-dilatation of stent placed in mid LAD with a NC Quantum Apex 3.25/12 mm balloon.

- Angiography of LAD after stent post-dilatation.

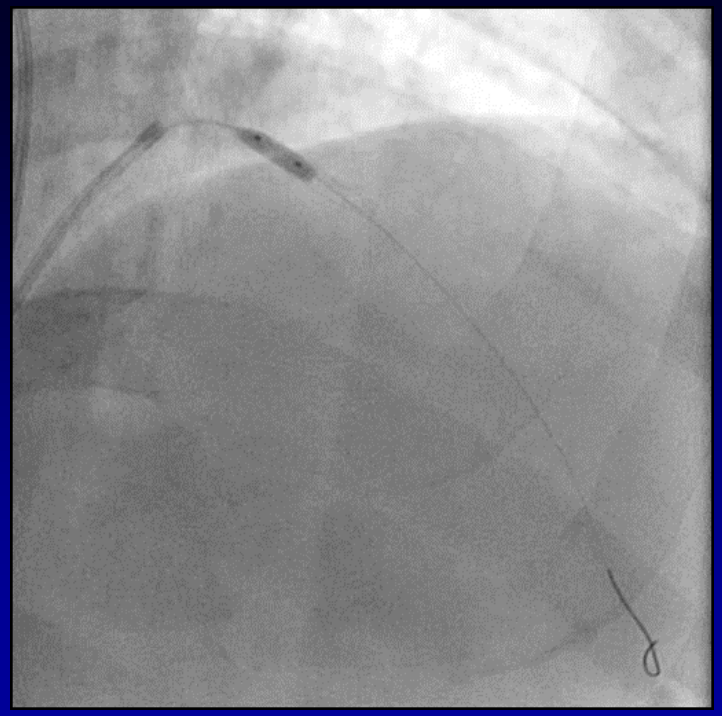

- Post-dilatation of stent placed in mid LAD with a NC Quantum Apex 3.5/8 mm balloon.

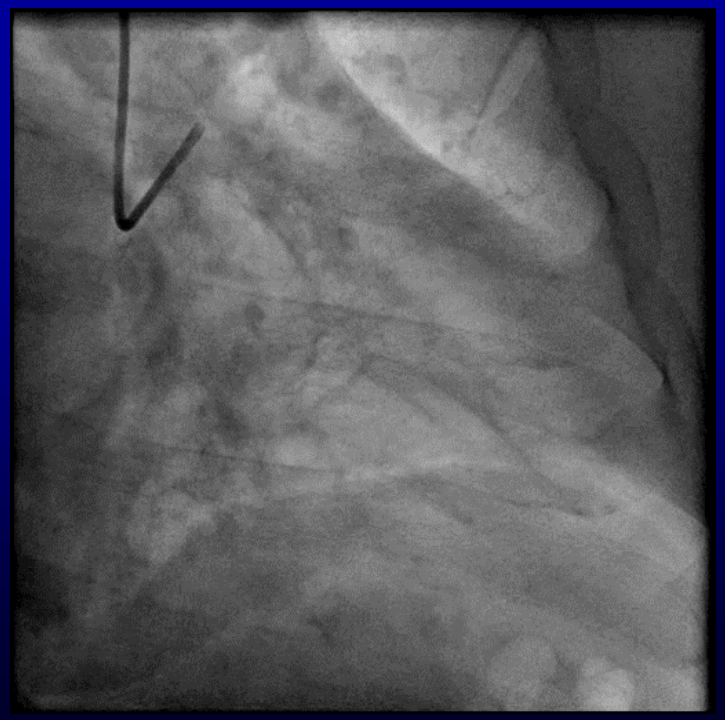

- Angiography of LAD after stent post-dilatation showing a possible distal stent edge Type E dissection vs thrombus with TIMI 2 flow.

Dissection Classifications

Type A	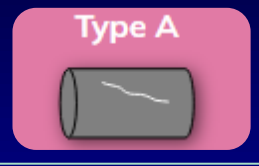	Minor radiolucency within the coronary lumen without dye persistence
Type B		Parallel tracks or double lumen separated by a radiolucent area during angiography without dye persistence
Type C	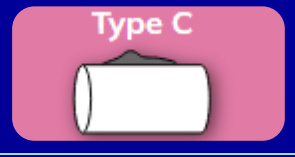	Extraluminal, persisting extravasation of contrast
Type D		Spiral luminal filling defects
Type E	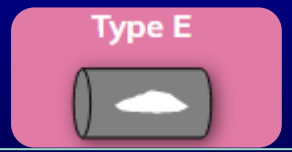	Persistent lumen defect with delayed antegrade flow
Type F		Filling defect accompanied by total coronary occlusion

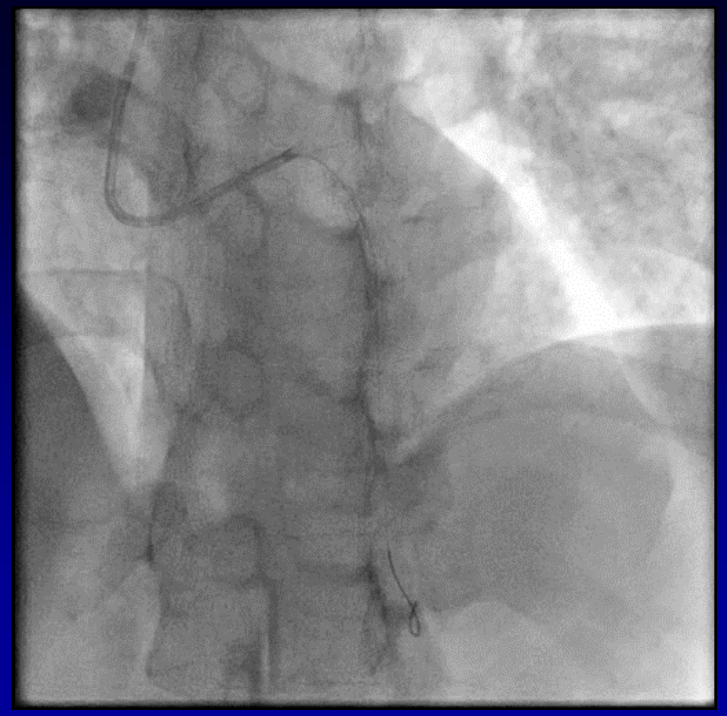

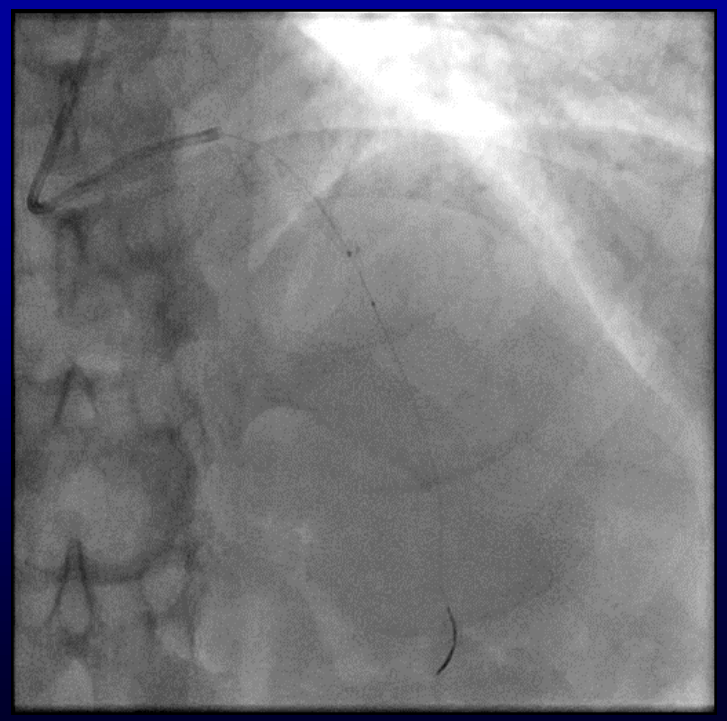

- Abrupt vessel closure of the LAD.
- IC vasodilators administered and no improvement in TIMI flow. Next, aspiration thrombectomy of LAD was performed using a Pronto catheter.

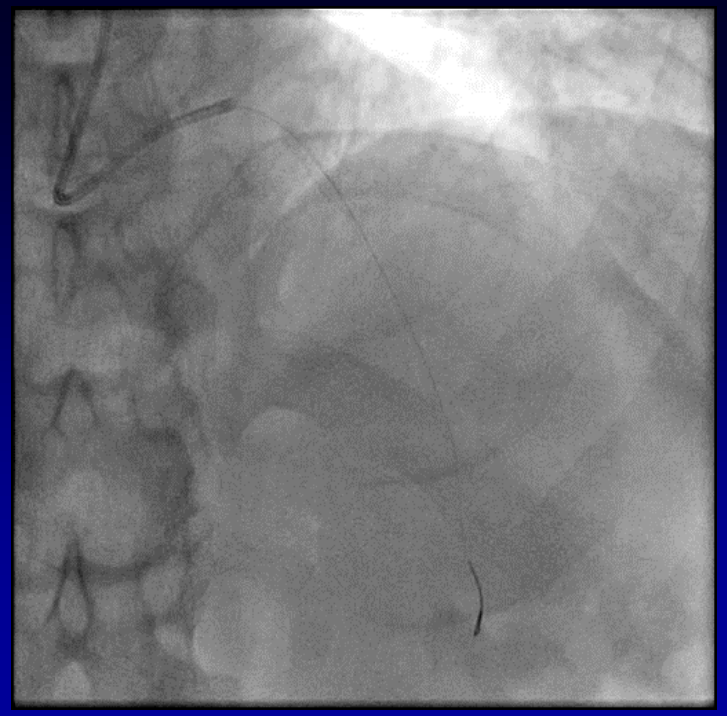

- Angiography of the LAD after aspiration thrombectomy showing no improvement in TIMI flow.

- Injection using a Pronto microcatheter. The distal vessel was patent with TIMI 3 flow,
- Due to preserved distal vessel TIMI 3 flow and no improvement in flow with IC vasodilators and aspiration thrombectomy, etiology is dissection.

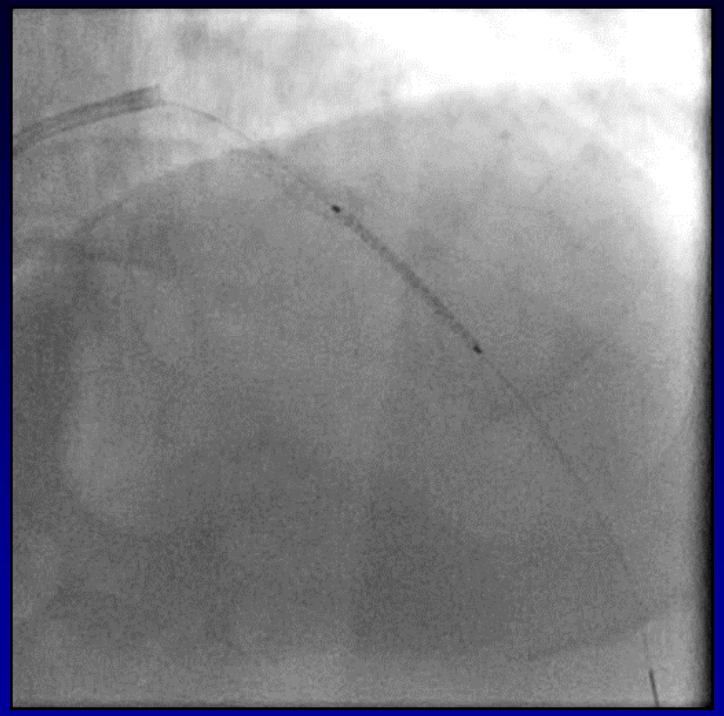

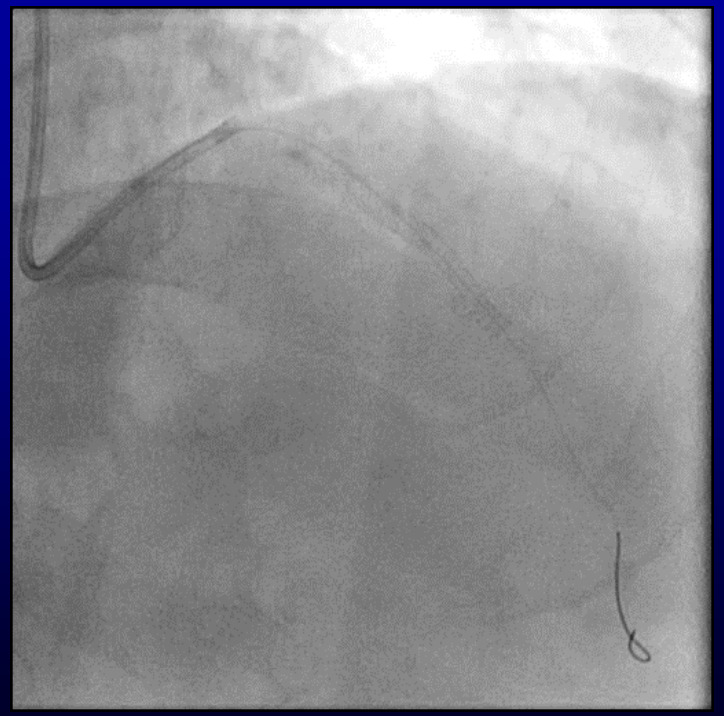

- Positioning of a Xience Alpine 3.5/23 mm stent in the mid LAD with slight overlap with the distal stent edge of the previously placed stent.

- Angiography of LAD after stent placement.

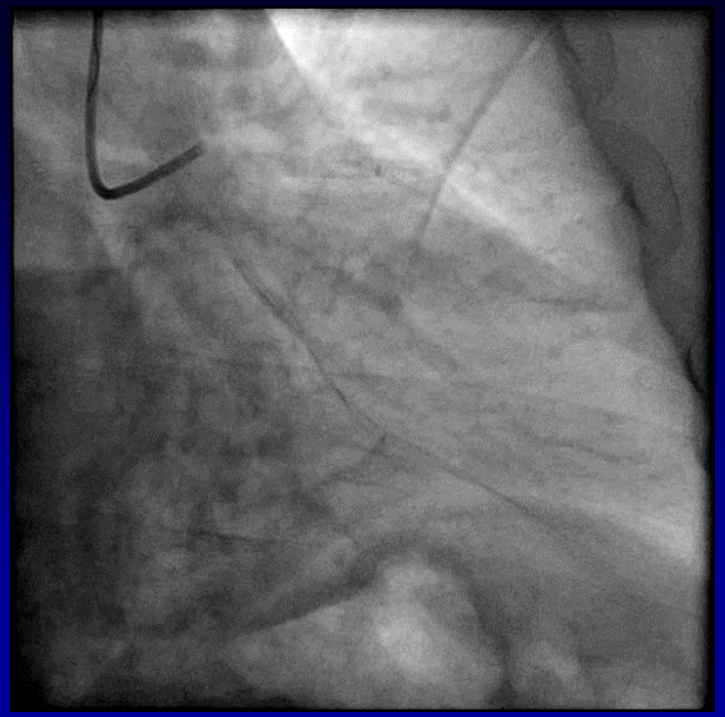

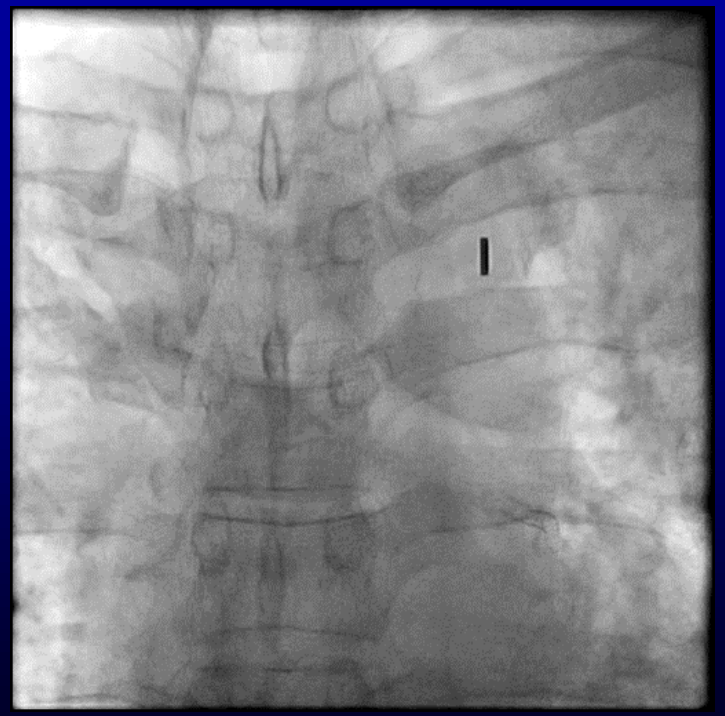

- Final angiography showing successful treatment of the LAD dissection with TIMI 3 flow.

- Patient remained hemodynamically unstable and an IABP was placed.
- Troponin-I peaked at 0.5 ng/mL

Type E Dissection: Case 2
Post-procedure EKG

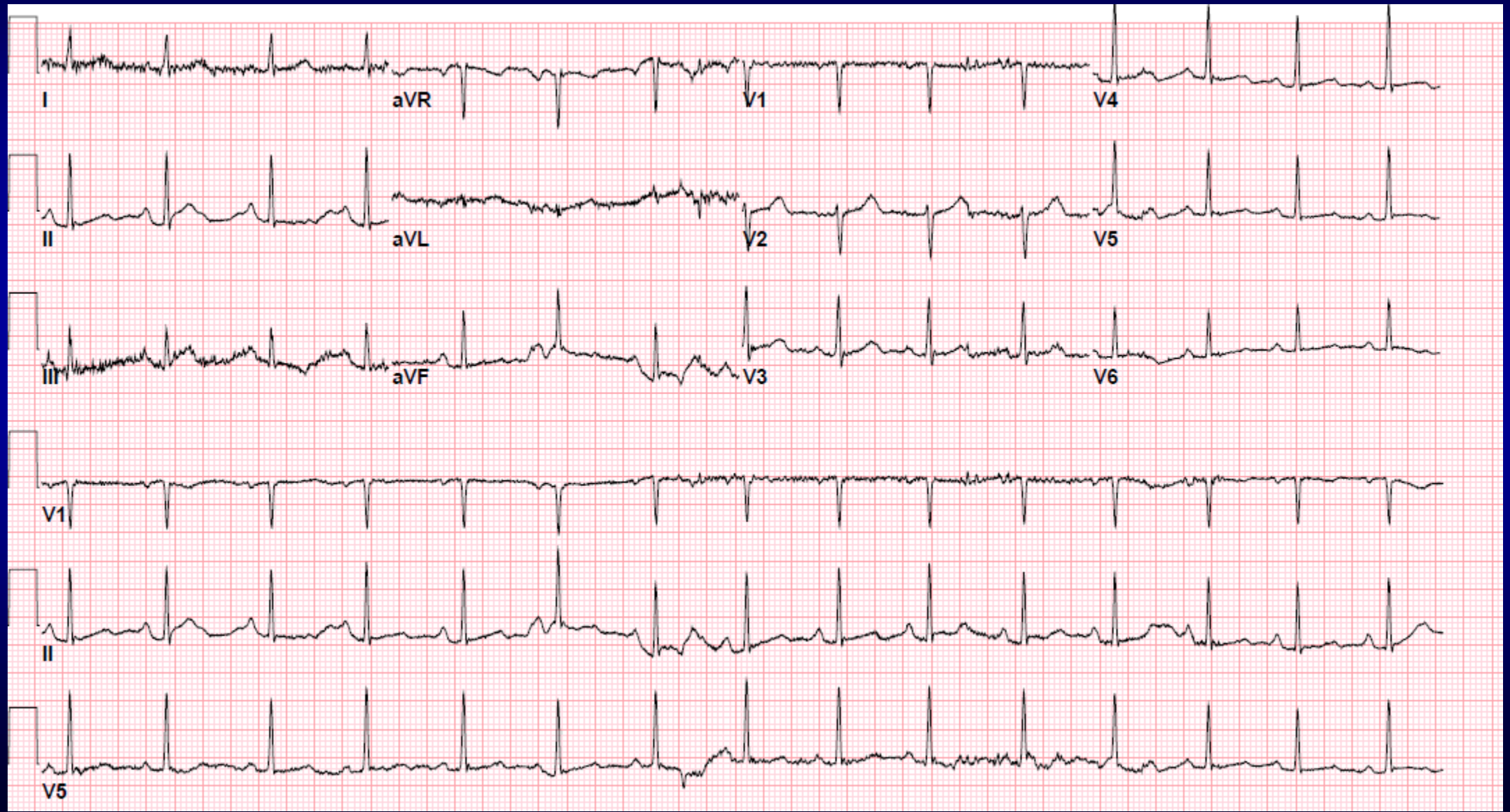

Case #6: 55 yrs M

Presentation - The patient presented with exertional chest tightness and SPECT-myocardial perfusion imaging showed moderate reversible inferior defect. A cardiac cath revealed 2 vessel cardiac artery disease: 70% mid LAD, 80% proximal RCA, 95% mid RCA with Syntax score 13. The patient underwent successful PCI of proximal RCA (Promus Premier 4x12mm) and mid RCA (Promus Premier 3.5x20mm). The patient returned for LAD cath +/- PCI due to ongoing symptoms.

Prior history - Hypertension, hyperlipidemia

Medications - Aspirin 81mg, Clopidogrel 75mg, Metoprolol 12.5mg, Simvastatin 5mg, Norvasc 5mg

A bifurcation lesion with medina (1,1,0) mid LAD

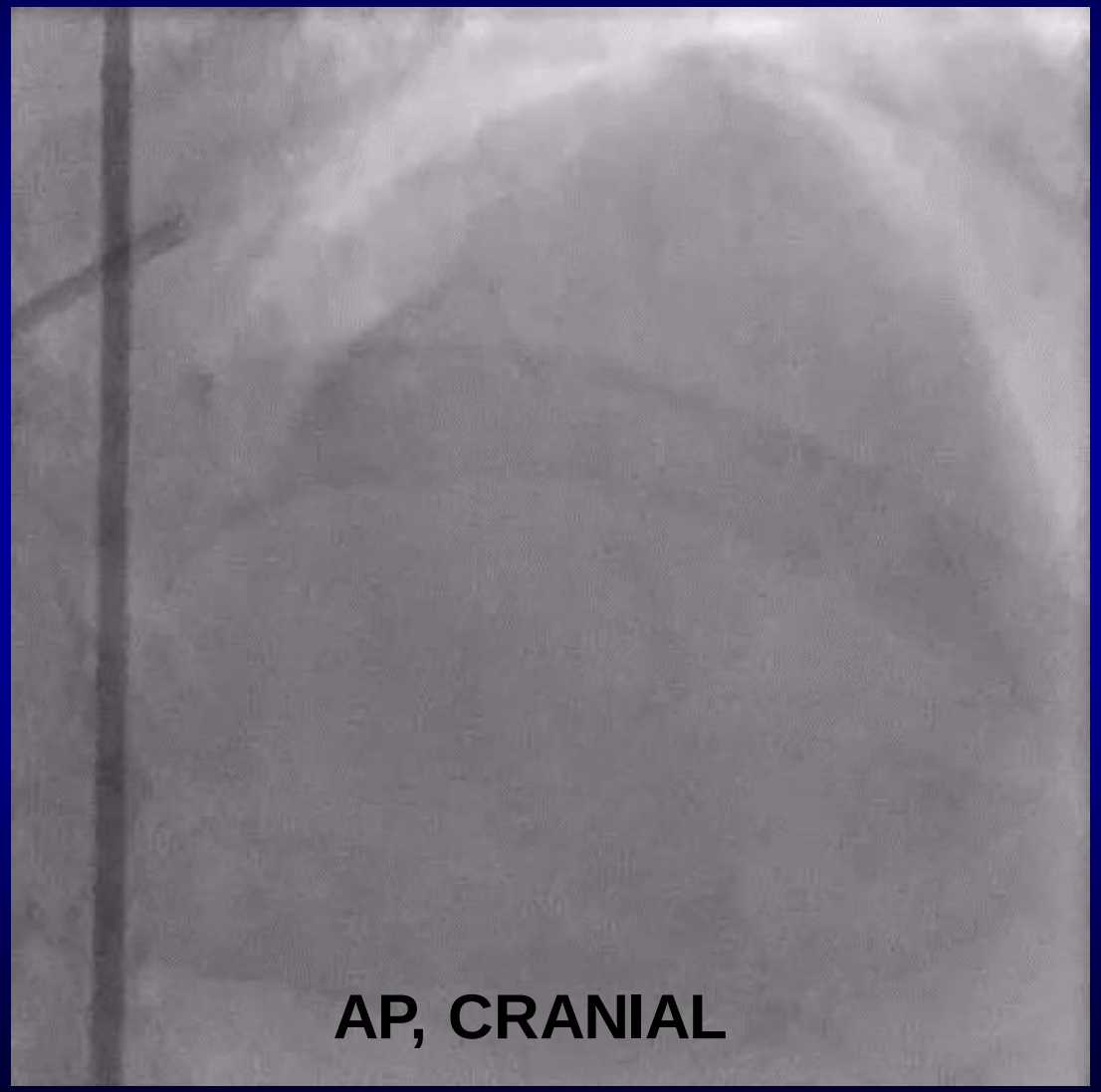

A bifurcation lesion with medina (1,1,0) mid LAD

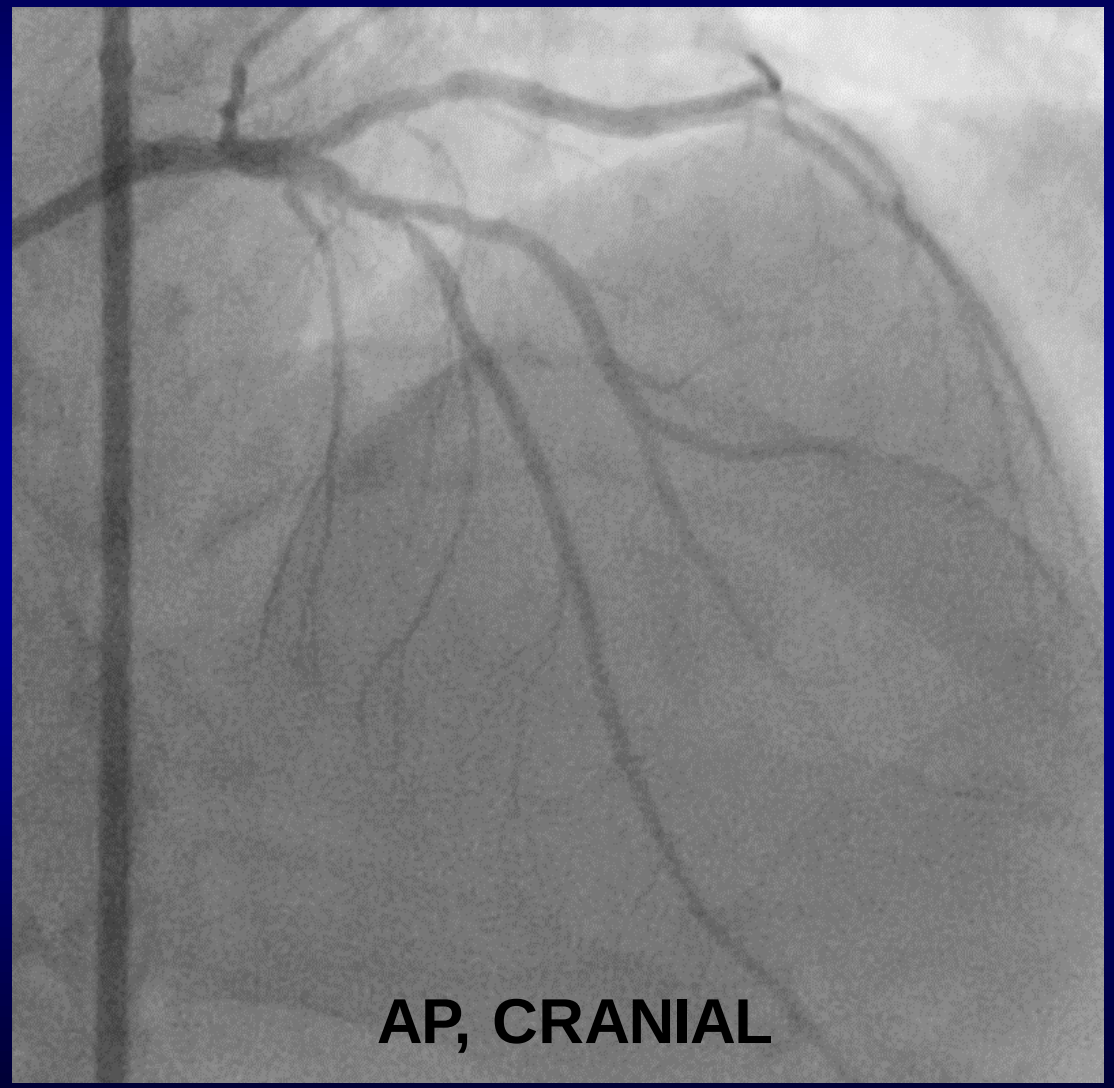

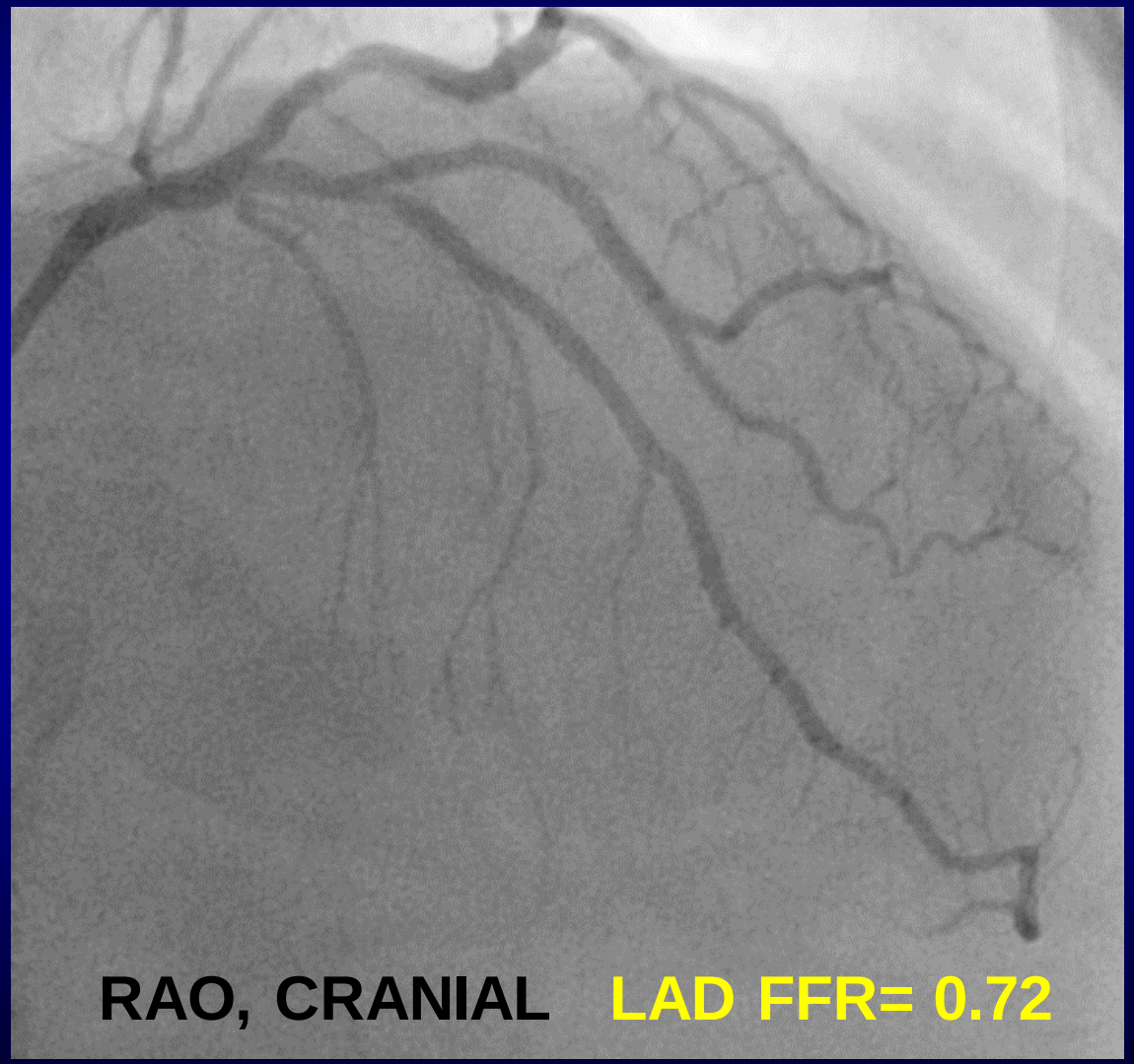


TREK NC 3.0x15mm at 16atm

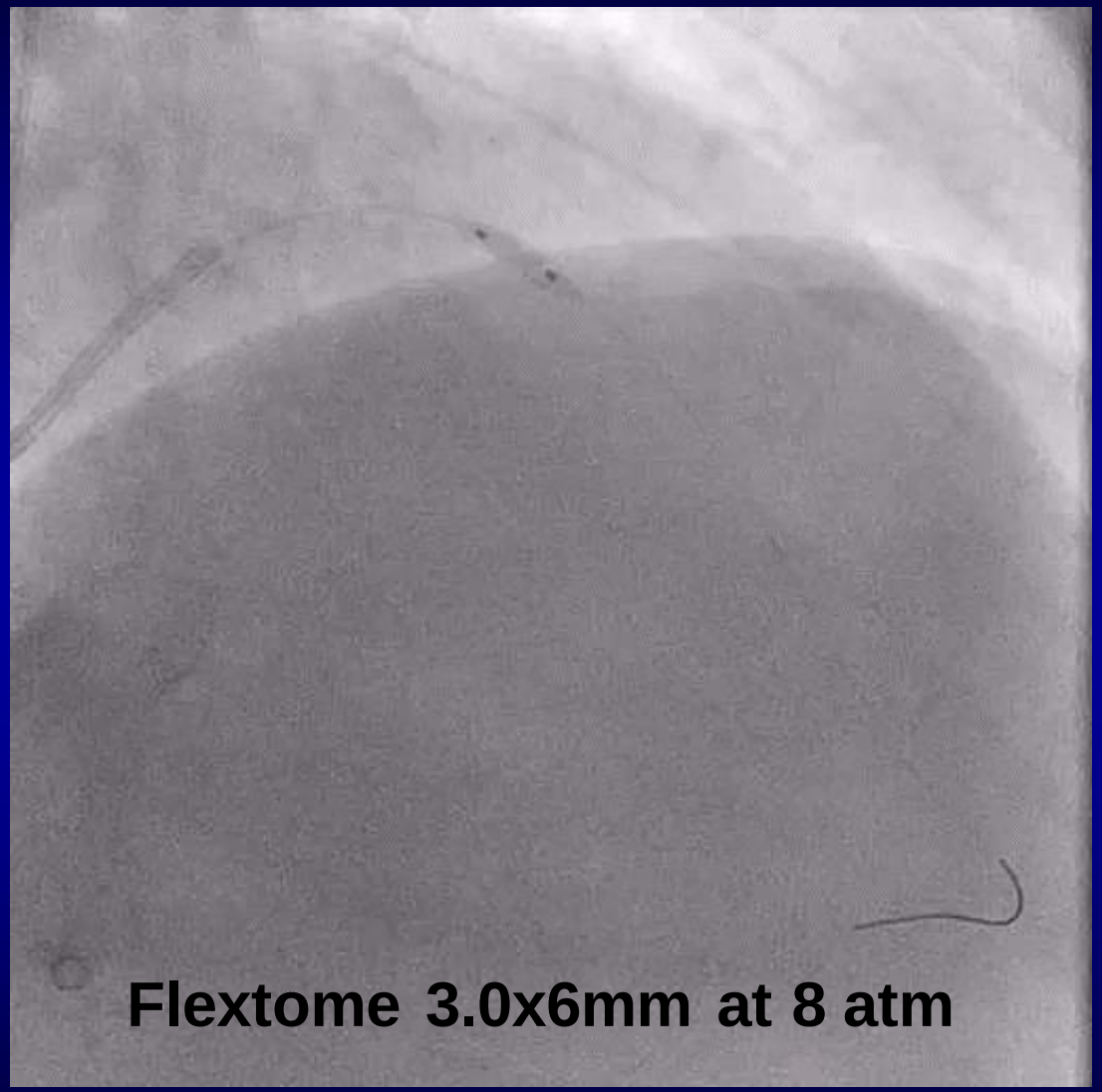
Flextome 3.0x6mm at 8 atm

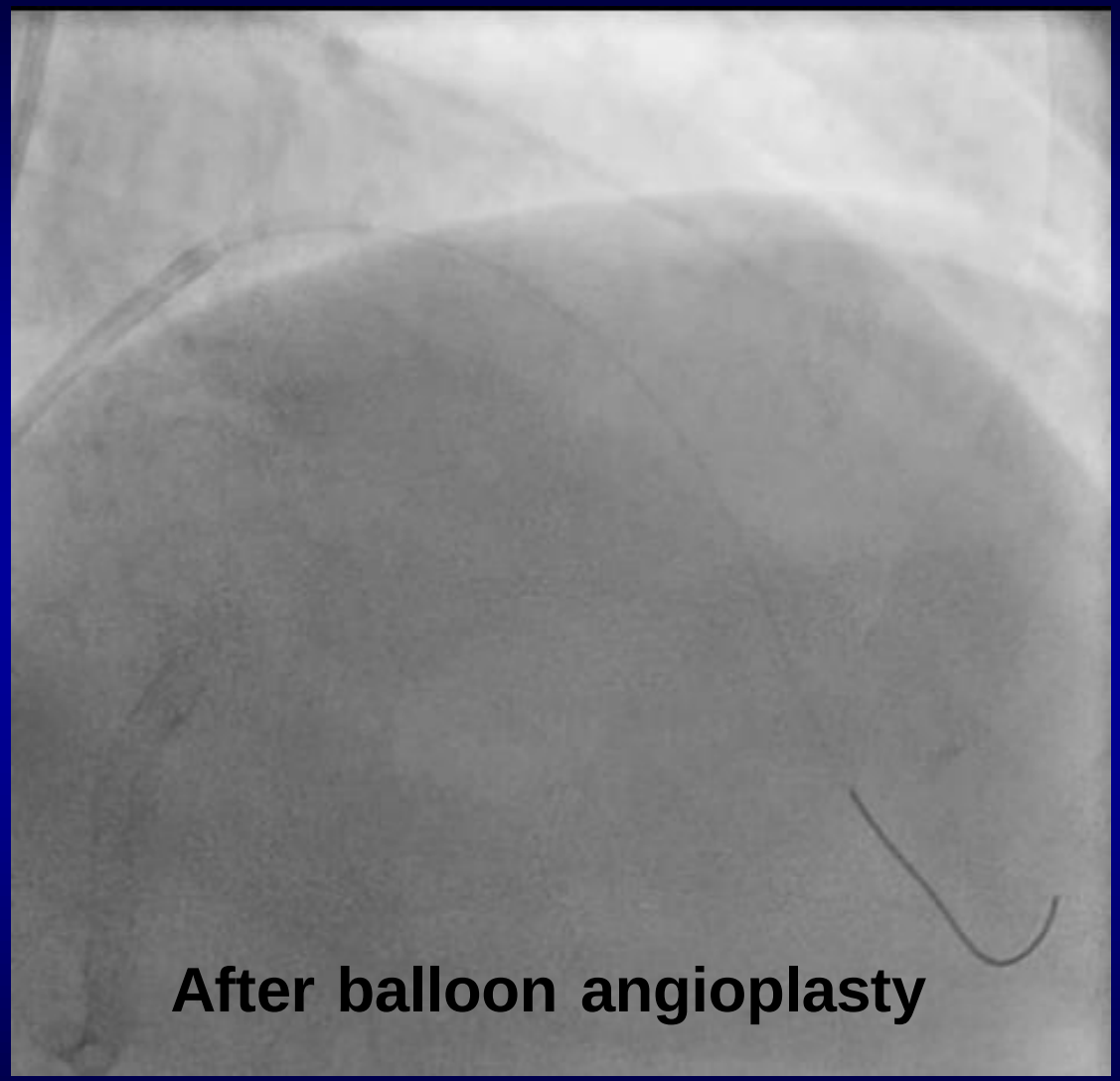
After balloon angioplasty

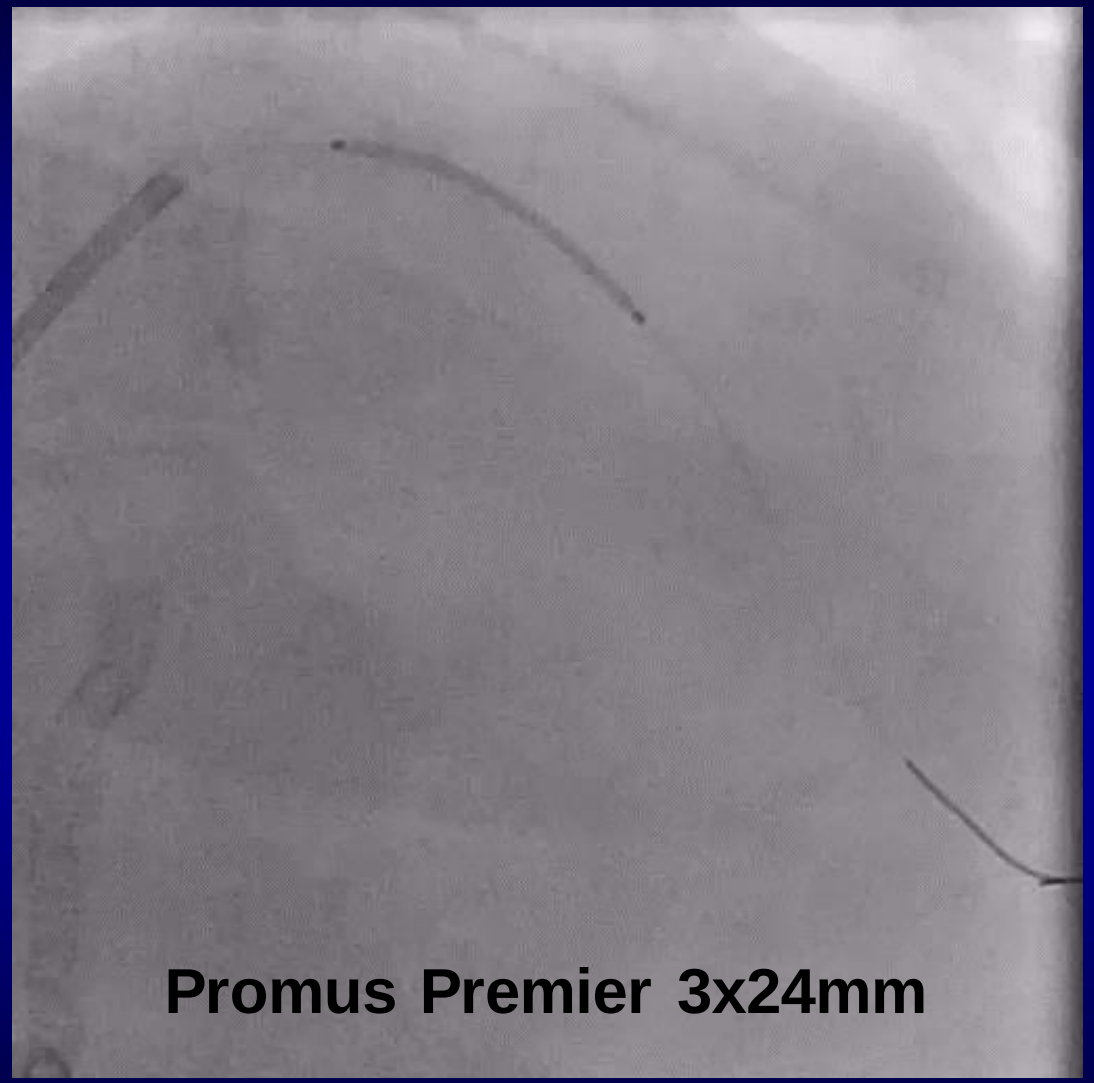
Promus Premier 3x24mm

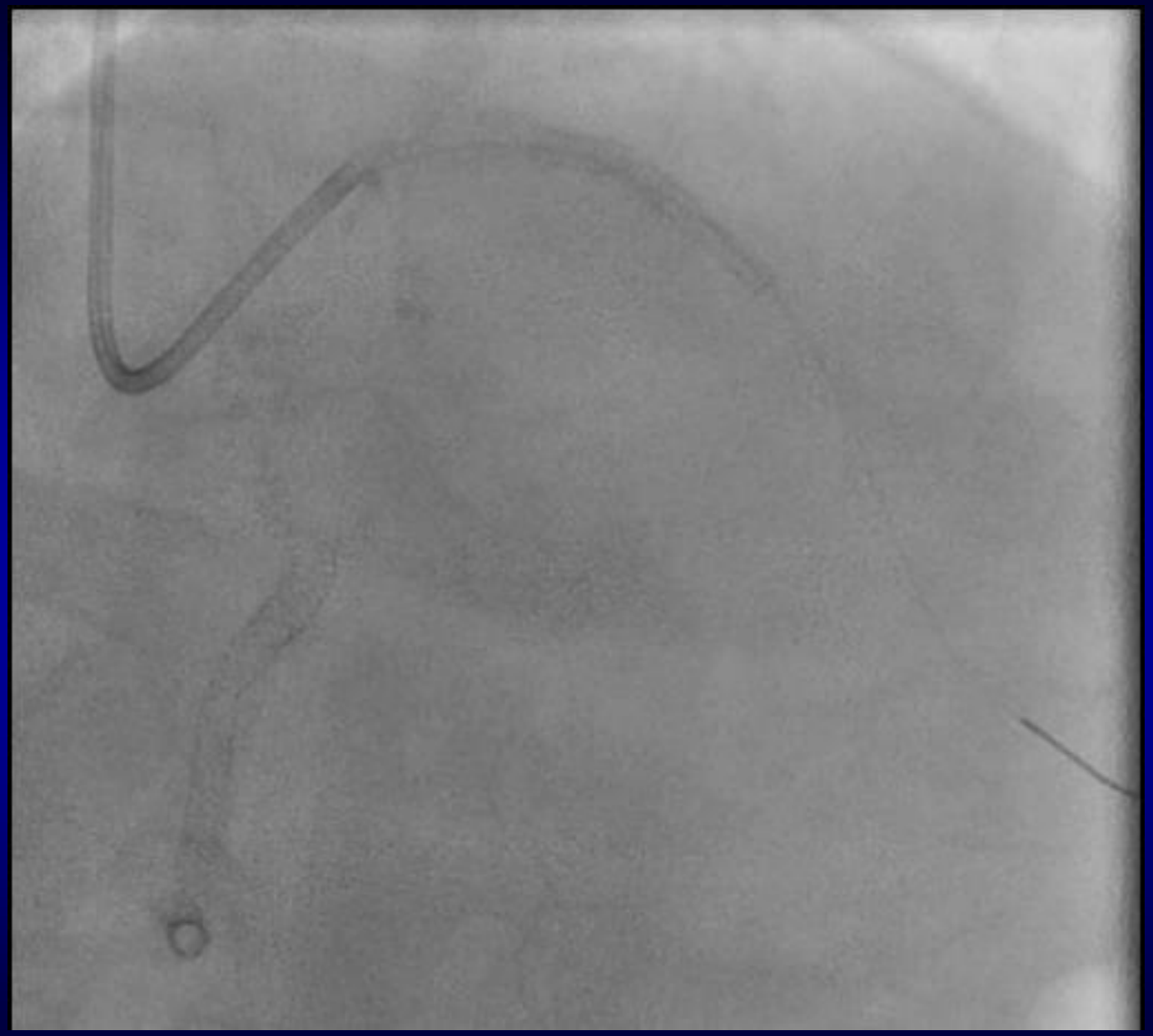

Side branch showed TIMI 1 flow.

?

Why I Lost This Side Branch and What I Should Have Done Instead

Bifurcaid App

Bifurcaid App





Free Download

Download on the App Store

GET IT ON Google Play

Why I Lost This Side Branch and What I Should Have Done

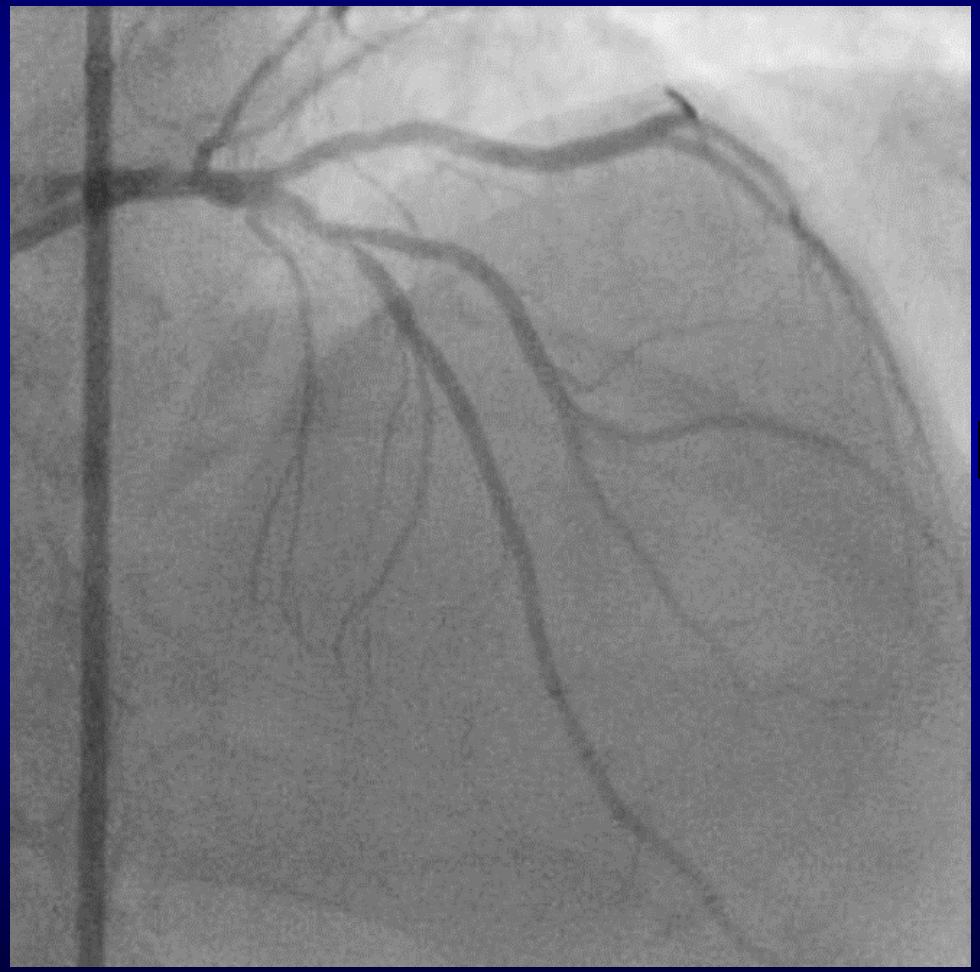



BIFURCAID

Mount Sinai

NON - LM

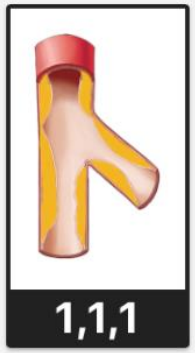
1,1,1

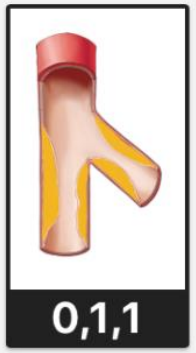
0,1,1

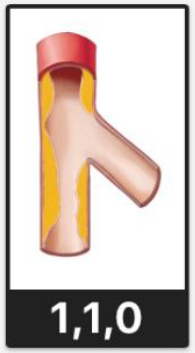
1,1,0

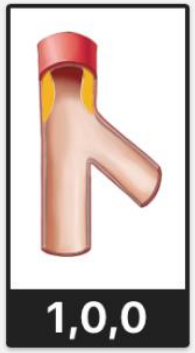
1,0,0

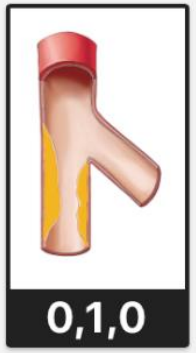
0,1,0

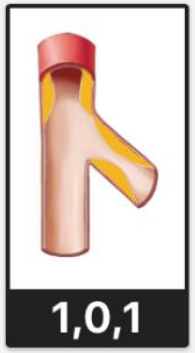
1,0,1

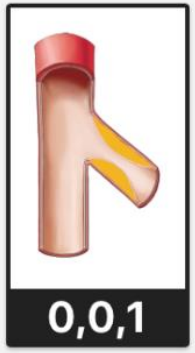
0,0,1

BIFURCAID

Mount Sinai

NON - LM > 110

Side Branch Diameter (mm)

< 1.5

1.5 - < 2.25

2.25 - < 2.75

> 2.75

BIFURCAID

Mount Sinai

NON - LM > 110 > 2.25 - < 2.75

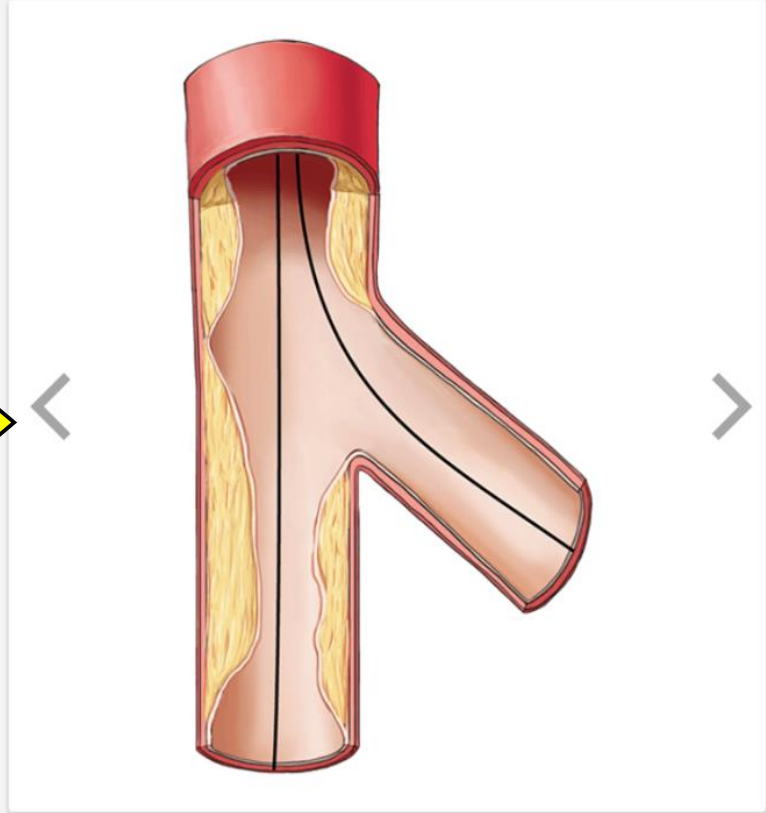

Wire MV, wire SB .

I should have wired SB.

BASICS

BACK

Inability to pass balloon in SB

- Use lowest profile balloon (1.20 or 1.25 mm, 6-8 mm in length)
- Rewire SB and access SB through a different stent strut
- Accessing SB through a different stent strut.
- POT to open struts of MB into SB.
- Use of microcatheter like Corsair (can cause damage to MV stent strut)

Instructional basics section within BifurcAID covers general topics and common hurdles.

BASICS

BACK

Difficult SB Re wiring after MV stenting

- Using hydrophilic wire
- Repeating POT at higher pressure or with a bigger balloon
- During SB rewiring, the same wire that was used initially to wire the SB is pulled back into the guide and not all the way out of the body prior to MV stenting and the same wire is used to recross. A new wire can be used if unable to recross.
- Wire Swap: The wire from the MV can be pulled back and can be

T-stenting And Protrusion

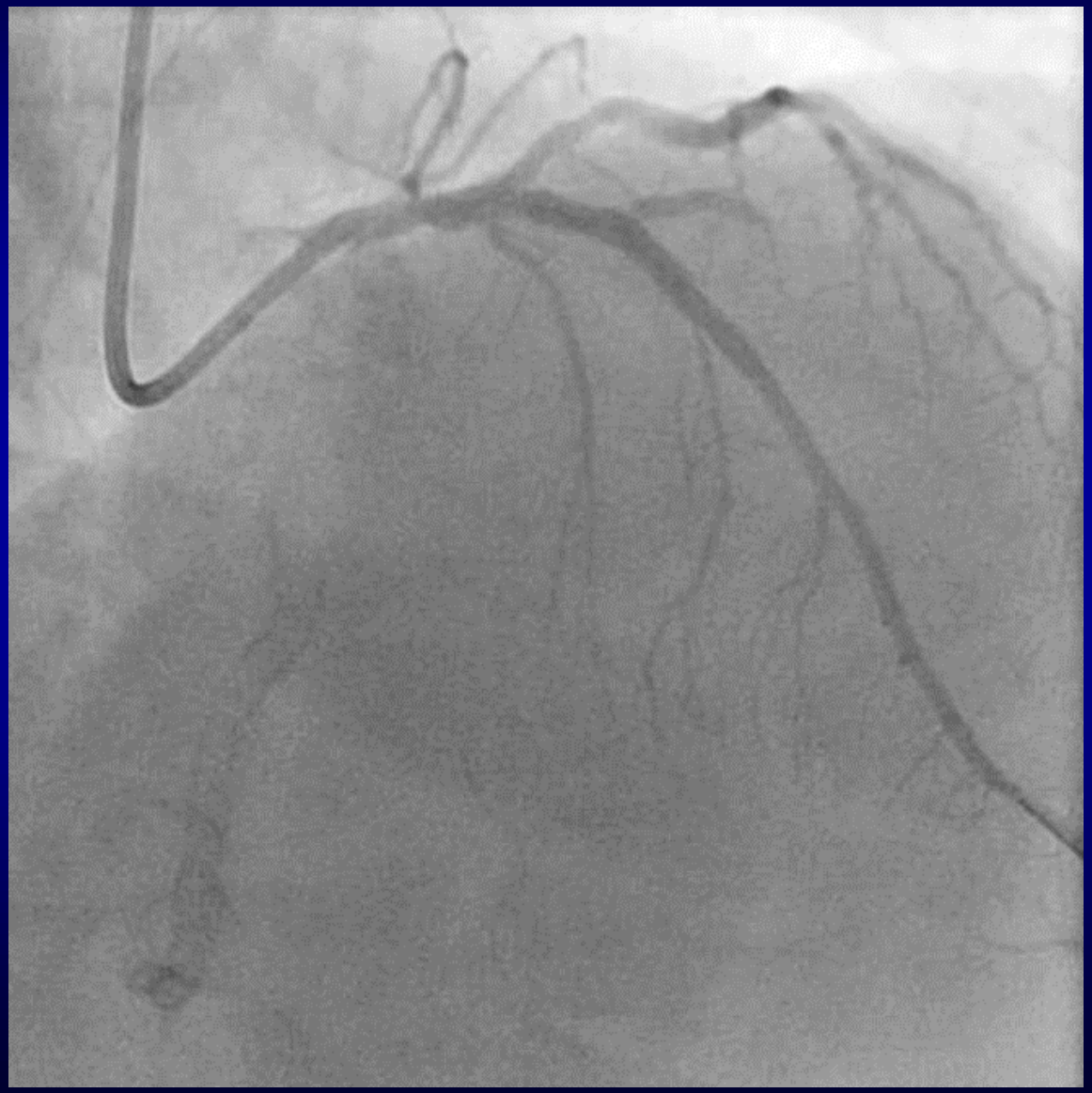

T-stenting And Protrusion

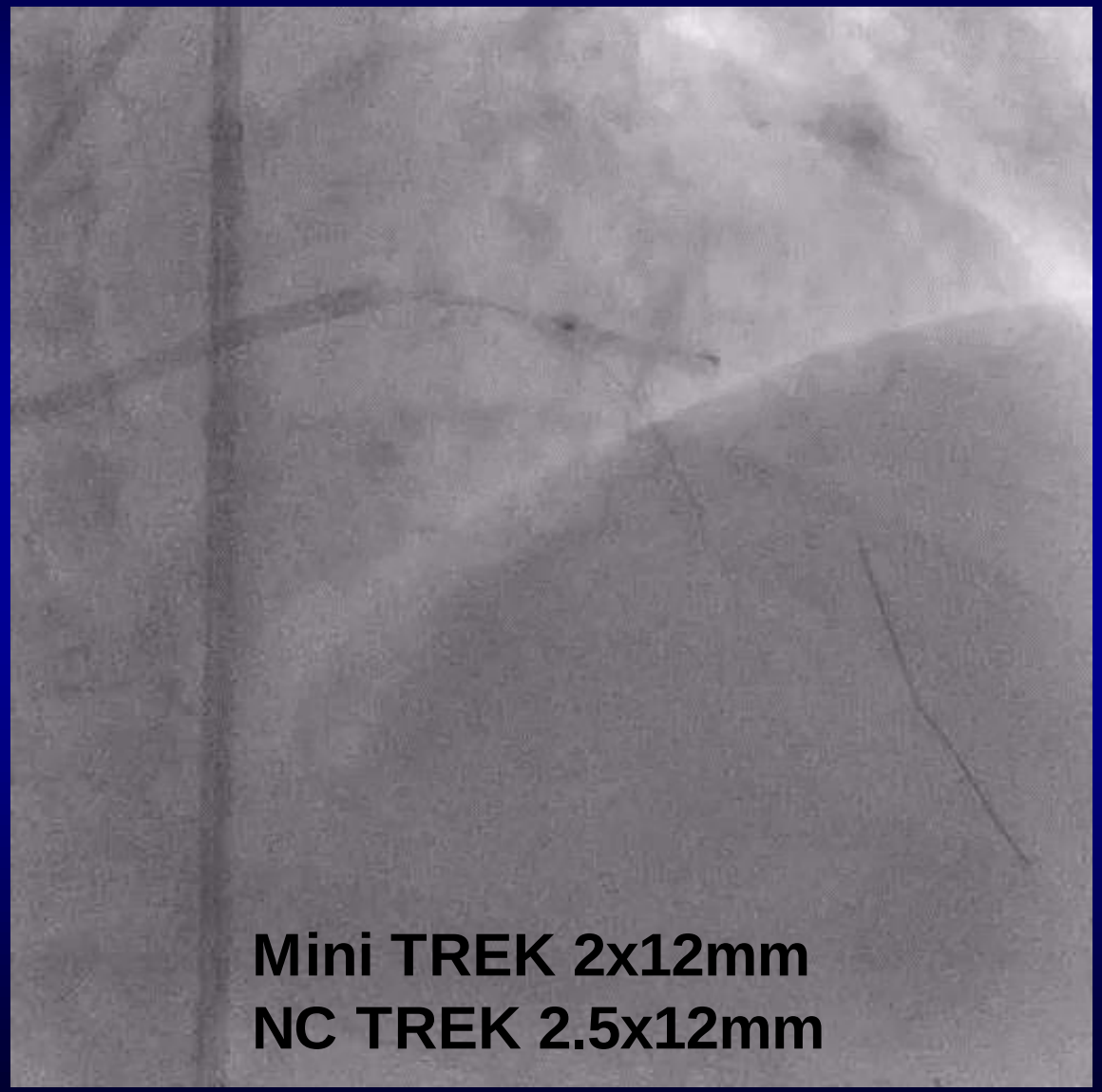

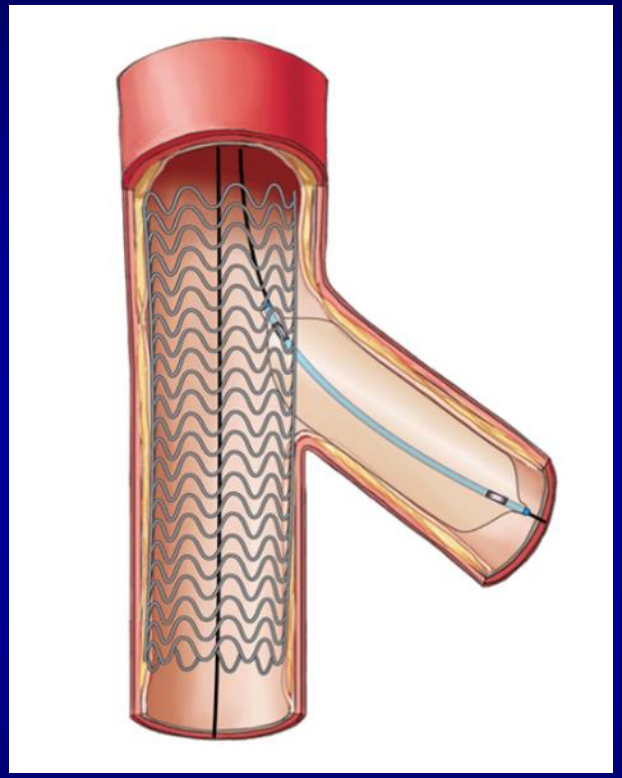

Dilate SB with compliant balloon

T-stenting And Protrusion

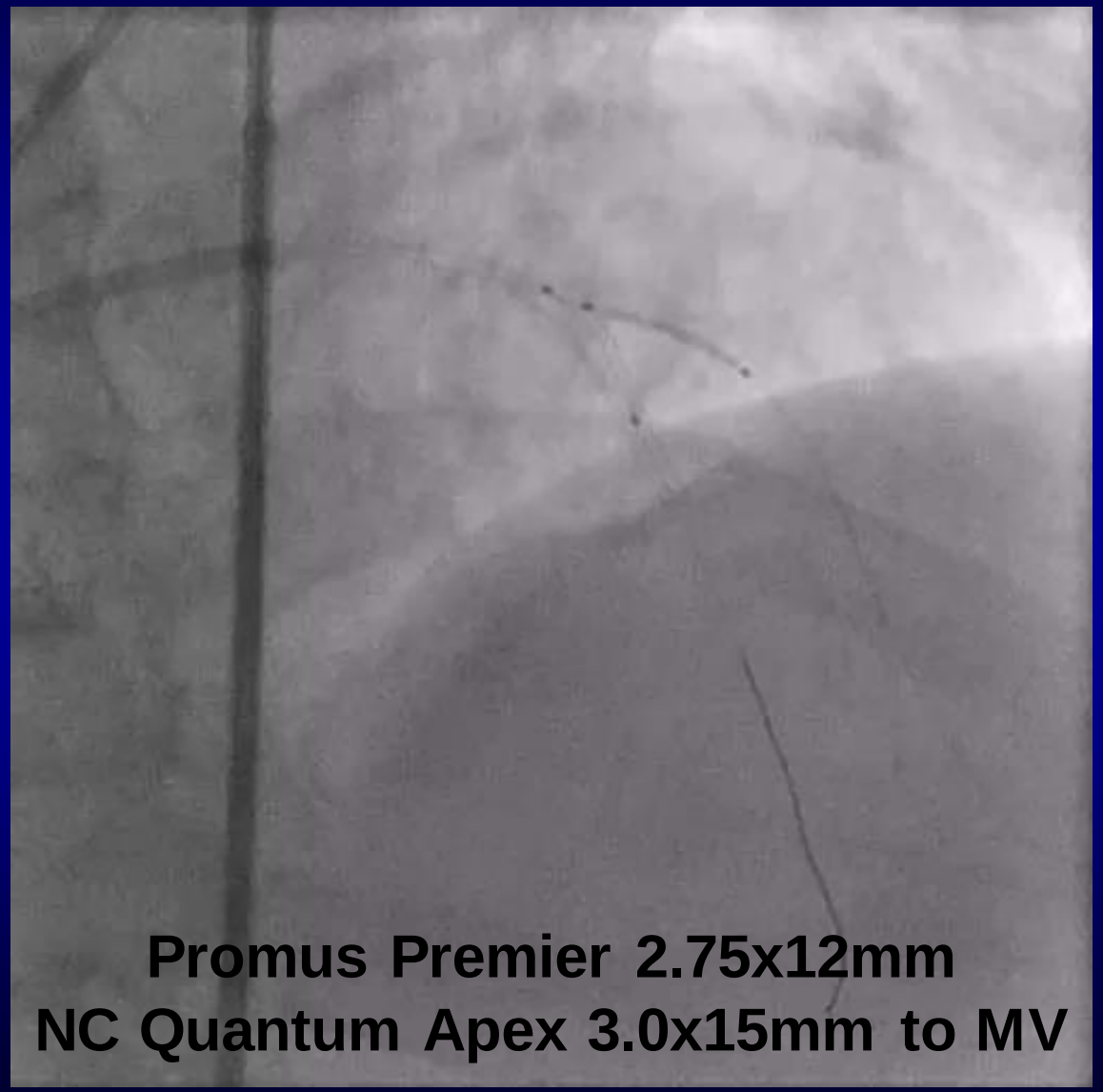

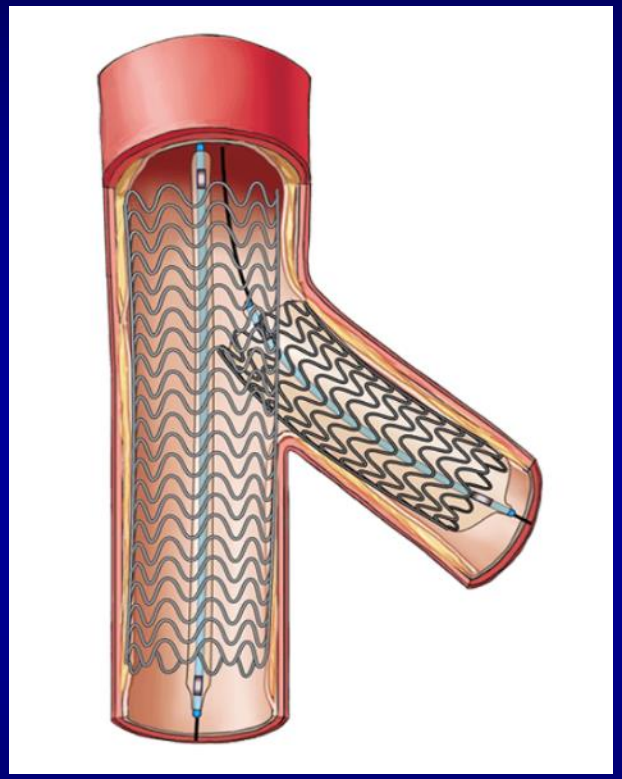

- Advance stent to SB (protrude into MV by 1mm).
- Advance balloon to MV (NC balloon).

T-stenting And Protrusion

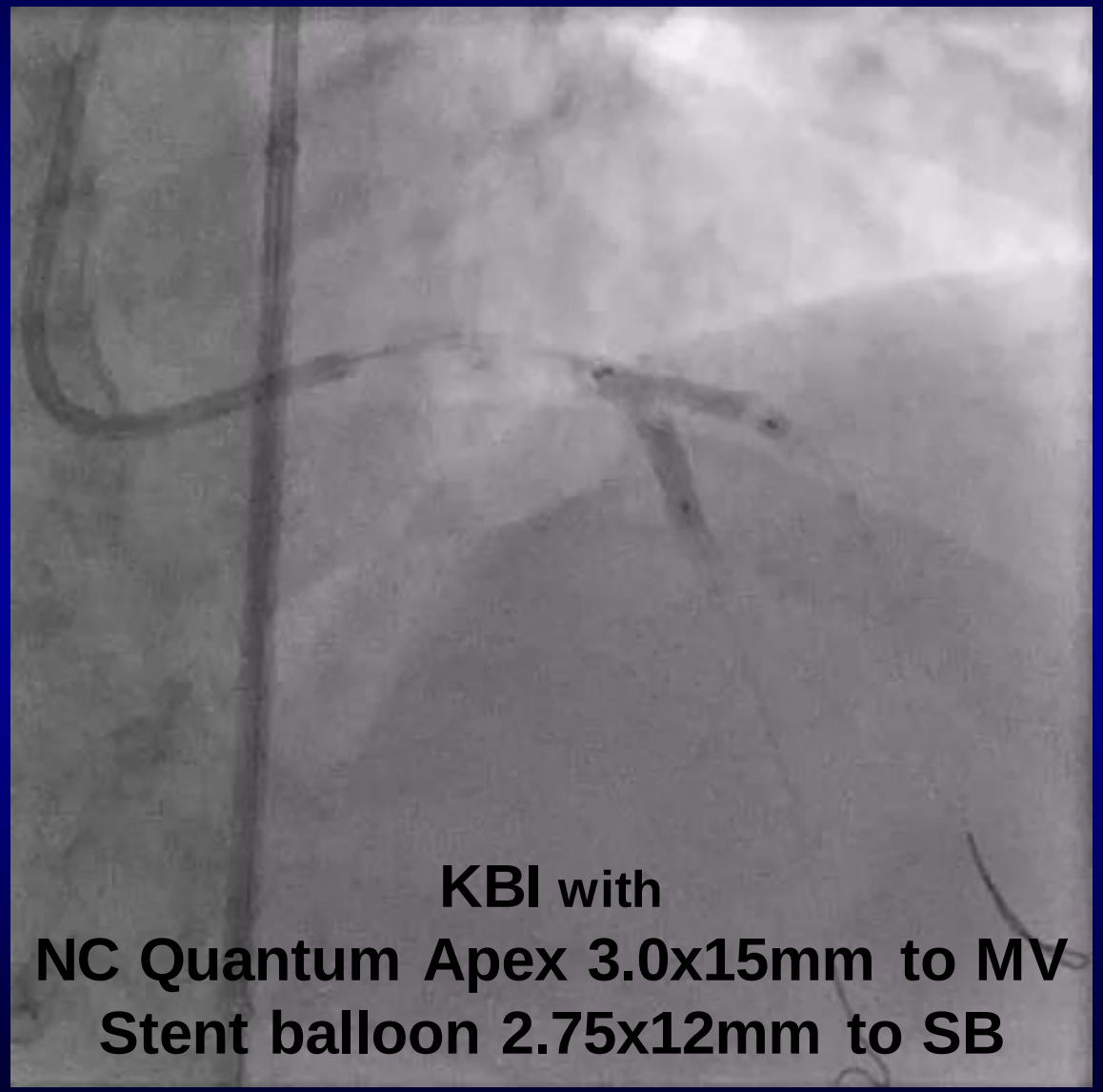

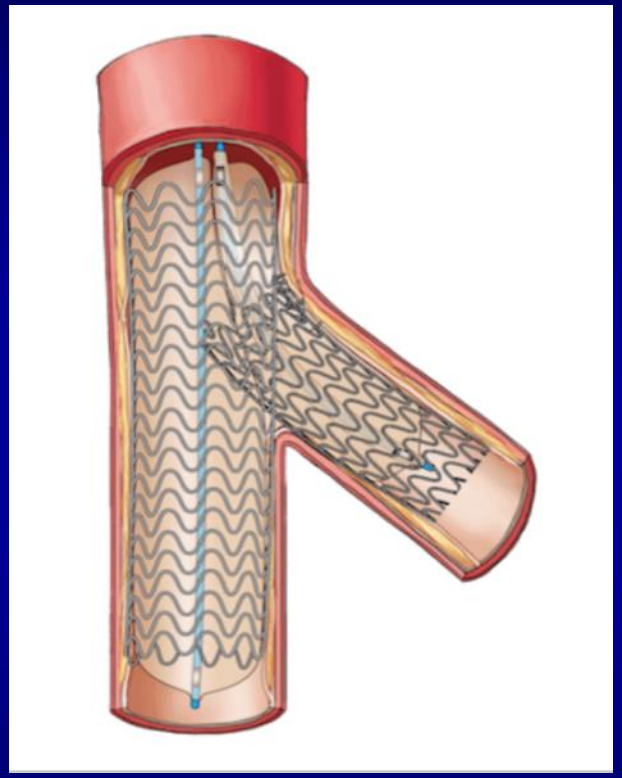

Perform KBI.

T-stenting And Protrusion

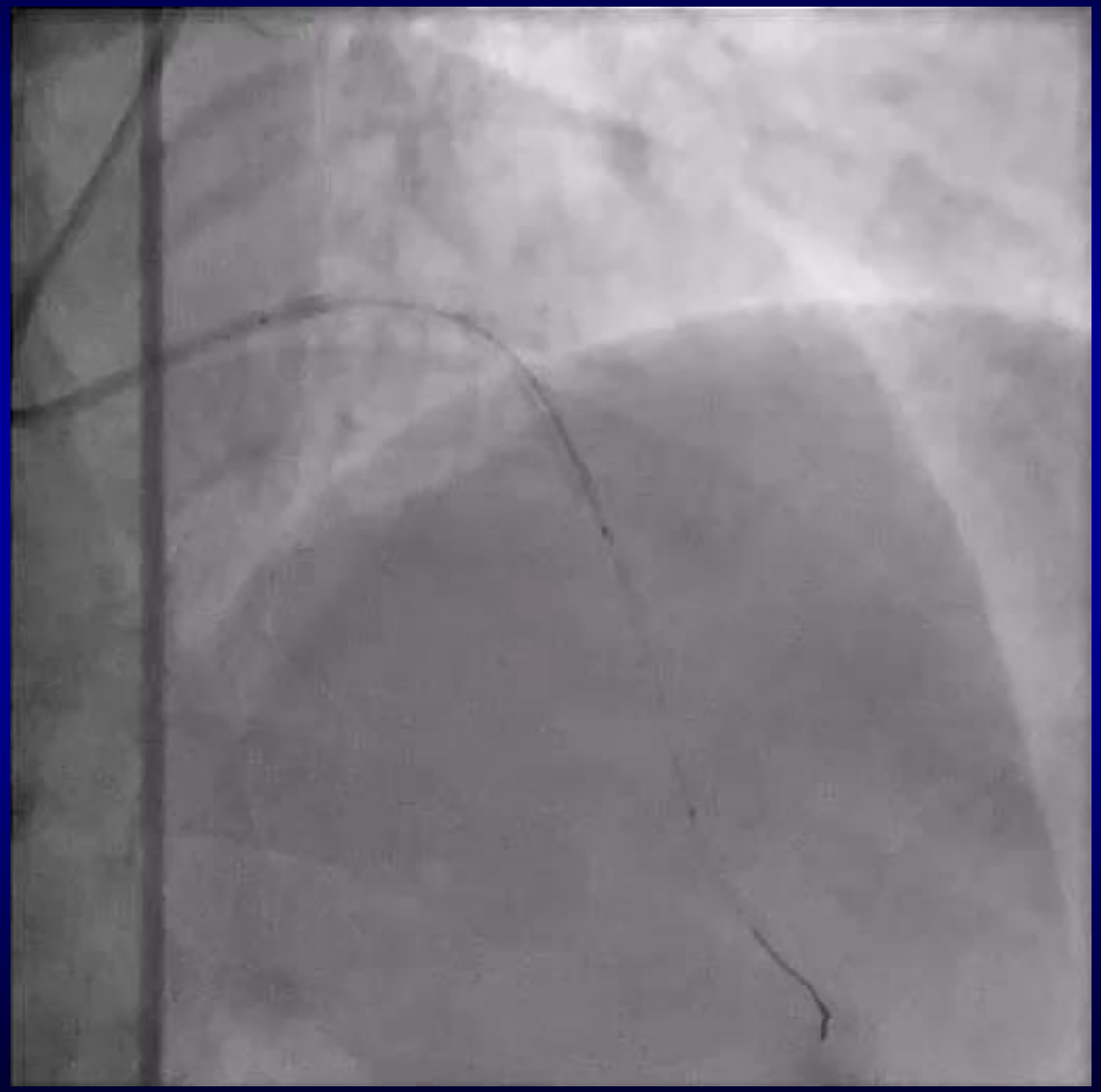

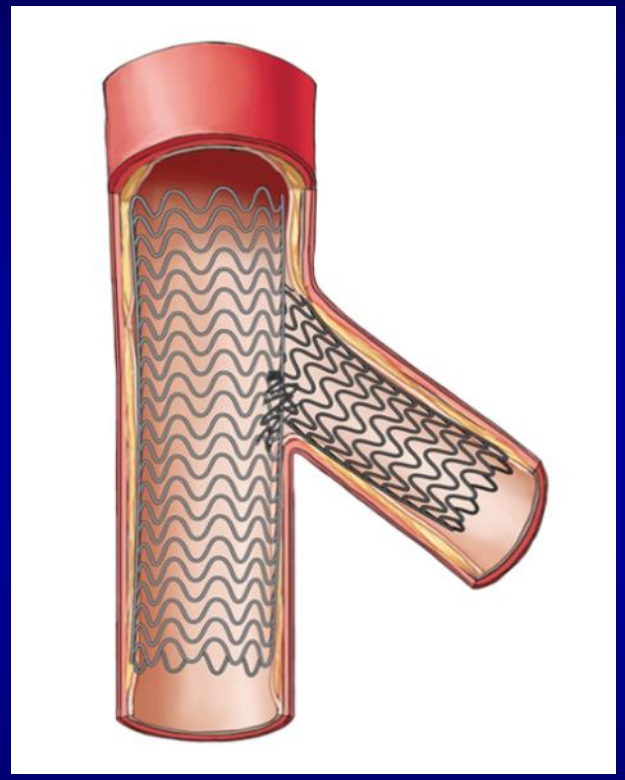

Final angiogram to rule out distal edge dissection.

Final coronary angiography

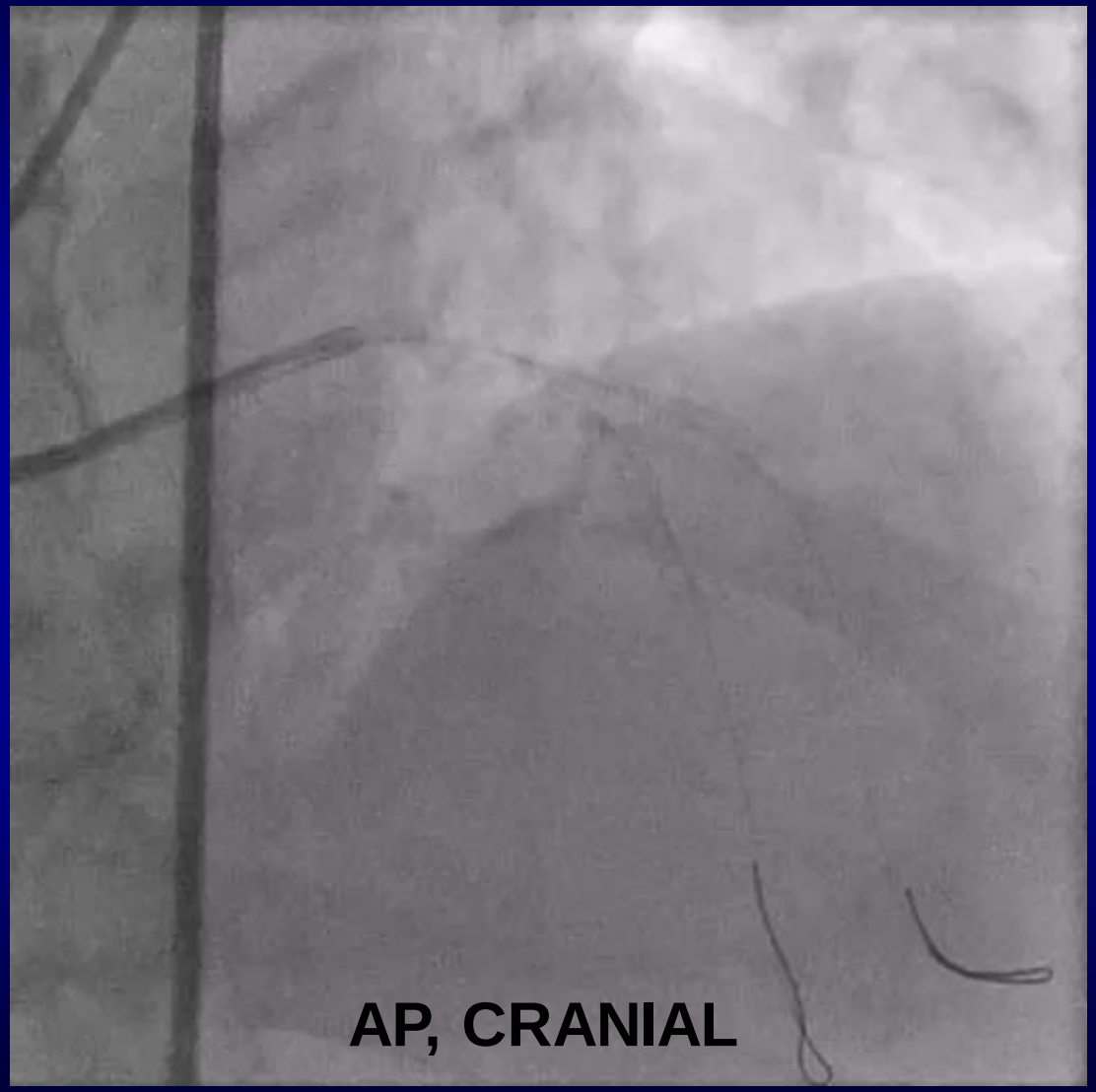

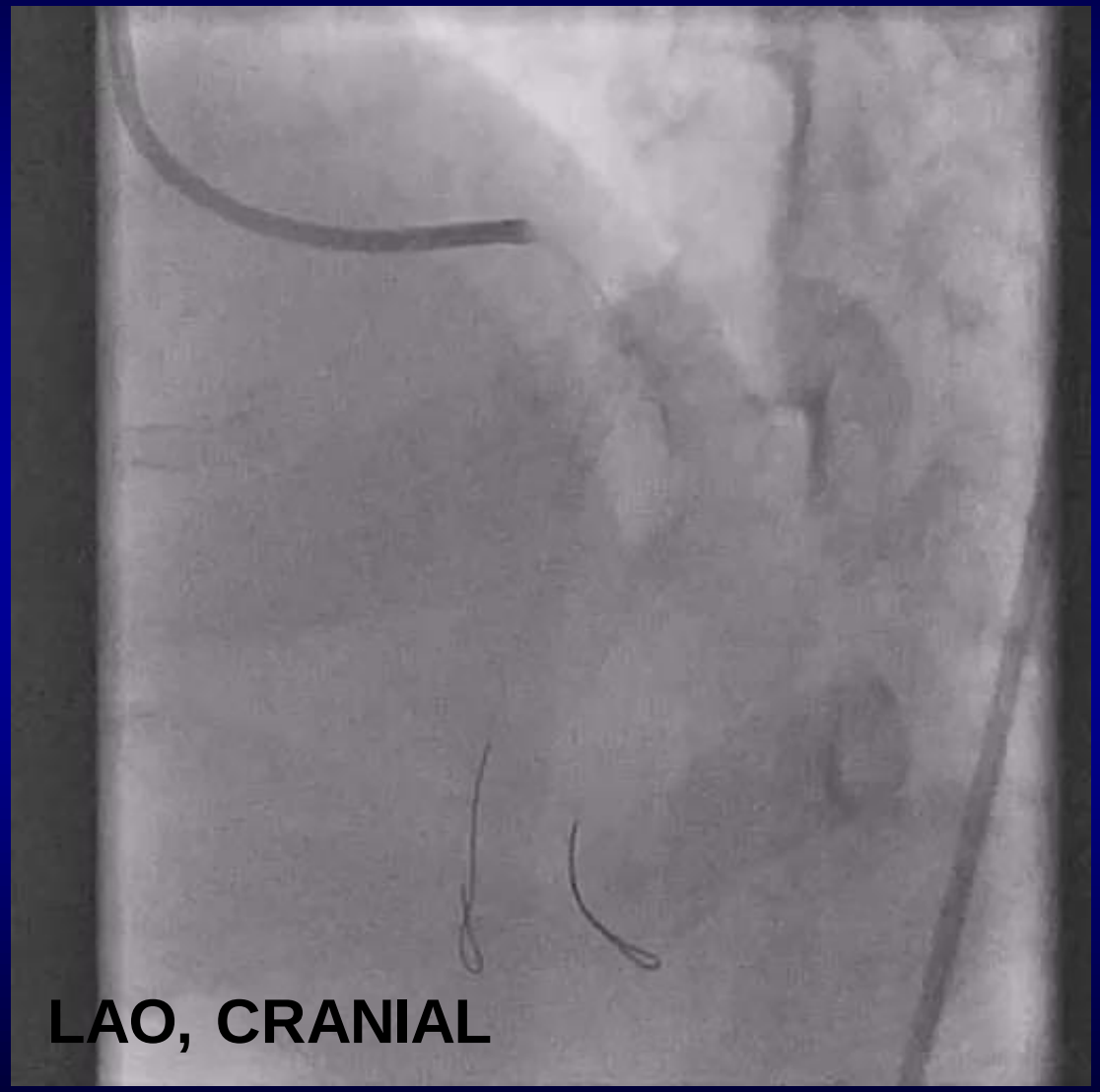

Conclusion:
How to Anticipate & Prevent Complications?

- **Anticipate** the problems; dissections coronary or aortic, slow-flow, damped tracings of ostial lesion, air embolism, thrombus formations, coronary/wire perforations, acute closure, vascular perforations
- **Prepare** to tackle the complications with liberal use of vasopressors, maintain airway, call for senior attending
- Have appropriate **equipment** to tackle the complications especially; Covered Stent, Coils, Pericardiocentesis tray, IABP, Impella, ECMO, CTS

PCI Complications: MSH vs. NY State Hospitals

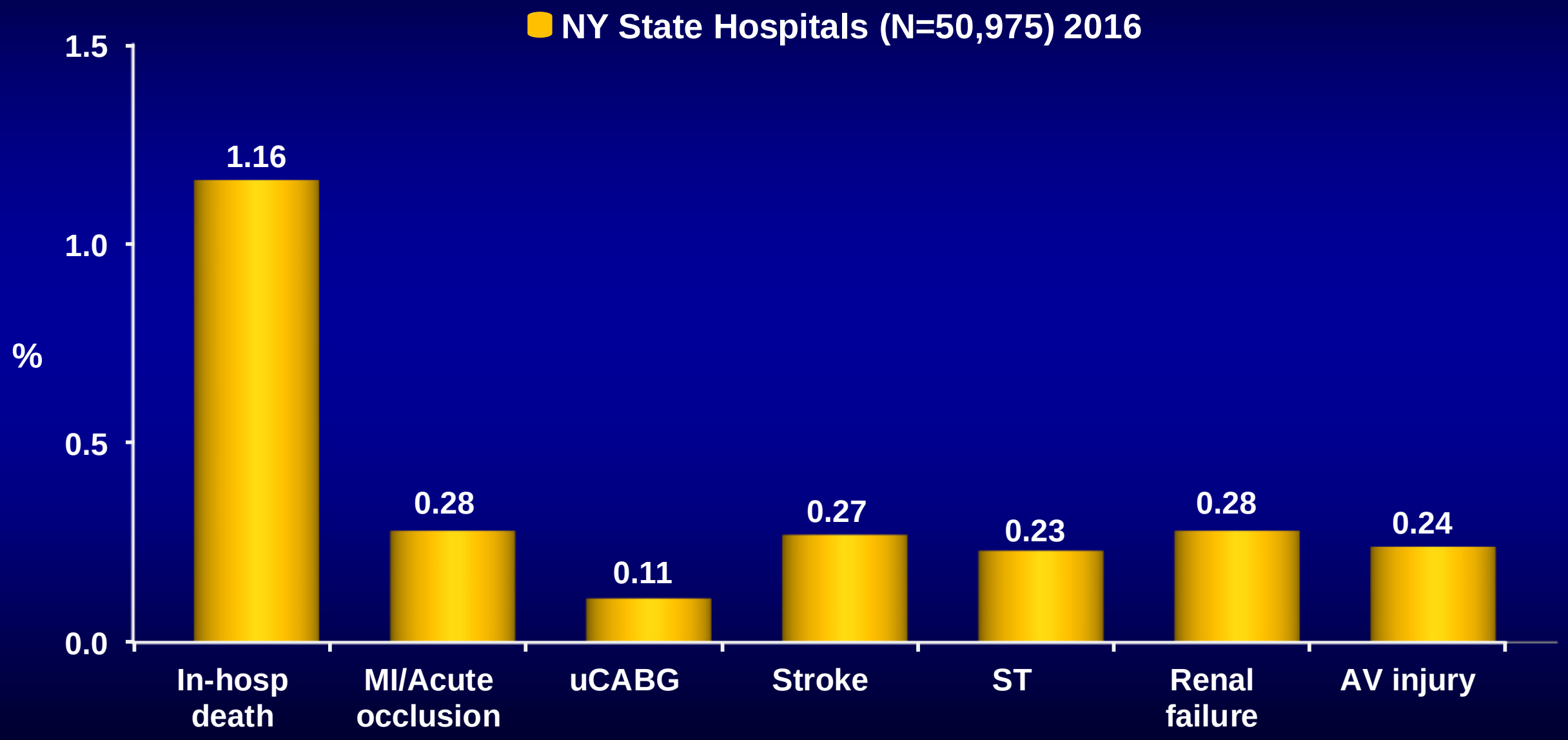

PCI Complications: MSH vs. NY State Hospitals

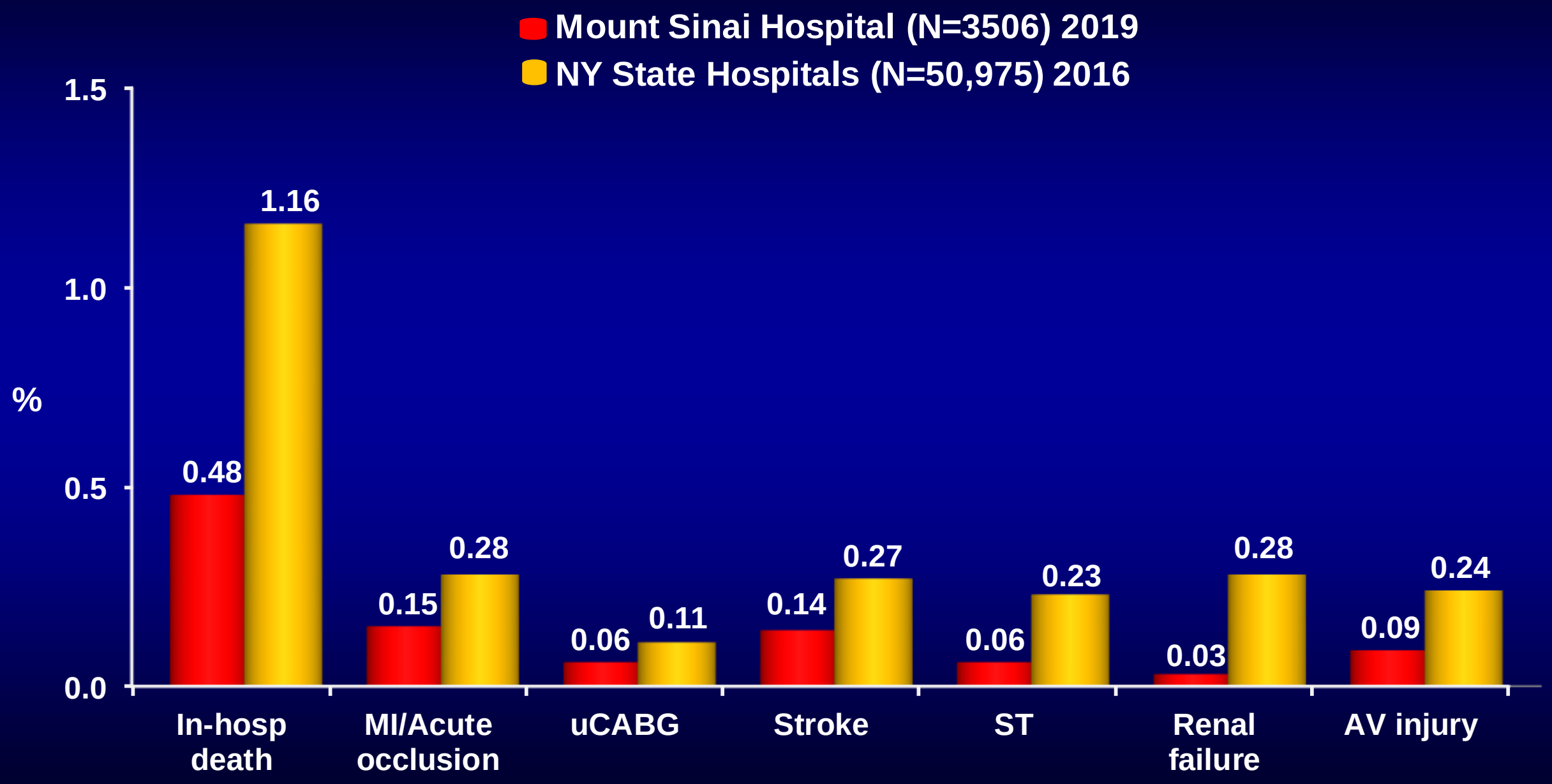

PCI Complications: MSH vs. ACC-NCDR Hospitals 2018-19

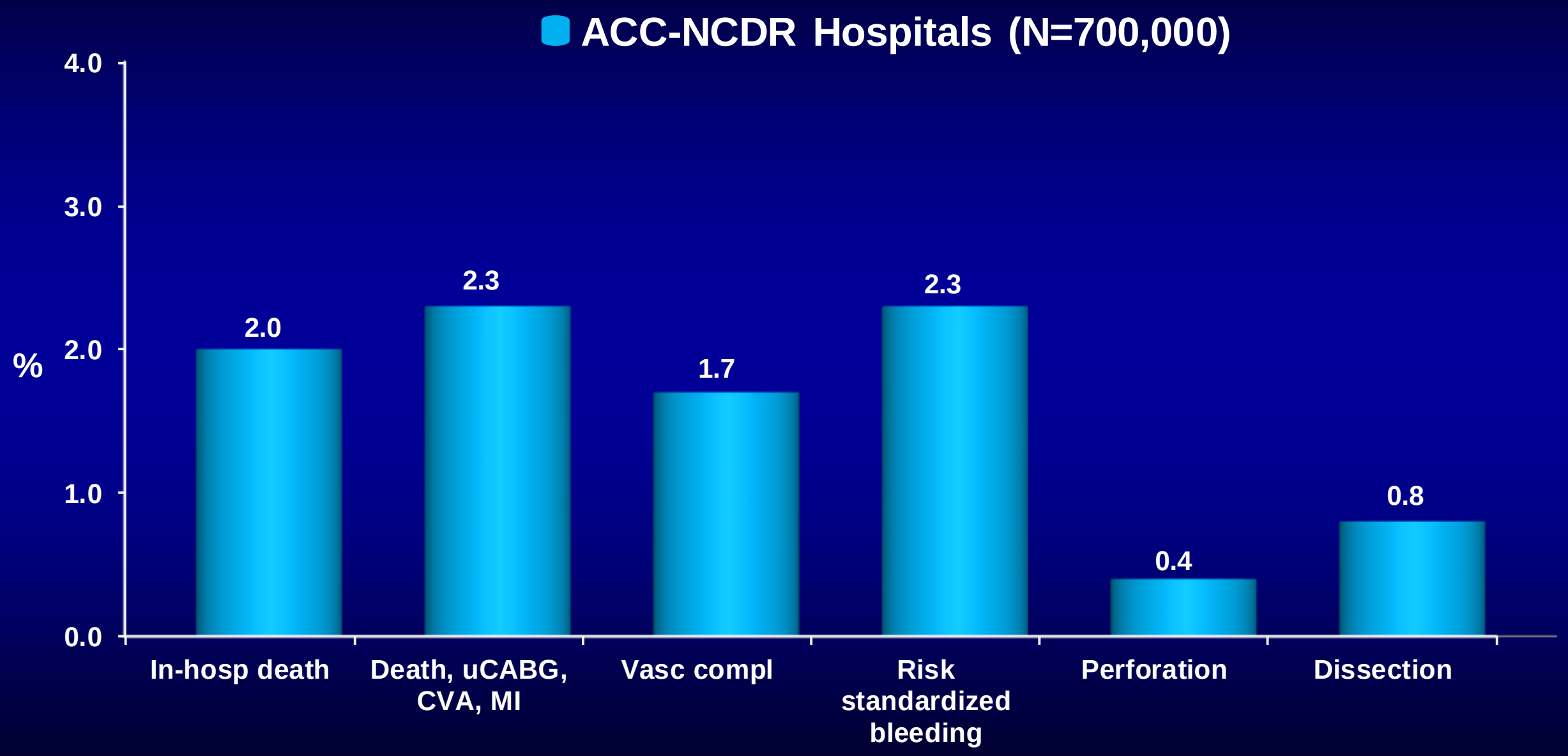

PCI Complications: MSH vs. ACC-NCDR Hospitals 2018-19

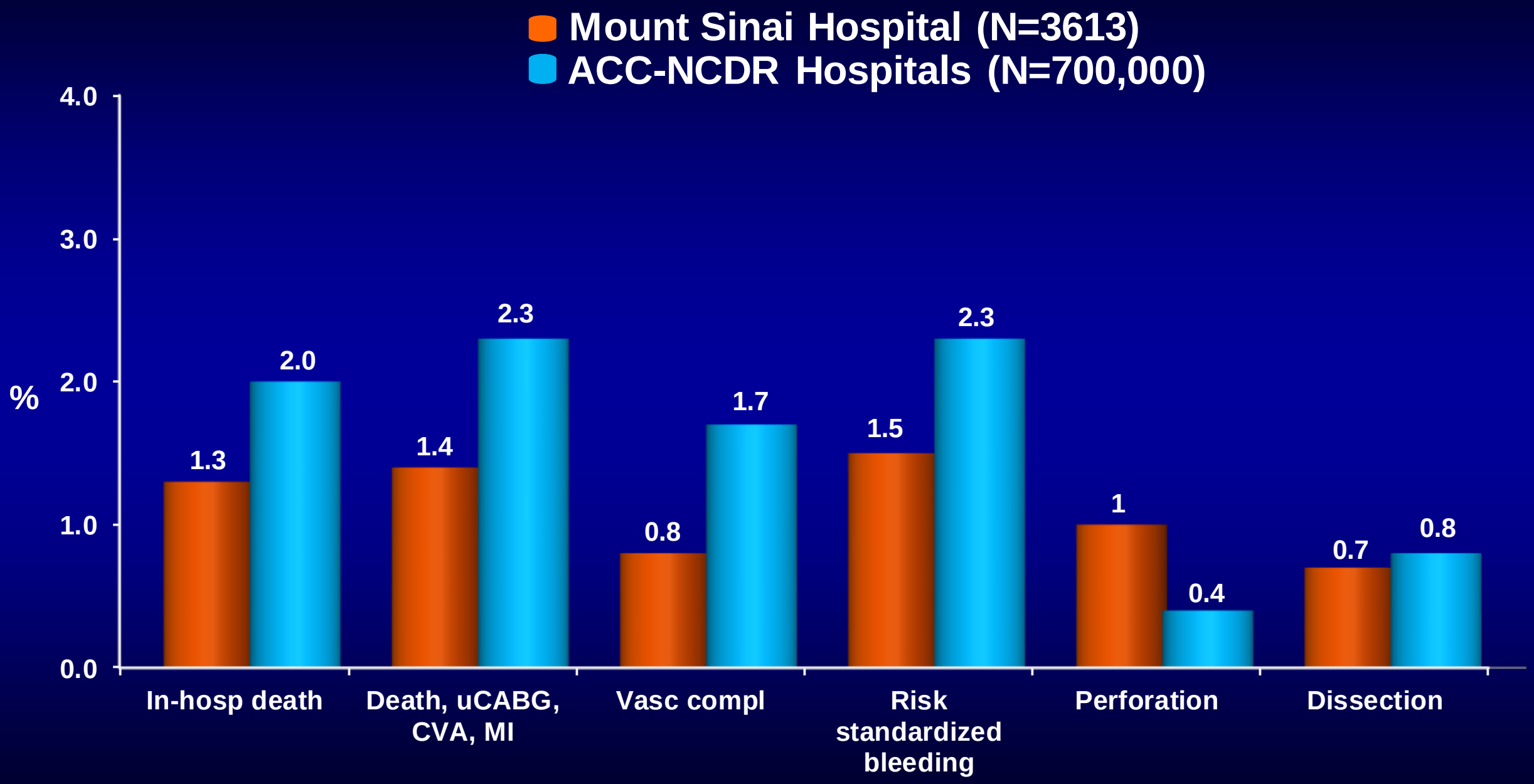

CCCLiveCases.org: More than 11 years of live cases

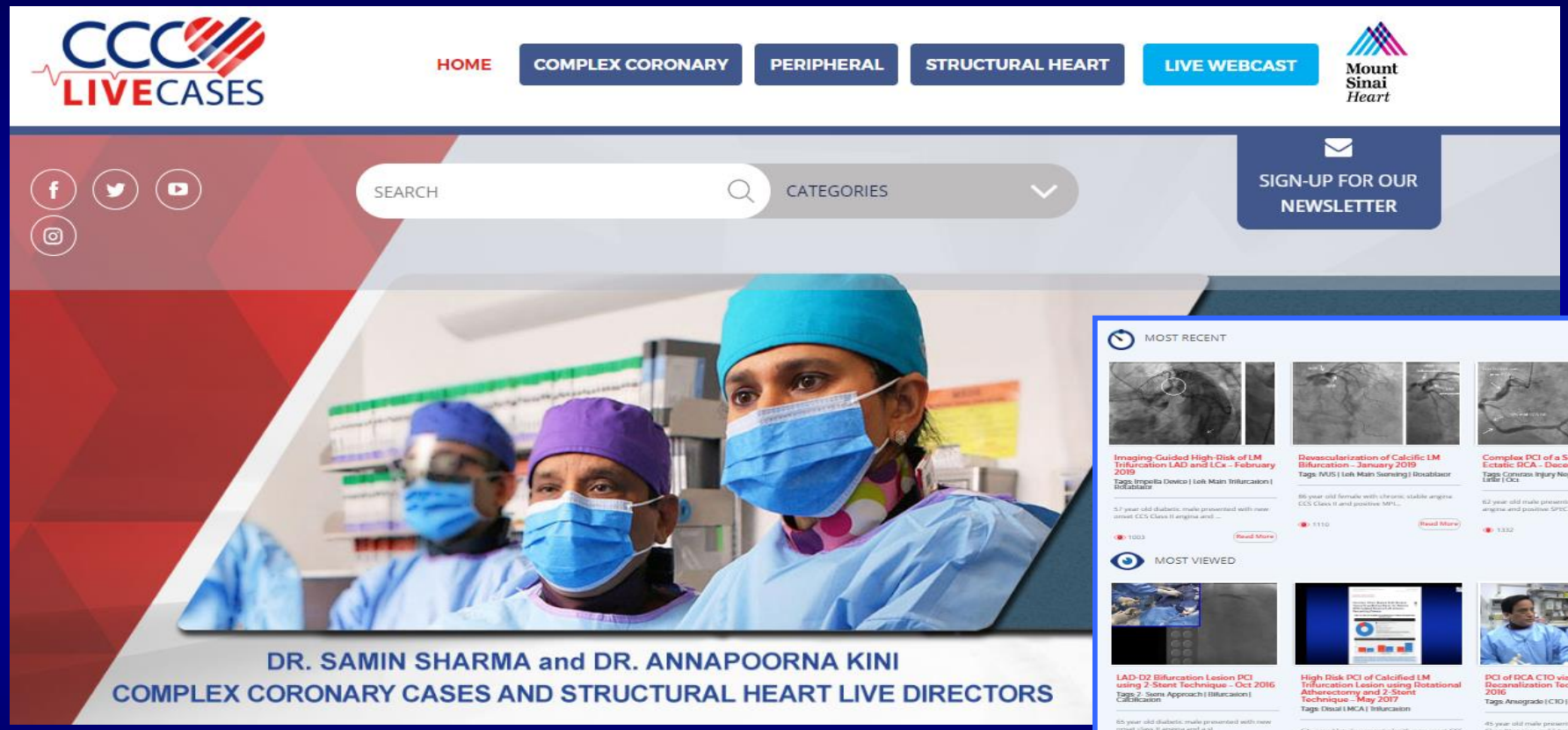

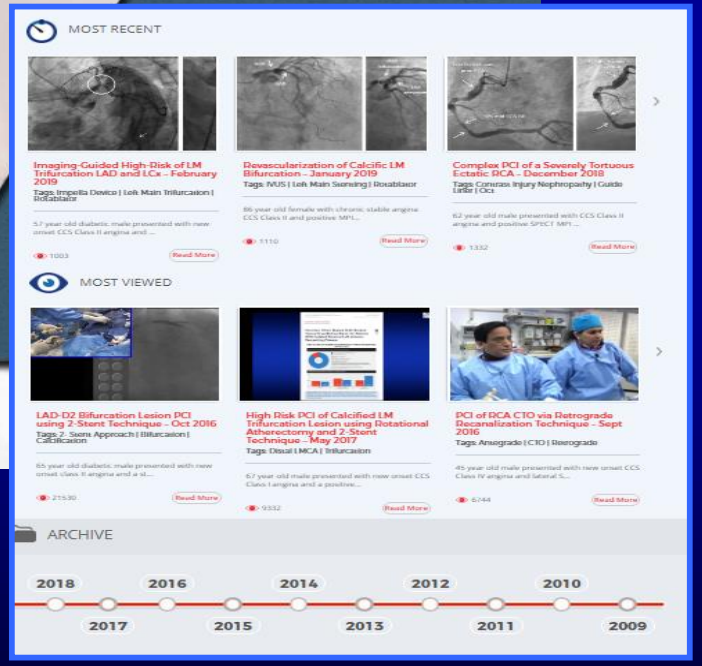

COMPLEX CORONARY CASES
Occurs 3rd Tuesday of the month at 8am

LIVE PERIPHERAL INTERVENTIONS
Every 4th Wednesday at 8am

STRUCTURAL HEART LIVE CASES
Every other Tuesday at 9am

www.ccclivecases.org

CCCLivecases Total Pageviews = 764,876

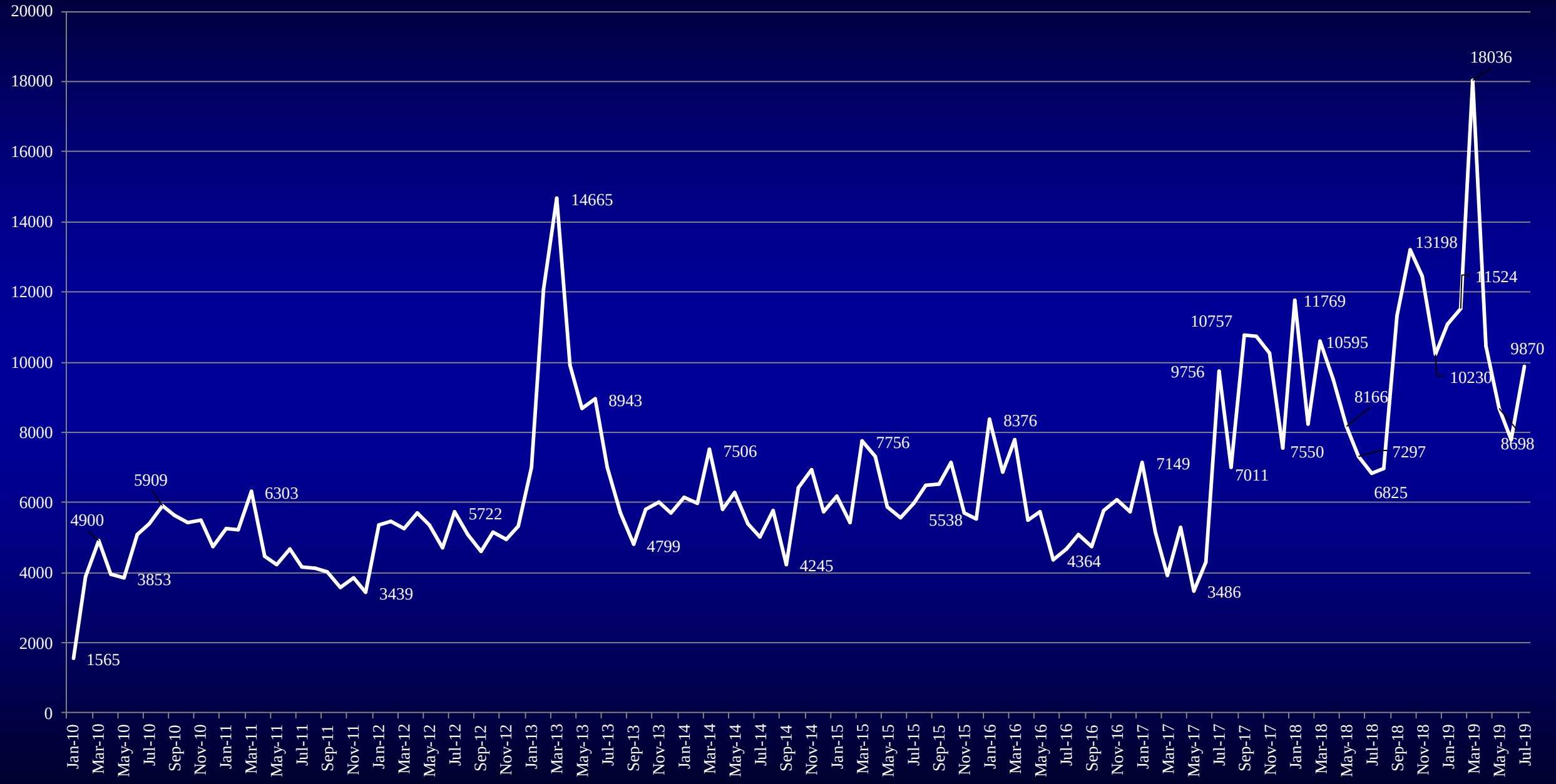

Total YouTube Pageviews = 266,037

CCCLivecases Total Pageviews = 764,876

1.03M+

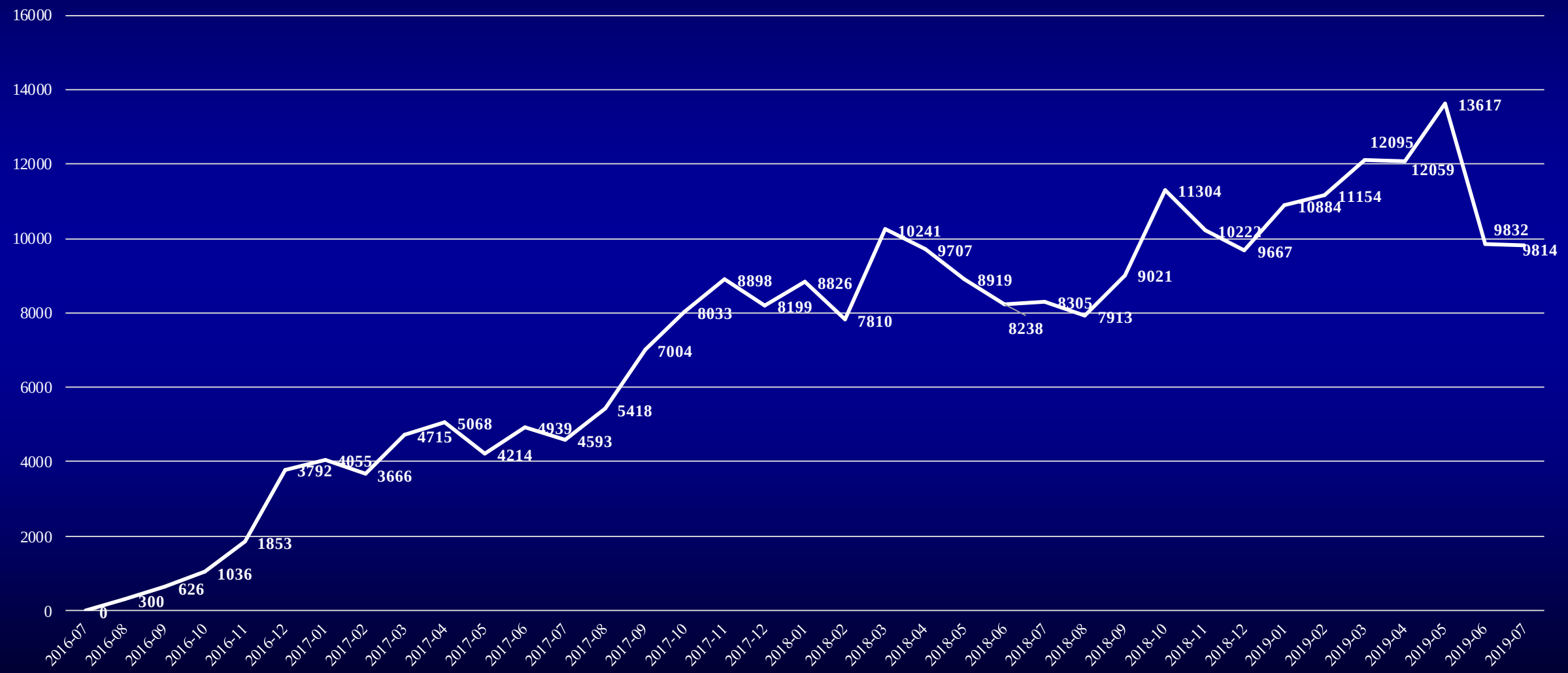

cardiologyapps.com

Home | The Apps | About Us | Contact Us | Search Site

Our Latest Mobile Apps

CalcificAID

CalcificAID guides medical

TAVRCathAID

The TAVRcathAID app utilizes

OCTAID

The OCTAID app is an educational

Cath Lab Apps CardiologyApps.com

More than 28,000 unique downloads

BifurcAID	OCTAID	TranseptAID	TAVRcathAID	CalcificAID	STEMIcathAID
iOS 5/5 stars	iOS 5/5 stars	iOS 5/5 stars	iOS 5/5 stars	iOS 5/5 stars	
8596 downloads	5068 downloads	2073 downloads	1074 downloads	931 downloads	
Android 4.4/5 stars	Android 4.8/5 stars	Android N/A stars	Android N/A stars	Android 5/5 stars	
6145 downloads	2850 downloads	549 downloads	547 downloads	538 downloads	
Released sept 2017	Released June 2018	Released March 2018	Released Sept 2018	Released June 2019	Coming Soon

Download for Free on Both:

Download on the App Store

GET IT ON Google Play

Apps Coming Soon…

STEMIcathAID – STEMI patient transfer platform designed to optimize communication between key members, record key performance metrics for AHA's Mission: Lifeline program, and avoid costly false activations through direct CCL contact.

BifurcAID 3D – An animated bifurcation lesion treatment educational application and website. With two views, detailed descriptions, and more, BifurcAID 3D helps make clear the complex steps in techniques such as Minicrush, DK Crush and Culotte, as well as provisional approached and bailout techniques.

TBA

GuidewireAID – This application covers the design of coronary guidewires and the resulting properties they exhibit during use in the lab. With more than a hundred available wires in multiple configurations,

BifurcAID 3D – DK Crush & Minicrush



STEMIcathAID: STEMI Patient Transfer Optimized

Designed following the AHA's Mission: Lifeline STEMI treatment pathway recommendation, STEMIcathAID offers a platform for the referring physician, transfer, and PCI center teams to communicate effectively, quickly involve the cath lab, and automatically record key performance metrics.

Raise Alarm:

Notify cath lab team for quick expert review of suspected STEMI; accept or reject

Enter Info:

Share name, DOB, MRN, and key vitals such as HR and BP with care team

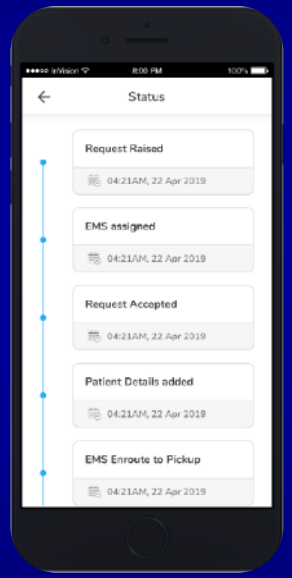

See Progress:

Automatically time-stamped records such as EMS pickup and acceptance of STEMI alert

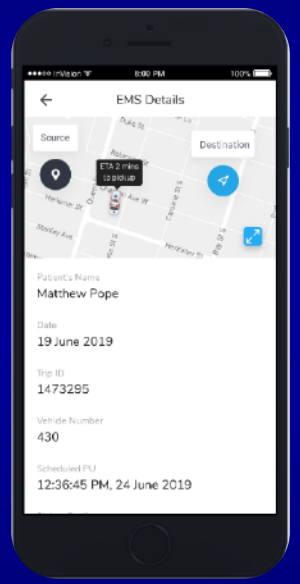

Track GPS:

Track patient transfer in order to prepare for their arrival

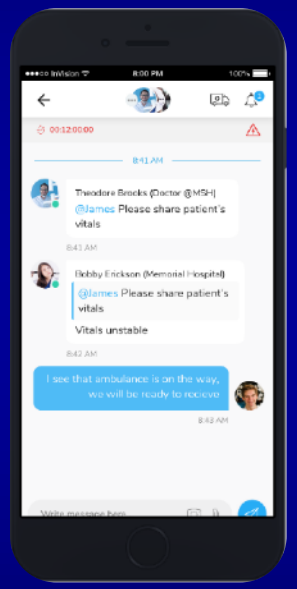

Communicate:

Messaging between teams is easy and kept within medical records

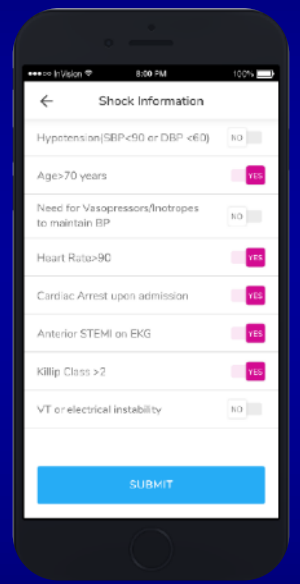

Screen Shock:

Cardiogenic shock screening prepares for potential shock team response

And more…


TAVR
CathAID
THANK
YOU!
OCT

Q&A

Question 1: Q

A 40 year old female with history of HTN, and pre-diabetes presents with substernal chest pain. Stress MPI concerning for ischemia involving the RCA territory. She was referred for coronary angiography which showed a 80% stenosis in the proximal RCA. Run-through wire was used to cross the lesion, and pre-dilated using a 3.0/15mm balloon to 18 ATM. On removal of the balloon, the guide was inadvertently disengaged and wire position was lost. The patient developed crushing chest pain and the guide was quickly re-engaged and lesion was rewired using the same wire. Contrast is injected and there is TIMI 0 flow. What is the next best step?

Question 1: Q

A. Rapid saline flushes and IC vasodilators
B. Quickly deliver a stent and deploy it
C. Use the same balloon, dotter and repeat balloon dilatation
D. Use a dual lumen catheter and inject small amount of contrast to confirm lumen wire position

Question 1: Q

A. Rapid saline flushes and IC vasodilators
B. Quickly deliver a stent and deploy it
C. Use the same balloon, dotter and repeat balloon dilatation
D. Use a dual lumen catheter and inject small amount of contrast to confirm lumen wire position

Question 1: A

- Answer D: No-reflow due to thrombotic or emboli is less likely in this situation and usually seen when using atherectomy devices and performing vein graft interventions. The reason for TIMI 0 flow is likely because of iatrogenic coronary dissection. It is vital to confirm wire position and assure you are in the true lumen prior to delivering a balloon or stent as this can lead to further catastrophe if a stent is deployed over the dissected flap, sealing off the vessel.

D. Use a dual lumen catheter and inject small amount of contrast to confirm lumen wire position

Question 2: Q

- A 65 year old male with history of HTN, HLD, DM, and known CAD s/p multiple PCI's who has been having refractory angina chest pain despite being on optimal medical therapy. He was referred for coronary angiography which shows a 60% distal RCA lesion. Patient was appropriately anticoagulated with Bivalirudin and FFR was performed per protocol, with a result of 0.85. After pulling back the wire into the guide catheter, repeat coronary angiography shows a small amount of contrast staining with extravasation along a small caliber distal RPDA. Patient became hemodynamically unstable with BP dropping from 160/90 with a HR of 90, to a BP of 106/68 and HR 112. Activated clotting time is 310. What is the immediate next step?

Question 2: Q

A. Use a renegade microcatheter to deliver coils to embolize the vessel

B. Quickly deliver a covered stent in the RPDA and deploy it

C. Emergent CTS consultation

D. D/C anticoagulation and balloon inflation in distal RCA

E. Perform pericardiocentesis

Question 2: Q

A. Use a renegade microcatheter to deliver coils to embolize the vessel
B. Quickly deliver a covered stent in the RPDA and deploy it
C. Emergent CTS consultation
D. D/C anticoagulation and balloon inflation in distal RCA
E. Perform pericardiocentesis

Question 2: A

- Answer A: This patient has a Type 3 perforation with contrast extravasation into the pericardial space, leading to cardiac tamponade. The primary focus is to gain control of the situation and seal the perforation. Of the choices, listed delivery of coils is the best next step. The RPDA in this case was of small caliber, and a covered stent is bulky and difficult to deliver distally to seal the perforation. Heparin anticoagulation can be reversed with protamine sulfate after equipment is removed but it has no role for reversal of bivalirudin. Performing pericardiocentesis is important but it is crucial to gain control of the source of bleeding first. Had prolonged balloon tamponade of the vessel to seal the perforation been listed, it would have also been correct.

A. Use a renegade microcatheter to deliver coils to embolize the vessel

Question 3: Q

- An 80-year-old man with history of HTN, IDDM, and active tobacco use presented to an outside hospital. He was found to have severely calcified and diffuse multivessel disease with LM involvement, SYNTAX score of 30. He was referred for CABG but patient declined and transferred to your facility for complex PCI. Echocardiography was performed and showed an LVEF of <20%. He undergoes IMPELLA assisted PCI of the LM with use of rotational atherectomy. While performing rotational atherectomy using a 1.5mm burr, it became stuck. Multiple techniques were deployed to retrieve the burr but all were unsuccessful, and patient was referred for emergent CTS for 3 vessel CABG and burr retrieval. Which of the following is not considered a part of optimal rotational atherectomy technique to prevent associated complications.

Question 3: Q

A. Maximum burr-to-artery ratio of 0.4 to 0.6

B. Rotational speed of 150,000 rpm, with higher speeds reserved for cases in which burr cannot cross lesion despite optimal technique

C. Burr advancement with steady pressure

D. Short ablation runs up to 20 seconds in duration

E. Avoiding decelerations exceeding 5000 rpm

F. Final polishing run at completion of atherectomy

Question 3: Q

A. Maximum burr-to-artery ratio of 0.4 to 0.6

B. Rotational speed of 150,000 rpm, with higher speeds reserved for cases in which burr cannot cross lesion despite optimal technique

C. Burr advancement with steady pressure

D. Short ablation runs up to 20 seconds in duration

E. Avoiding decelerations exceeding 5000 rpm

F. Final polishing run at completion of atherectomy

Question 3: A

- Answer C: C is considered part of optimal rotational atherectomy technique. Variations in burr motion and speed contribute importantly to risk of complications, and in particular, slow-flow/no-reflow and myocardial infarction. The best combination of technique and speed is that which minimizes excessive decelerations/stalling, distal thromboembolization, and thermal injury. In addition to appropriate burr sizing, fundamental elements of optimal RA technique include (1) a rotational speed of 140 000 to 150 000 rpm, (2) **gradual burr advancement with a slow, pecking to-and-fro motion**, (3) short ablation runs lasting no more than 20 seconds, pausing between runs, and (4) avoidance of decelerations >5000 rpm. Visual, tactile, and auditory feedback provide additional signals regarding resistance to burr advancement. Once the lesion has been fully crossed, RA completes with a final polishing run, which should be smooth and without resistance.

C. Burr advancement with steady pressure

Question 4: Q

- While performing coronary angiography, a 5cc column of air in inadvertently injected. You notice there is persistent dye within the lumen of the vessel. You assure the system is appropriately prepared and air tight, and bleed back from the guide-catheter clears any air in the system. While preparing the system, the patient develops crushing chest pain and becomes hypotensive and bradycardic. What is the next best step in management?

Question 4: Q

A. Perform vigorous flushing using saline.
B. Use of vasodilators (adenosine, CCB, nitrates) for treatment of slow flow/no-reflow
C. Give 0.5mg of atropine, followed by vigorous flushing using saline mixed with aspirated blood
D. Give IV phenylephrine 200ug, 0.5mg of atropine, followed by vigorous flushing using saline mixed with aspirated blood.
E. Dissolving or passage of the air embolism by transient elevation of intra-atrial pressure by use of inotropes and intra-aortic balloon pump.

Question 4: Q

A. Perform vigorous flushing using saline.

B. Use of vasodilators (adenosine, CCB, nitrates) for treatment of slow flow/no-reflow

C. Give 0.5mg of atropine, followed by vigorous flushing using saline mixed with aspirated blood

D. Give IV phenylephrine 200ug, 0.5mg of atropine, followed by vigorous flushing using saline mixed with aspirated blood.

E. Dissolving or passage of the air embolism by transient elevation of intra-atrial pressure by use of inotropes and intra-aortic balloon pump.

Question 4: A

Blood pressure management:

- If hypotension and SBP is 50-90 mmHg give IV phenylnephrine 200 ug push and followed by flush with saline, repeat as needed every minute
- If blood pressure is non-measureable **give IV epinephrine 1cc of [1:10,000 dilution]** push and followed by flush with saline, repeat as needed every 2 minutes
- Bradycardia Management
  - IV atropine 0.5-1mg (up to a dose of 3mg), Dopamine 2-10 ug/kg/min gtt, and/or epinephrine 2-10 ug/min gtt
  - Transcutaneous pacing or temporary venous pacer

Dissolving or passage of the air embolism by transient elevation of intra-atrial pressure by use of inotropes and intra-aortic balloon pump.

D. Give IV phenylephrine 200ug, 0.5mg of atropine, followed by vigorous flushing using saline mixed with aspirated blood.


TAVR CathAID
Cardiology Apps.com
OCT
THANK YOU!