Aortic Regurgitation

VAANI PANSE GARG, MD

ASSISTANT PROFESSOR OF MEDICINE

ASSOCIATE PROGRAM DIRECTOR CARDIOLOGY FELLOWSHIP

MOUNT SINAI MORNINGSIDE – NEW YORK, NY

IOWA ACC ECHO BOARD REVIEW SERIES 2021

Normals

Aortic valve leaflets are uniform in thickness except for a slightly more fibrous region at the anatomic midpoint of each cusp or nodules of **Arantius**

Aortic Valve

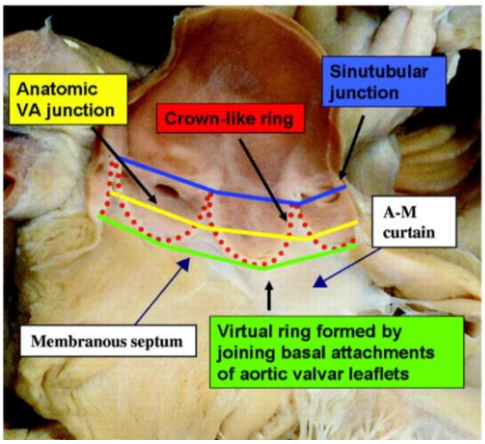

Normal aortic valve area (AVA) 3-4 cm^2 ;
Normal opening usually 2 cm

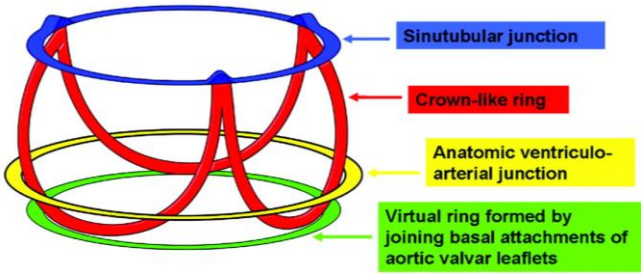

PIAZZA ET AL. CIRCULATION: CARDIOVASCULAR INTERVENTIONS. 2008;1:74–81

Normal Aortic Valve M-Mode

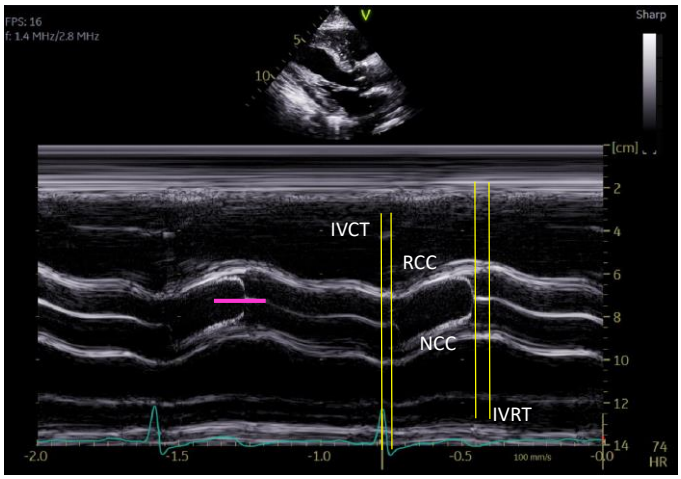

Parallelogram in shape

Midline closure

RCC = right coronary cusp

NCC = non-coronary cusp

IVCT = isovolumetric contraction time

IVRT = isovolumetric relaxation time

Aortic Valve: Transthoracic

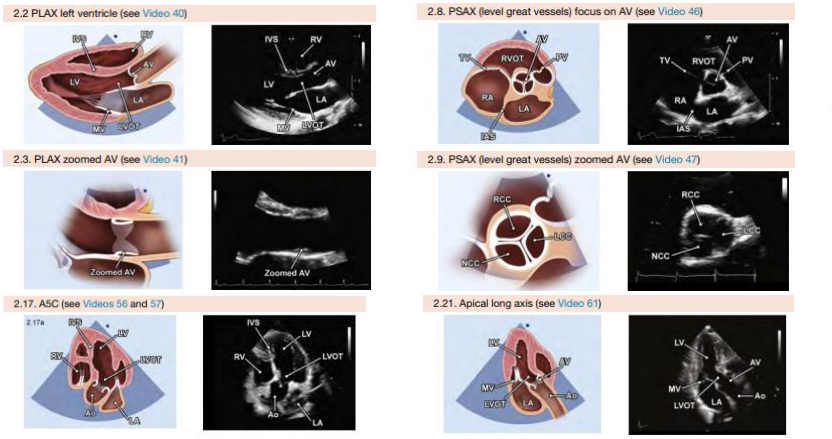

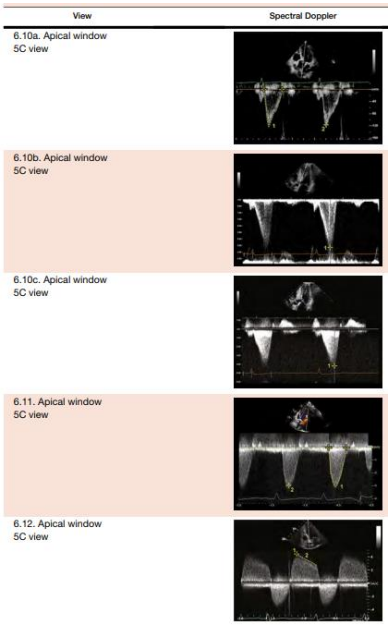

ASE 2018 GUIDELINE ADULT COMPREHENSIVE TTE

Aortic Valve: Transesophageal

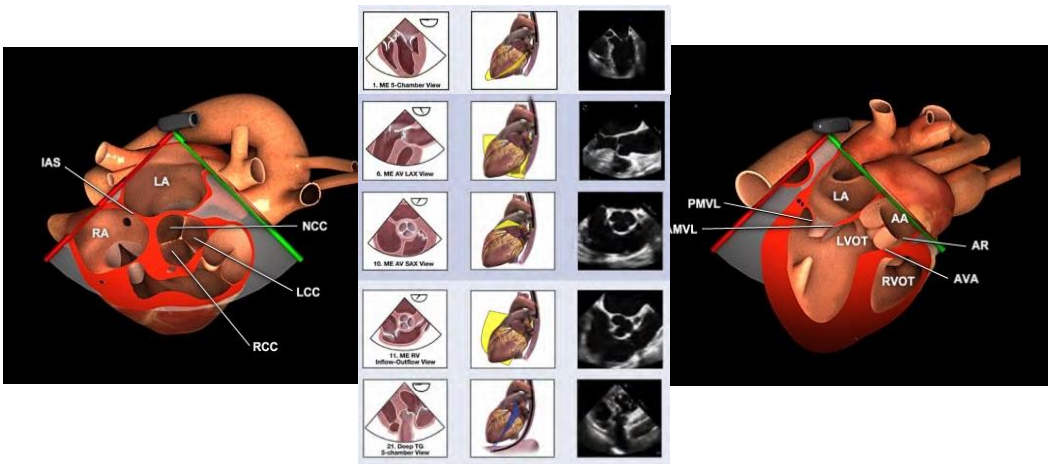

ASE GUIDELINE COMPREHENSIVE TEE 2013
HTTP://PIE.MED.UTORONTO.CA/TEE/INDEX.HTM

Questions

Question 1

3. In the midesophageal TEE short axis of the aortic valve:

A. The non-coronary cusp is the most anterior cusp.

B. The left coronary cusp is the most anterior cusp.

C. The right coronary is adjacent to the interatrial septum.

D. The non-coronary cusp is adjacent to the interatrial septum.

18. This short-axis of the aortic valve shows (Fig. 6-3):

A. Bicuspid aortic valve.

B. Lambl's excrescence.

C. Fibroelastoma of the left coronary cusp.

D. Fibroelastoma of the noncoronary cusp.

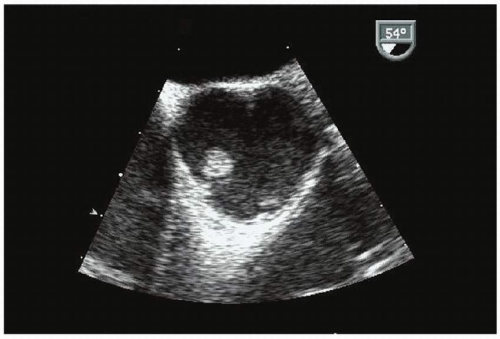

KLEIN, A. CLINICAL ECHOCARDIOGRAPHY REVIEW, 2017

Question 2

5. A 30-year-old woman is referred for management of a newly diagnosed subaortic stenosis. She is asymptomatic, but during a routine physical examination a loud systolic murmur was heard. An echocardiogram demonstrated a subaortic membrane with a gradient of 44 mm Hg and concomitant presence of moderate aortic valve regurgitation. The left ventricle is borderline enlarged, with an LVEF of 57%. At TEE, the aortic valve does not appear to be calcified. Which of the following statements are correct?

A. This type of lesion responds well to balloon dilatation.

B. The patient should undergo resection of the subaortic membrane and aortic valve replacement.

C. Careful inspection of the pulmonary valve and pulmonary artery should be carried out during TEE.

D. Doppler interrogation of the abdominal aorta provides no information in this case.

KLEIN, A. CLINICAL ECHOCARDIOGRAPHY REVIEW, 2017

Question 3

6. Which of the following statements regarding aortic regurgitation (AR) is correct?

A. A PISA radius of 0.8 cm with an aliasing velocity of 40 cm/s and a peak aortic regurgitant velocity of 4 m/s is consistent with severe AR.

B. A pressure half-time greater than 250 ms is consistent with severe AR.

C. Vena contracta is best evaluated from the apical long-axis view.

D. The use of the suprasternal notch window is not useful in the assessment of AR.

KLEIN, A. CLINICAL ECHOCARDIOGRAPHY REVIEW, 2017

Question 4

8. A 67-year-old man with aortic regurgitation underwent transthoracic echocardiographic examination. There was no mitral stenosis or regurgitation. The following values were obtained:

Table 8-8

Peak diastolic velocity of aortic regurgitant jet	5.0 m/s
End-diastolic velocity of aortic regurgitant jet	3.7 m/s
Pressure half-time of aortic regurgitant jet	656 ms
Peak aortic antegrade flow velocity	2.2 m/s
Blood pressure	130/65 mm Hg

Based on the aforementioned data, one can conclude that:

A. Pressure half-time is consistent with severe aortic regurgitation.

B. Aortic valve area can be estimated as 220 divided by pressure half-time.

C. Peak left ventricular systolic pressure (LVSP) is lower than the systolic blood pressure (SBP).

D. Left ventricular end-diastolic pressure (LVEDP) is estimated at 10 mm Hg.

E. Aortic valve area cannot be calculated using continuity equation because there is aortic regurgitation.

KLEIN, A. CLINICAL ECHOCARDIOGRAPHY REVIEW, 2017

Aortic Regurgitation

Aortic Regurgitation: Classification

AI Class	Type I Normal cusp motion with FAA dilatation or cusp perforation				Type II Cusp Prolapse	Type III Cusp Restriction
	Ia	Ib	Ic	Id		
Mechanism						
Repair Techniques (Primary)	STJ remodeling *Ascending aortic graft*	Aortic Valve sparing: *Reimplantation or Remodeling with SCA*	SCA	Patch Repair *Autologous or bovine pericardium*	Prolapse Repair *Plication Triangular resection Free margin Resuspension Patch*	Leaflet Repair *Shaving Decalcificatio Patch*
(Secondary)	SCA		STJ Annuloplasty	SCA	SCA	SCA

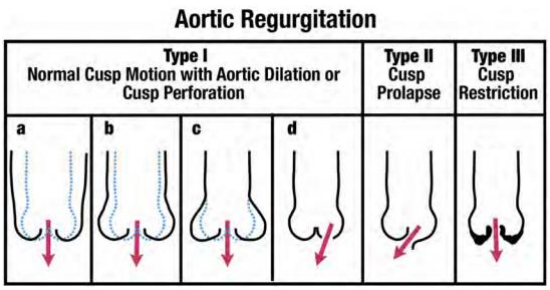

FAA = functional aortic annulus
STJ = sinotubular junction
SCA = subcommisural annuloplasy

BOODWHANI ET AL J OF THORACIC AND CARDIAC SURGERY 2009;
ZOGHBI ET AL. JASE 2017.

Aortic Regurgitation: Jet Width/LVOT Diameter

Mild
- Jet width <25% of LVOT diameter

Moderate
- Jet width within 25-64%

Severe
- Jet width >65% LVOT diameter = jet more than 2/3 in comparison to LVOT

Modality	Optimization	Example	Advantages	Pitfalls
Color flow Doppler 2D				
Jet width/ LVOT diameter	• Long-axis view • Zoomed view • Imaging plane for optimal VC measurement may be different from PISA • Measure in LVOT within 1 cm of the VC		• Simple sensitive screen for AR • Rapid qualitative assessment	• Underestimates AR in eccentric jets • May overestimate AR in central jets as AR jet may expand unpredictably below the orifice • Is affected by the size of the LVOT

*Nyquist limit at 50-60 cm/s

- Mild AR:
  - Jet width <25% of LVOT
  - Vena contracta <0.3 cm
  - Regurgitant volume <30 mL/beat
  - Regurgitant fraction <30%
  - ERO <0.10 cm^2
  - Angiography grade 1
- Moderate AR:
  - Jet width 25%-64% of LVOT
  - Vena contracta 0.3-0.6 cm
  - Regurgitant volume 30-59 mL/beat
  - Regurgitant fraction 30% to 49%
  - ERO 0.10-0.29 cm^2
  - Angiography grade 2
- Severe AR:
  - Jet width ≥65% of LVOT
  - Vena contracta >0.6 cm
  - Holodiastolic flow reversal in the proximal abdominal aorta
  - Regurgitant volume ≥60 mL/beat
  - Regurgitant fraction ≥50%
  - ERO ≥0.3 cm^2
  - Angiography grade 3 to 4
  - In addition, diagnosis of chronic severe AR requires evidence of LV dilation

ZOGHBI ET AL. JASE 2017;
OTTO ET AL. AHA/ACC UPDATE 2020.

Aortic Regurgitation: Jet Area

Mild
- Cross sectional area <5%

Moderate
- In between

Severe
- Cross sectional area >60% = basically more than 2/3

Semiquantitative parameters[§]				
VCW (cm)	<0.3	0.3-0.6		>0.6
Jet width/LVOT width, central jets (%)	<25	25-45	46-64	≥65
Jet CSA/LVOT CSA, central jets (%)	<5	5-20	21-59	≥60

Modality	Optimization	Example	Advantages	Pitfalls
Jet area/LVOT area	• Short-axis view • Zoom view • Measure within 1 cm of the VC		• Estimate of regurgitant orifice area	• Direction and shape of jet may overestimate or underestimate jet area

*Nyquist limit at 50-60 cm/s

ZOGHBI ET AL. JASE 2017;
OTTO ET AL. AHA/ACC UPDATE 2020.

Aortic Regurgitation: Vena Contracta

Mild
- Vena contracta < 0.3 cm

Moderate
- Vena contracta 0.3 – 0.6 cm

Severe
- Vena contracta > 0.6 cm

*Vena contracta measured in the parasternal long axis due to best axial resolution (depth resolution)

*Nyquist limit at 50-60 cm/s

Modality	Optimization	Example	Advantages	Pitfalls
VC	• Parasternal long-axis view • Zoomed view • Imaging plane for optimal VC measurement may be different from that for PISA • Narrowest area of jet at or just apical to the valve		• Surrogate for regurgitant orifice size • May be used in eccentric jets • Independent of flow rate and driving pressure • Less dependent on technical factors • Good at identifying mild or severe AR	• Problematic in the presence of multiple jets or bicuspid valves • Convergence zone needs to be visualized • The direction of the jet (in relation to the insonation beam) will influence the appearance of the jet

- Mild AR:
  - Jet width <25% of LVOT
  - Vena contracta <0.3 cm
  - Regurgitant volume <30 mL/beat
  - Regurgitant fraction <30%
  - ERO <0.10 cm^2
  - Angiography grade 1
- Moderate AR:
  - Jet width 25%-64% of LVOT
  - Vena contracta 0.3-0.6 cm
  - Regurgitant volume 30-59 mL/beat
  - Regurgitant fraction 30% to 49%
  - ERO 0.10-0.29 cm^2
  - Angiography grade 2
- Severe AR:
  - Jet width ≥65% of LVOT
  - Vena contracta >0.6 cm
  - Holodiastolic flow reversal in the proximal abdominal aorta
  - Regurgitant volume ≥60 mL/beat
  - Regurgitant fraction ≥50%
  - ERO ≥0.3 cm^2
  - Angiography grade 3 to 4
  - In addition, diagnosis of chronic severe AR requires evidence of LV dilation

ZOGHBI ET AL. JASE 2017;
OTTO ET AL. AHA/ACC UPDATE 2020.

Aortic Regurgitation: Proximal Flow Convergence

Modality	Optimization	Example	Advantages	Pitfalls
Proximal flow convergence	• Align direction of flow with insonation beam to avoid distortion of hemisphere from noncoaxial imaging • Zoomed view • Change baseline of Nyquist limit in the direction of the jet • Adjust lower Nyquist limit to obtain the most hemispheric flow convergence	Apical view 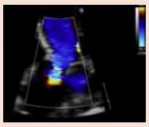 Parasternal view 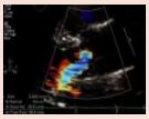	• Rapid qualitative assessment	• Multiple jets • Constrained jet (aortic wall) • Nonhemispheric shape • Timing in early diastole

- Mild AR:
  - Jet width <25% of LVOT
  - Vena contracta <0.3 cm
  - Regurgitant volume <30 mL/beat
  - Regurgitant fraction <30%
  - ERO <0.10 cm^2
  - Angiography grade 1
- Moderate AR:
  - Jet width 25%-64% of LVOT
  - Vena contracta 0.3-0.6 cm
  - Regurgitant volume 30-59 mL/beat
  - Regurgitant fraction 30% to 49%
  - ERO 0.10-0.29 cm^2
  - Angiography grade 2
- Severe AR:
  - Jet width ≥65% of LVOT
  - Vena contracta >0.6 cm
  - Holodiastolic flow reversal in the proximal abdominal aorta
  - Regurgitant volume ≥60 mL/beat
  - Regurgitant fraction ≥50%
  - ERO ≥0.3 cm^2
  - Angiography grade 3 to 4
  - In addition, diagnosis of chronic severe AR requires evidence of LV dilation

Coming later…

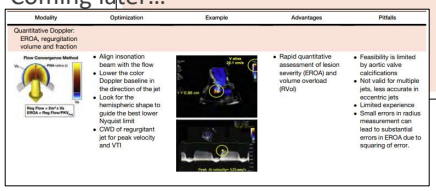

ZOGHBI ET AL. JASE 2017;
OTTO ET AL. AHA/ACC UPDATE 2020.

M-Mode: Severe Aortic Regurgitation

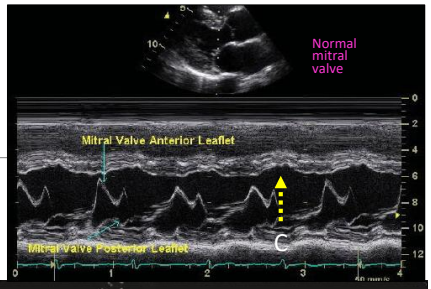

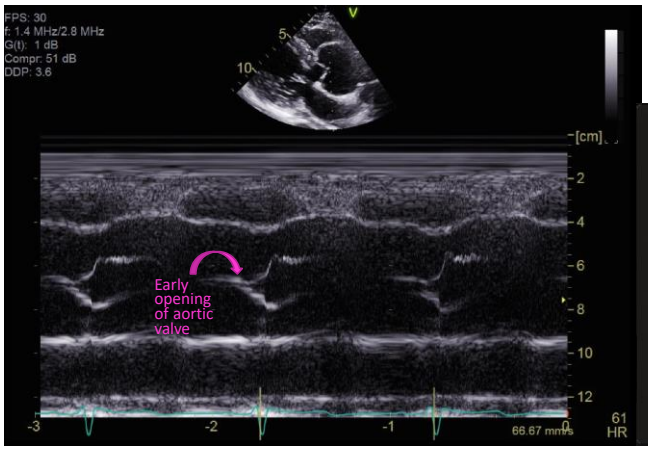

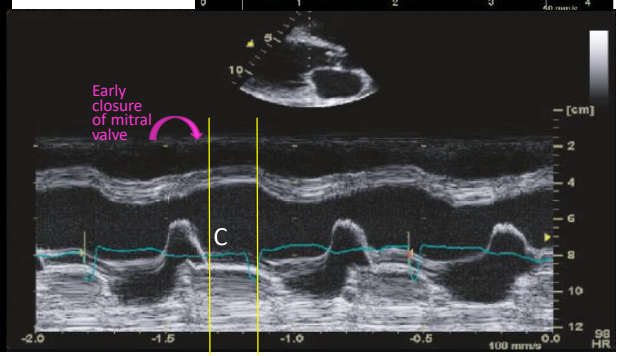

Aortic Regurgitation: Pulse Wave

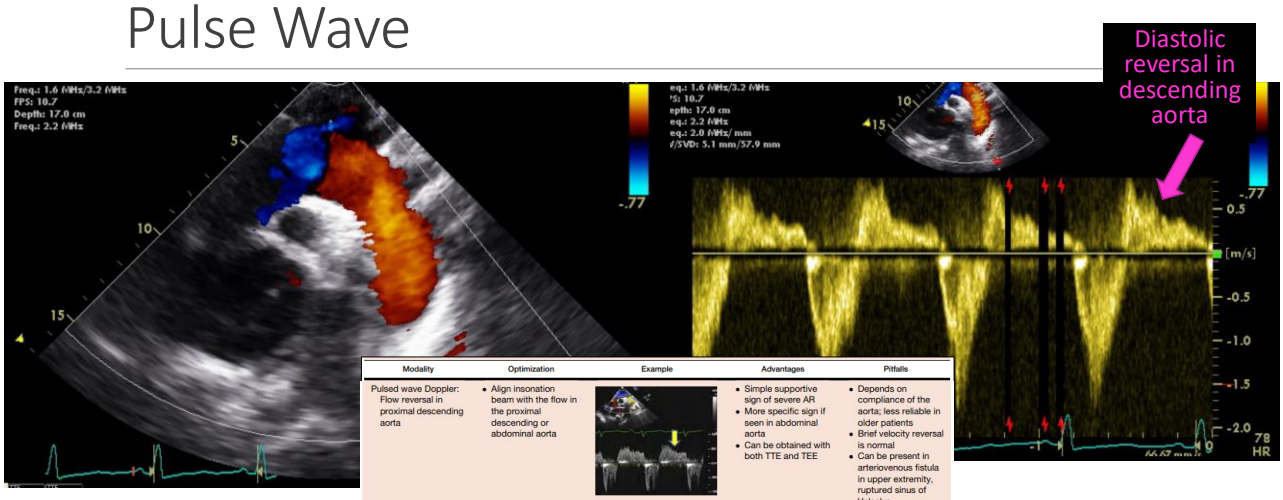

Modality	Optimization	Example	Advantages	Pitfalls
Pulsed wave Doppler: Flow reversal in proximal descending aorta	• Align insonation beam with the flow in the proximal descending or abdominal aorta		• Simple supportive sign of severe AR • More specific sign if seen in abdominal aorta • Can be obtained with both TTE and TEE	• Depends on compliance of the aorta; less reliable in older patients • Brief velocity reversal is normal • Can be present in arteriovenous fistula in upper extremity, ruptured sinus of Valsalva • May not be holodiastolic in acute AR

Aortic Regurgitation: Continuous Wave

Mild
- Pressure half time (PHT) >500 ms

Moderate
- In between 200-500

Severe
- Pressure half time (PHT) <200 ms

Modality	Optimization	Example	Advantages	Pitfalls
CWD				
Density of regurgitant jet	• Align insonation beam with the flow • Adjust overall gain		• Simple • Density is proportional to the number of red blood cells reflecting the signal • Faint or incomplete jet is compatible with mild or trace AR	• Qualitative • Perfectly central jets may appear denser than eccentric jets of higher severity • Overlap between moderate and severe AR
Jet deceleration rate (pressure half-time)	• Align insonation beam with the flow • Usually best from apical windows • In eccentric jets, may be best from parasternal window, helped by color Doppler		• Simple • Specific sign of pressure relation between aorta and LV • If long, excludes severe AR	• Qualitative • Poor alignment of Doppler beam may result in lower pressure half-time • Affected by changes that modify LV-aorta pressure gradient (if short, implies significant AR or high LV filling pressure)

ZOGHBI ET AL. JASE 2017.

Severity of Chronic Aortic Regurgitation

Table 11 Grading the severity of chronic AR with echocardiography

	AR severity			
	Mild	Moderate		Severe
Structural parameters				
Aortic leaflets	Normal or abnormal	Normal or abnormal		**Abnormal/flail, or wide coaptation defect**
LV size	**Normal**[*]	Normal or dilated		Usually dilated[†]
Qualitative Doppler				
Jet width in LVOT, color flow	**Small in central jets**	Intermediate		**Large in central jets**; variable in eccentric jets
Flow convergence, color flow	**None or very small**	Intermediate		**Large**
Jet density, CW	**Incomplete or faint**	Dense		Dense
Jet deceleration rate, CW (PHT, msec)[‡]	Incomplete or faint Slow, >500	Medium, 500-200		**Steep, <200**
Diastolic flow reversal in descending aorta, PW	**Brief, early diastolic reversal**	Intermediate		**Prominent holodiastolic reversal**
Semiquantitative parameters[§]				
VCW (cm)	<0.3	0.3-0.6		>0.6
Jet width/LVOT width, central jets (%)	<25	25-45	46-64	≥65
Jet CSA/LVOT CSA, central jets (%)	<5	5-20	21-59	≥60
Quantitative parameters[§]				
RVol (mL/beat)	<30	30-44	45-59	≥60
RF (%)	<30	30-39	40-49	≥50
EROA (cm²)	<0.10	0.10-0.19	0.20-0.29	≥0.30

Stage	Definition	Valve Anatomy	Valve Hemodynamics	Hemodynamic Consequences	Symptoms
A	At risk of AR	■ BAV (or other congenital valve anomaly) ■ Aortic valve sclerosis ■ Diseases of the aortic sinuses or ascending aorta ■ History of rheumatic fever or known rheumatic heart disease ■ IE	AR severity: none or trace	None	None
B	Progressive AR	■ Mild to moderate calcification of a trileaflet valve BAV (or other congenital valve anomaly) ■ Dilated aortic sinuses ■ Rheumatic valve changes ■ Previous IE	■ Mild AR: ■ Jet width <25% of LVOT ■ Vena contracta <0.3 cm ■ Regurgitant volume <30 mL/beat ■ Regurgitant fraction <30% ■ ERO <0.10 cm² ■ Angiography grade 1 ■ Moderate AR: ■ Jet width 25%-64% of LVOT ■ Vena contracta 0.3-0.6 cm ■ Regurgitant volume 30-59 mL/beat ■ Regurgitant fraction 30% to 49% ■ ERO 0.10-0.29 cm² ■ Angiography grade 2	■ Normal LV systolic function ■ Normal LV volume or mild LV dilation	None
C	Asymptomatic severe AR	■ Calcific aortic valve disease ■ Bicuspid valve (or other congenital abnormality) ■ Dilated aortic sinuses or ascending aorta ■ Rheumatic valve changes ■ IE with abnormal leaflet closure or perforation	■ Severe AR: ■ Jet width ≥65% of LVOT ■ Vena contracta >0.6 cm ■ Holodiastolic flow reversal in the proximal abdominal aorta ■ Regurgitant volume ≥60 mL/beat ■ Regurgitant fraction ≥50% ■ ERO ≥0.3 cm² ■ Angiography grade 3 to 4 ■ In addition, diagnosis of chronic severe AR requires evidence of LV dilation	■ C1: Normal LVEF (>55%) and mild to moderate LV dilation (LVESD <50 mm) ■ C2: Abnormal LV systolic function with depressed LVEF (≤55%) or severe LV dilation (LVESD >50 mm or indexed LVESD >25 mm/m²)	None; exercise testing is reasonable to confirm symptom status
D	Symptomatic severe AR	■ Calcific valve disease ■ Bicuspid valve (or other congenital abnormality) ■ Dilated aortic sinuses or ascending aorta ■ Rheumatic valve changes ■ Previous IE with abnormal leaflet closure or perforation	■ Severe AR: ■ Doppler jet width ≥65% of LVOT ■ Vena contracta >0.6 cm ■ Holodiastolic flow reversal in the proximal abdominal aorta ■ Regurgitant volume ≥60 mL/beat ■ Regurgitant fraction ≥50% ■ ERO ≥0.3 cm² ■ Angiography grade 3 to 4 ■ In addition, diagnosis of chronic severe AR requires evidence of LV dilation	■ Symptomatic severe AR may occur with normal systolic function (LVEF >55%), mild to moderate LV dysfunction (LVEF 40% to 55%), or severe LV dysfunction (LVEF <40%) ■ Moderate to severe LV dilation is present	■ Exertional dyspnea or angina or more severe HF symptoms

ZOGHBI ET AL. JASE 2017.
OTTO ET AL. AHA/ACC UPDATE 2020.

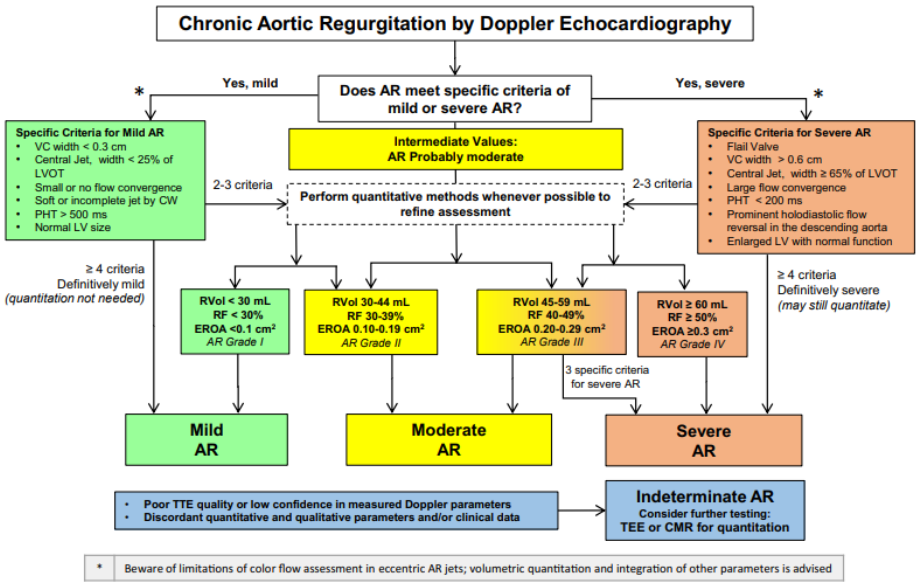

ZOGHBI ET AL. JASE 2017.

Aortic Regurgitation

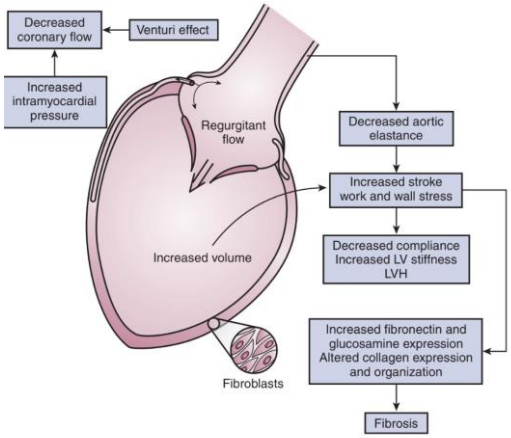

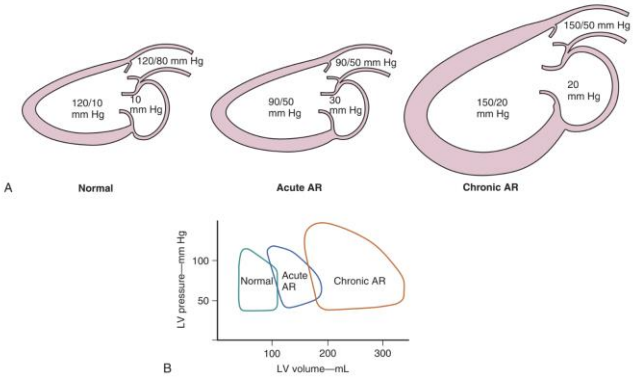

GOLDBARG & HALPERIN, NATURE CLINICAL PRACTICE CARDIOVASCULAR MEDICINE, MAY 2008.

Key Points

Chronic Aortic Regurgitation

- Severity graded using a combination of structural, qualitative Doppler, and semiquantitative parameters
- Jet often visible in all views
- Assess left ventricular size and volume
  - Globular and dilated
- Ejection fraction may fall as late finding
- Normal chamber volumes are unusual with chronic severe aortic regurgitation

Acute Severe Aortic Regurgitation

- Diagnostically more challenging
  - Color Doppler with short duration
  - Tachycardia
  - Low aortic regurgitation velocity
  - Eccentric jet
- Left ventricle not dilated
- Ejection fraction likely reduced
- M-Mode findings for aortic and mitral valves
- Low threshold for transesophageal echocardiogram (TEE)

Specific Diseases

Table 9 Etiology and mechanisms of AR

Mechanism	Specific etiology
Congenital/leaflet abnormalities	Bicuspid, unicuspid, or quadricuspid aortic valve Ventricular septal defect
Acquired leaflet abnormalities	Senile calcification Infective endocarditis Rheumatic disease Radiation-induced valvulopathy Toxin-induced valvulopathy: anorectic drugs, 5-hydroxytryptamine (carcinoid)
Congenital/genetic aortic root abnormalities	Annuloaortic ectasia Connective tissue disease: Loeys Deitz, Ehlers-Danlos, Marfan syndrome, osteogenesis imperfecta
Acquired aortic root abnormalities	Idiopathic aortic root dilatation Systemic hypertension Autoimmune disease: systemic lupus erythematosis, ankylosing spondylitis, Reiter's syndrome Aortitis: syphilitic, Takayasu's arteritis Aortic dissection Trauma

ZOGHBI ET AL. JASE 2017.

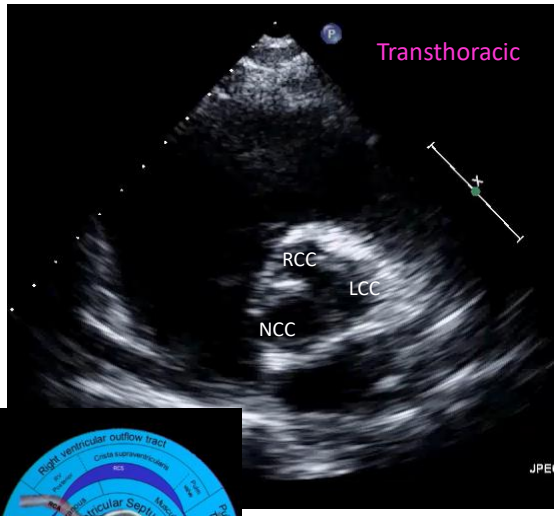

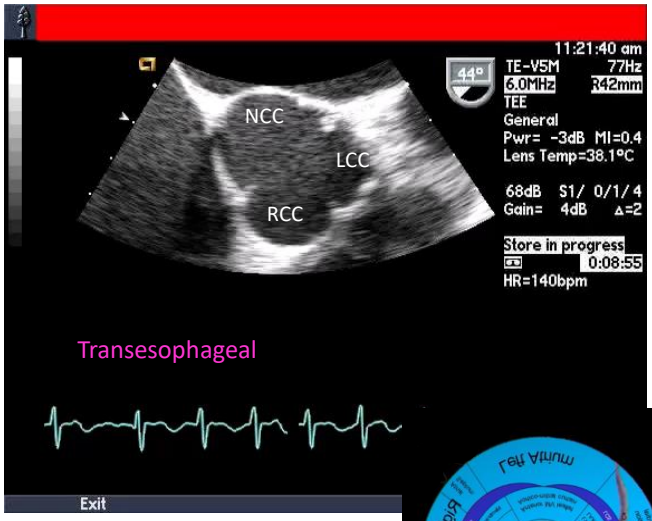

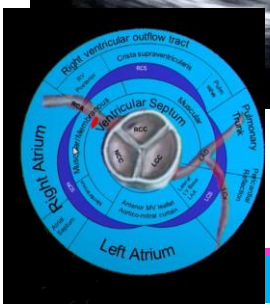

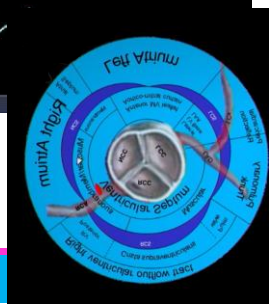

Bicuspid Aortic Valve

Bicuspid Aortic Valve

- Male predominance 2:1
- 1-2% of general population
- Most common is RCC-LCC fusion
  - RCC and NCC fusion 32%
  - Anterior/Posterior 14%
- Eccentric closure line on M-Mode
- Diagnose in <u>SYSTOLE</u>
- TTE 92% sensitivity; 96% specificity for detection
- 50% have associated aortopathy
- Coarctation
  - If bicuspid, 5% have coarctation
  - If coarctation, 50% have bicuspid

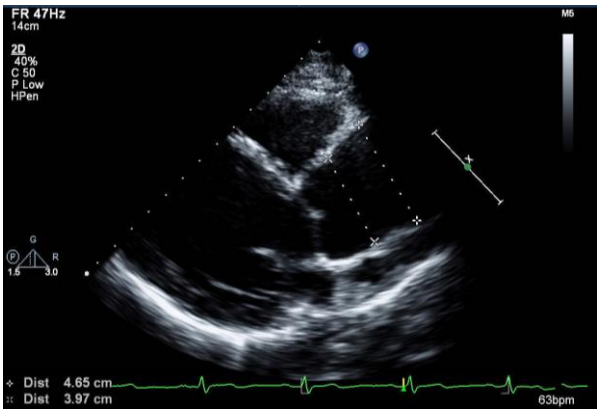

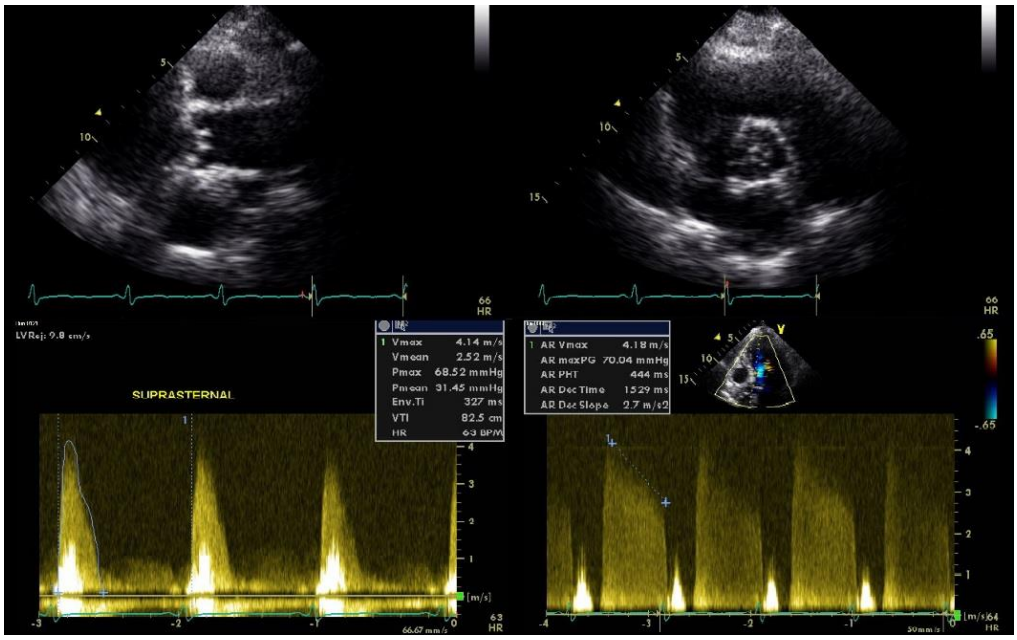

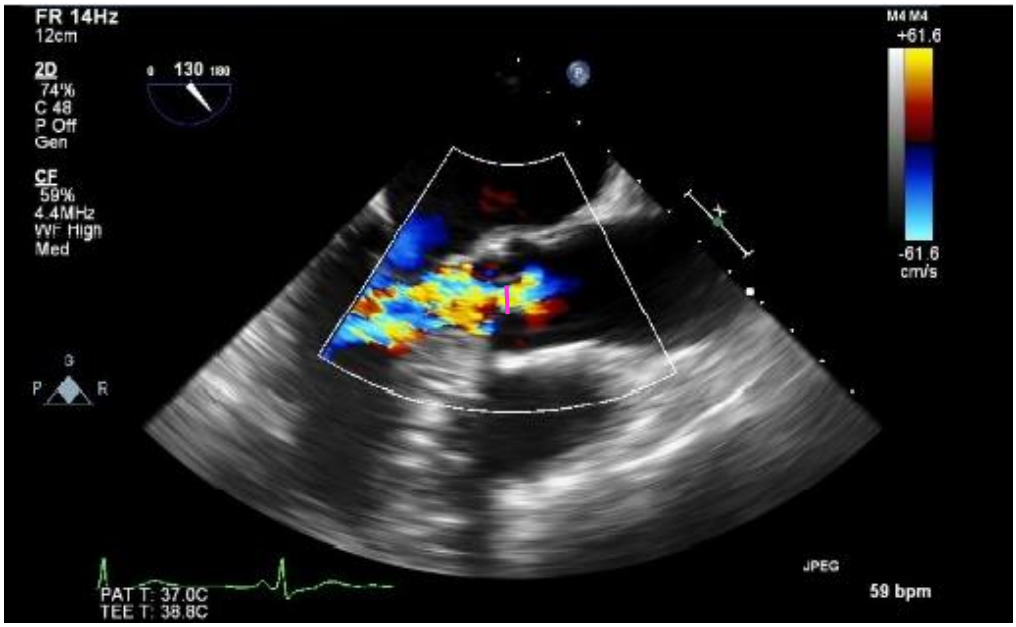

Quadricuspid Aortic Valve

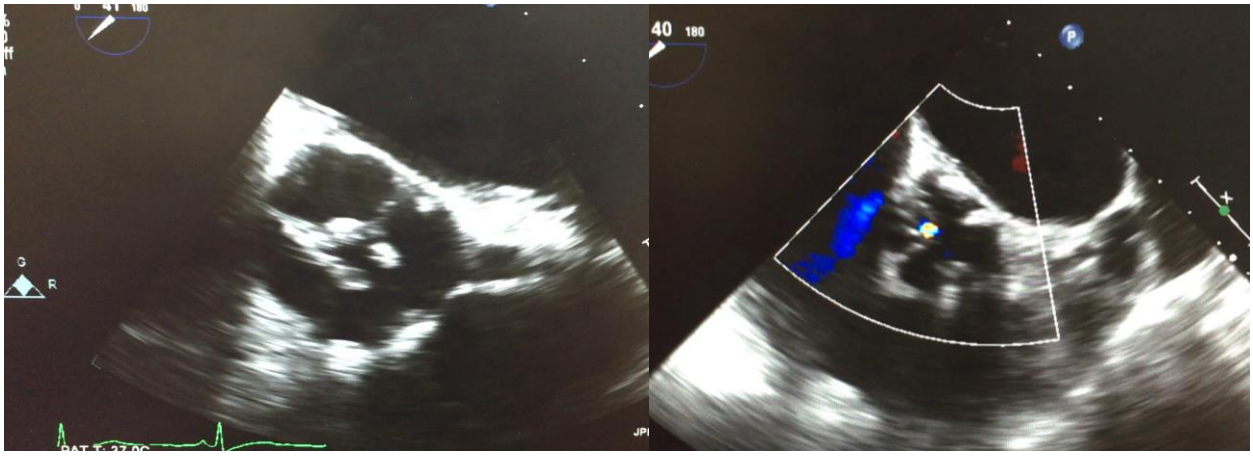

Quadricuspid Aortic Valve

- No gender preference
- Associated with aortic regurgitation
- Associated with anomalous coronary arteries (10%)
- Rare

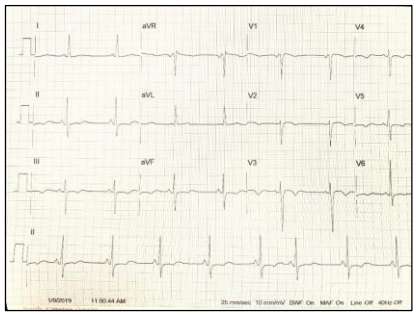

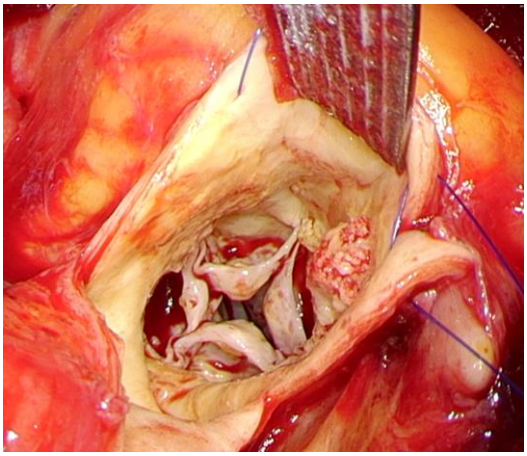

Ventricular Septal Defect

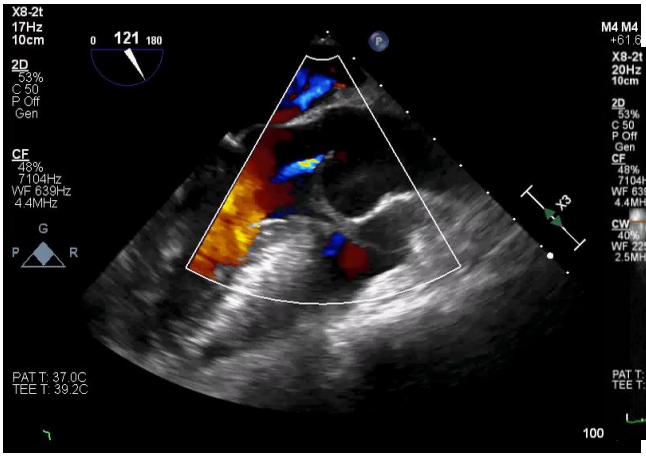

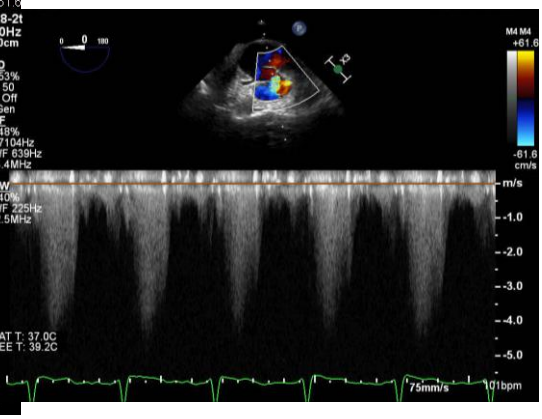

Endocarditis with Valve Destruction

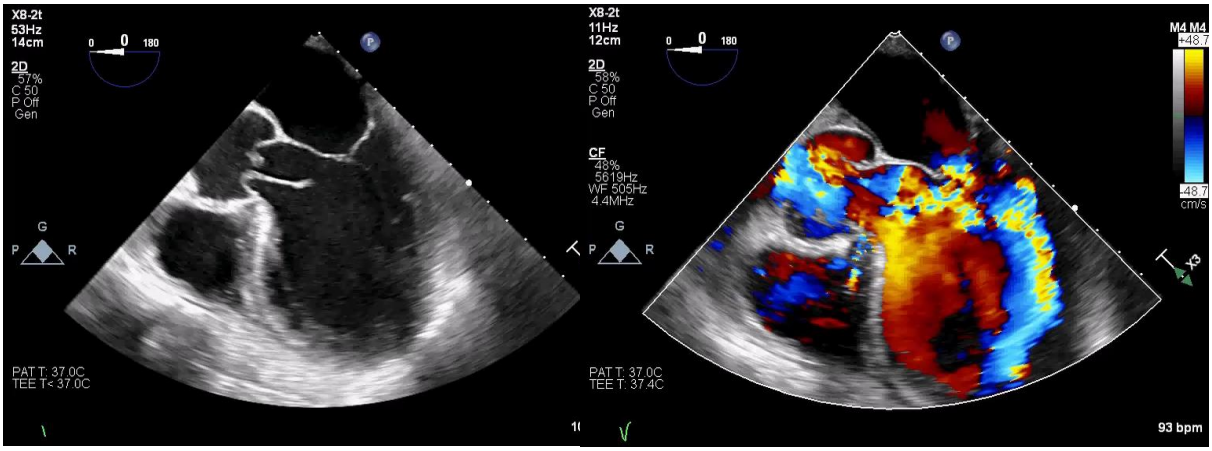

Subaortic Membrane

- M-Mode
  - Abrupt, very early posterior motion of right aortic cusp
  - Early systolic premature closure of aortic valve
  - Fluttering of the aortic leaflets post "dip" due to aortic regurgitation

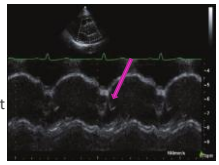

- Discrete fibrous membrane (90%)
- Muscular narrowing of LVOT (10%)
- Most common associated lesion are PDA, VSD, coarctation of the aorta, pulmonary valve stenosis
- Treatment is surgical resection
  - Symptomatic with peak LVOT gradient 50 mmHg or more
  - Peak LVOT gradient < 50 mmHg with heart failure or ischemia
  - Asymptomatic with mild aortic regurgitation and peak gradient 50 mmHg or more

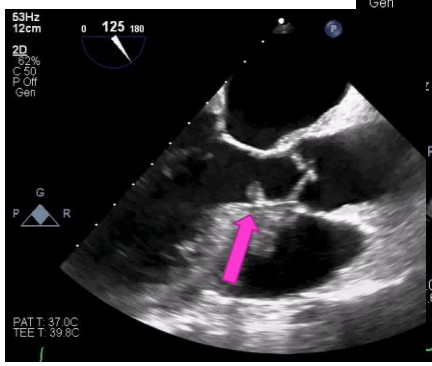

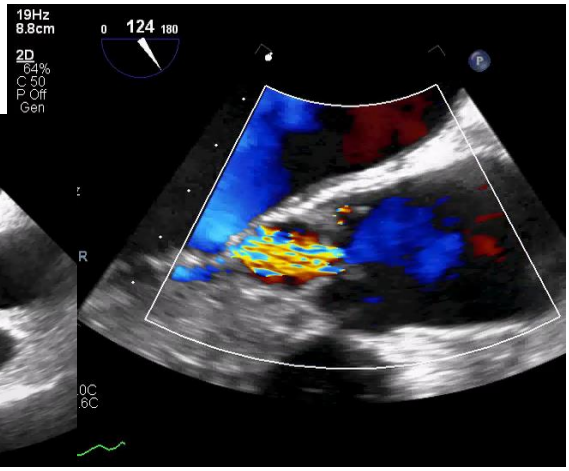

2018 AHA/ACC GUIDELINE MANAGEMENT ADULTS CONGENITAL HEART DISEASE

Connective Tissue Disorder (Marfan's)

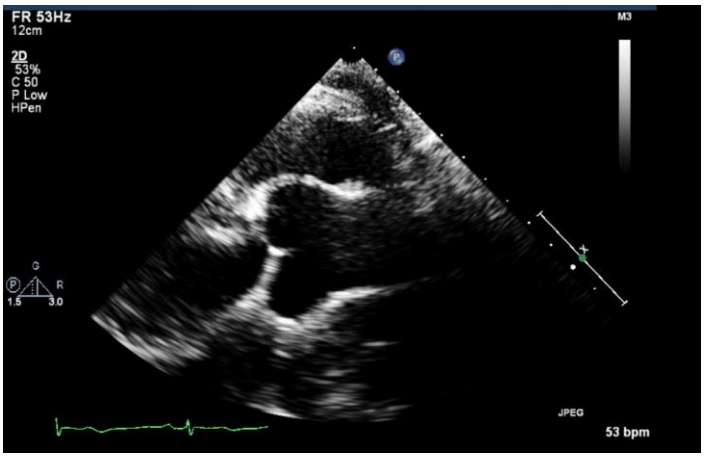

- Marked aortic root dilation

Aortic Dissection

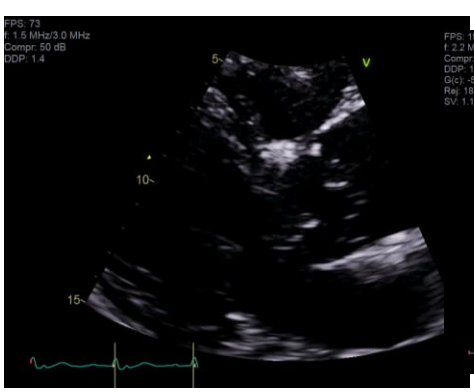

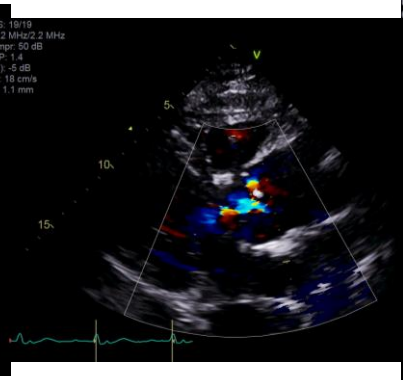

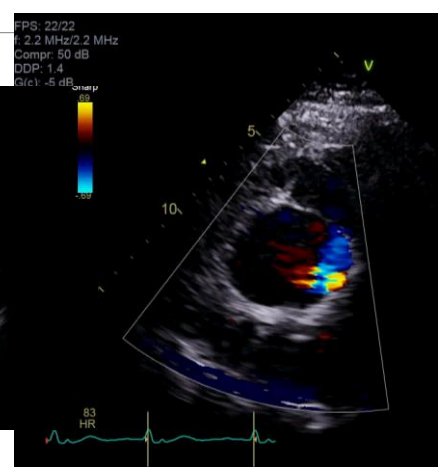

Quantitative Analysis & Equations

Principles

- Continuity = conservation of mass
  - Continuity for aortic valve
  - Area = volume / distance
    - Aortic valve area
    - Stroke volume = LVOT area x stroke distance
    - Transaortic distance (velocity time integral (VTI))
- Bernoulli = conservation of energy
  - Simplified → $\Delta P = 4V^2$
    - Account for V_2 if LVOT velocity > 2 m/s
    - $4(V_2^2 - V_1^2)$
- Flow Convergence = as blood approaches a regurgitant orifice, its velocity increases forming concentric, roughly hemispheric shells of increasing velocity and decreasing surface area

Flow Convergence Method

- $2\pi r^2 = 6.28r^2$
- $(6.28r^2)$(nyquist) / peak AR velocity
- Equals EROA

- Effective Regurgitant Orifice Area (EROA)
  - Area cm^2 = (flow cm/s) / (peak velocity cm/s)
- Proximal Isovelocity Surface Area (PISA) radius in cm

Modality	Optimization	Example	Advantages	Pitfalls
Quantitative Doppler: EROA, regurgitation volume and fraction				
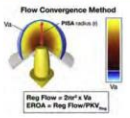	• Align insonation beam with the flow • Lower the color Doppler baseline in the direction of the jet • Look for the hemispheric shape to guide the best lower Nyquist limit • CWD of regurgitant jet for peak velocity and VTI	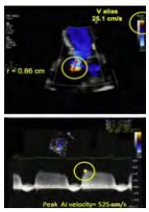	• Rapid quantitative assessment of lesion severity (EROA) and volume overload (RVol)	• Feasibility is limited by aortic valve calcifications • Not valid for multiple jets, less accurate in eccentric jets • Limited experience • Small errors in radius measurement can lead to substantial errors in EROA due to squaring of error.

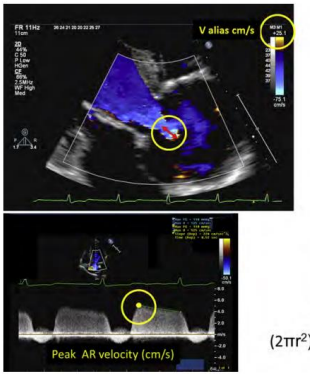

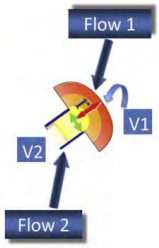

$Q_{prox} = Q_{distal}$

$A_1 V_1 = A_2 V_2$

$(2\pi r^2) \times Va = EROA \times PkV_{AR}$

ZOGHBI ET AL. JASE 2017.

Flow Convergence & PISA Example

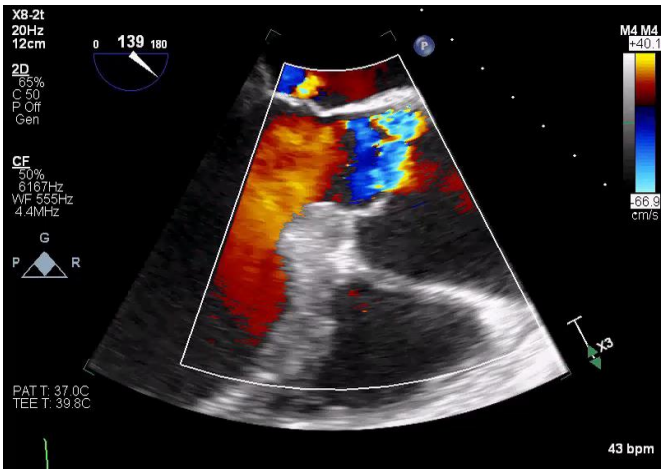

Stroke Volume (SV) Method

- Volume through mitral valve is representative of "full" amount
- Volume through LVOT will include regurgitant volume
- $SV_{mitral} + Rvol = SV_{lvot}$
- $Rvol = SV_{lvot} - SV_{mitral}$
- $SV = \pi r^2 \times$ stroke distance
- $\pi r^2 = \pi(d/2)^2 = \pi(d^2/4) = 0.785\ d^2$

Modality	Optimization	Example	Advantages	Pitfalls
SV method 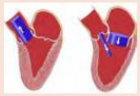 $RVol = SV_{LVOT} - SV_{MV}$	• LVOT diameter measured at the annulus in systole and pulsed Doppler from apical views at same site • Mitral annulus measured at middiastole; pulsed Doppler at the annulus level in diastole • Total LV SV can also be measured by the difference between LV end-diastolic volume and end-systolic volume. • LV volumes are best measured by 3D. Contrast may be needed to better trace endocardial borders. If 3D not feasible, use 2D method of disks.	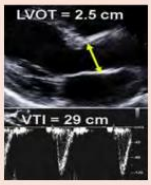 	• Quantitative, valid with multiple jets and eccentric jets. Provides both lesion severity (EROA, RF) and volume overload (RVol) • Verify results using LV end-diastolic volume and LV end-systolic volume	• Difficulties measuring mitral annulus diameter, particularly with annular calcification • Not valid for combined MR and AR, unless pulmonic site is used

ZOGHBI ET AL. JASE 2017.

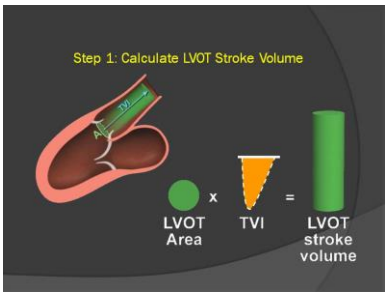

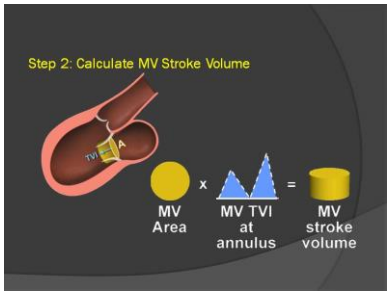

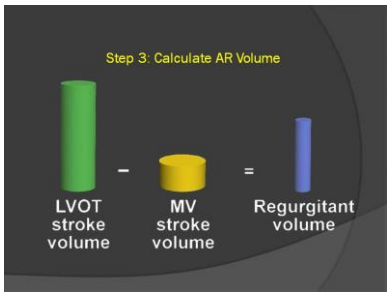

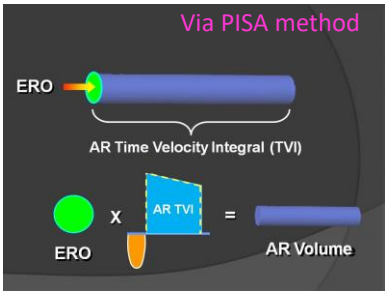

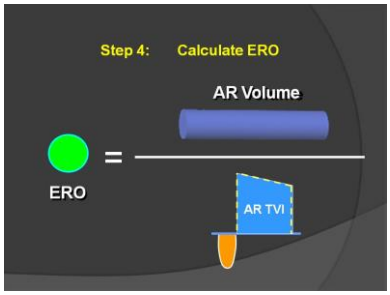

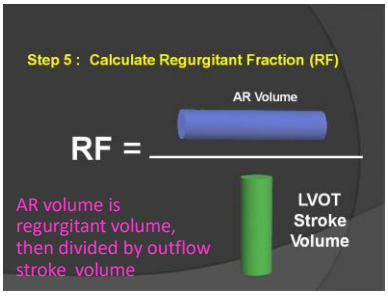

Table 11 Grading the severity of chronic AR with echocardiography

	AR severity			
	Mild	Moderate		Severe
Structural parameters				
Aortic leaflets	Normal or abnormal	Normal or abnormal		**Abnormal/flail, or wide coaptation defect**
LV size	**Normal***	Normal or dilated		Usually dilated†
Qualitative Doppler				
Jet width in LVOT, color flow	**Small in central jets**	Intermediate		**Large in central jets**; variable in eccentric jets
Flow convergence, color flow	**None or very small**	Intermediate		**Large**
Jet density, CW	**Incomplete or faint**	Dense		Dense
Jet deceleration rate, CW (PHT, msec)‡	Incomplete or faint Slow, >500	Medium, 500-200		**Steep, <200**
Diastolic flow reversal in descending aorta, PW	**Brief, early diastolic reversal**	Intermediate		**Prominent holodiastolic reversal**
Semiquantitative parameters§				
VCW (cm)	<0.3	0.3-0.6		>0.6
Jet width/LVOT width, central jets (%)	<25	25-45	46-64	≥65
Jet CSA/LVOT CSA, central jets (%)	<5	5-20	21-59	≥60
Quantitative parameters§				
RVol (mL/beat)	<30	30-44	45-59	≥60
RF (%)	<30	30-39	40-49	≥50
EROA (cm^2)	<0.10	0.10-0.19	0.20-0.29	≥0.30

- Mild AR:
  - Jet width <25% of LVOT
  - Vena contracta <0.3 cm
  - Regurgitant volume <30 mL/beat
  - Regurgitant fraction <30%
  - ERO <0.10 cm^2
  - Angiography grade 1
- Moderate AR:
  - Jet width 25%-64% of LVOT
  - Vena contracta 0.3-0.6 cm
  - Regurgitant volume 30-59 mL/beat
  - Regurgitant fraction 30% to 49%
  - ERO 0.10-0.29 cm^2
  - Angiography grade 2
- Severe AR:
  - Jet width ≥65% of LVOT
  - Vena contracta >0.6 cm
  - Holodiastolic flow reversal in the proximal abdominal aorta
  - Regurgitant volume ≥60 mL/beat
  - Regurgitant fraction ≥50%
  - ERO ≥0.3 cm^2
  - Angiography grade 3 to 4
  - In addition, diagnosis of chronic severe AR requires evidence of LV dilation

Left Ventricular End Diastolic Pressure

Pressure originating $chamber_{aorta}$ = $4v^2$ + Pressure receiving $chamber_{left\ ventricle}$

$\Delta P = 4\ V^2$

ΔP = DBP – LVEDP

DBP – LVEDP = 4 ($AR_{end\text{-}diastolic\ peak}$ velocity)^2

LVEDP = DBP - 4 ($AR_{end\text{-}diastolic\ peak}$ velocity)^2

If BP is 130/40:

4(AR velocity)^2 = DBP – LVEDP
LVEDP = DBP - 4(AR velocity)^2
LVEDP = 40 - 4(1.5)^2
LVEDP = 40 – 9
LVEDP = 31 mmHg

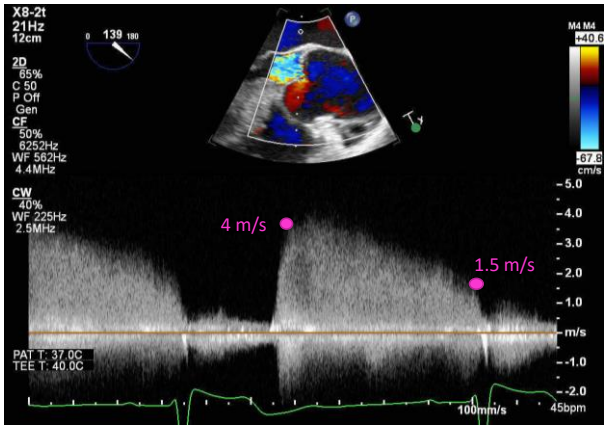

Aortic Valve Interventions

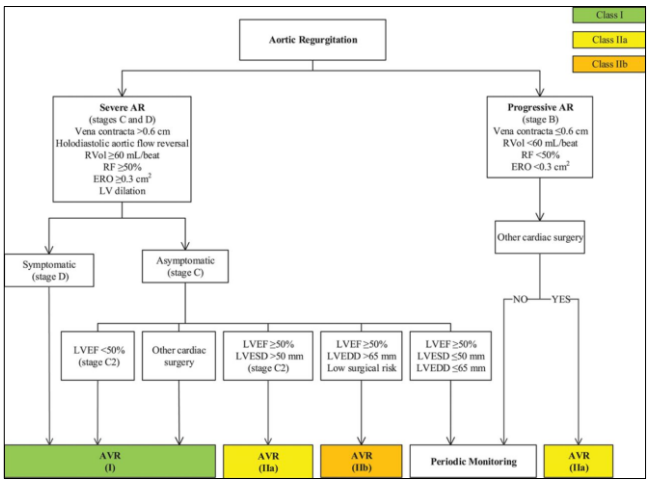

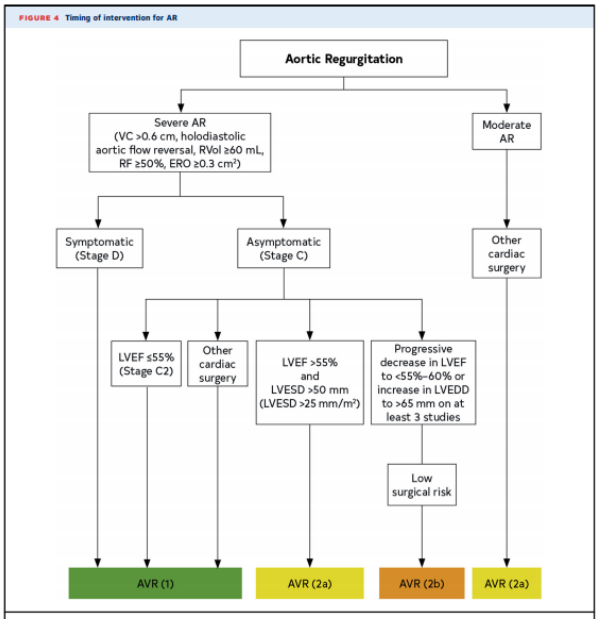

NISHIMURA 2014;
OTTO ET AL 2020

Mechanical Aortic Valve

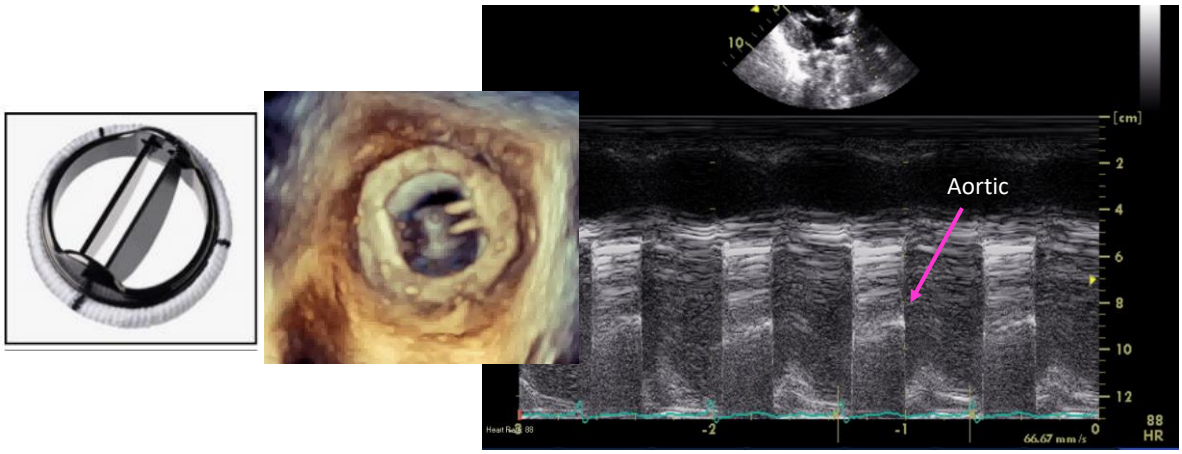

Bioprosthetic Aortic Valve

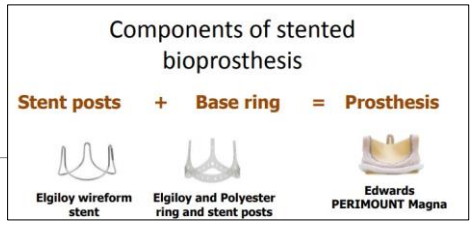

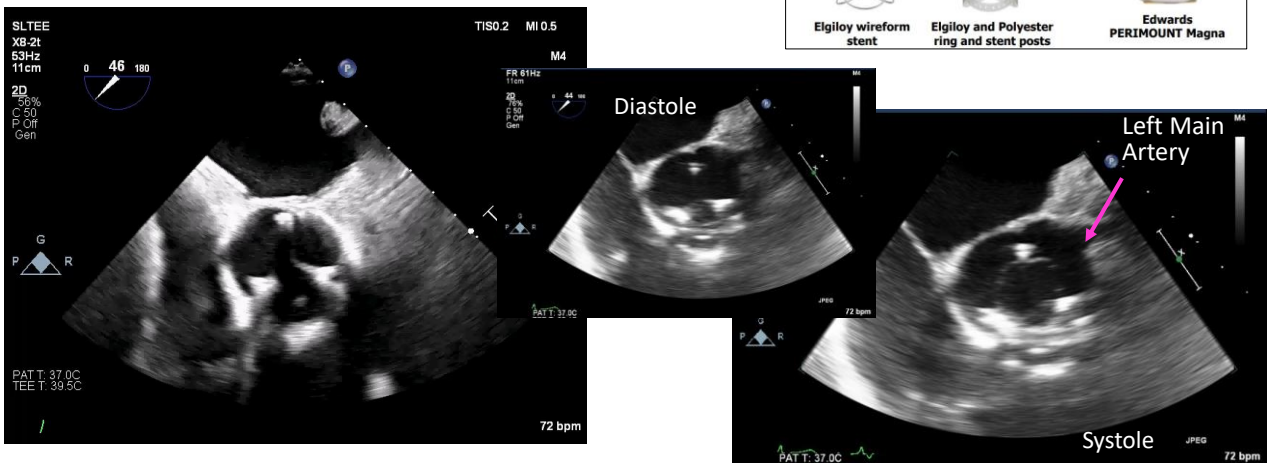

IMAGE ADAPTED FROM PIAZZA ET AL, BMJ 2012

Back to the Questions

Question 1

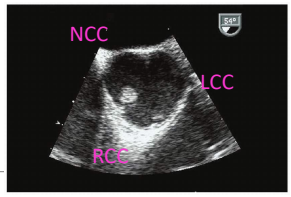

3. In the midesophageal TEE short axis of the aortic valve:

A. The non-coronary cusp is the most anterior cusp.

B. The left coronary cusp is the most anterior cusp.

C. The right coronary is adjacent to the interatrial septum.

D. The non-coronary cusp is adjacent to the interatrial septum.

Teaching points

- The non-coronary cusp is adjacent to the interatrial septum.
- The right coronary cusp is the most anterior cusp (farthest from the transducer on TEE)

18. This short-axis of the aortic valve shows (Fig. 6-3):

A. Bicuspid aortic valve.

B. Lambl's excrescence.

C. Fibroelastoma of the left coronary cusp.

D. Fibroelastoma of the noncoronary cusp.

Teaching points

- Papillary fibroelastomas are benign tumors
- Seen on aortic valve
- Small, well-delineated, pedunculated masses
- Small <20 mm
- Half have stalks
- Highly mobile
- High embolic risk

Question 2

Teaching points

- Subaortic stenosis is treated surgically
- Most common associated lesion are PDA, pulmonary valve stenosis, coarctation of the aorta, VSD

5. A 30-year-old woman is referred for management of a newly diagnosed subaortic stenosis. She is asymptomatic, but during a routine physical examination a loud systolic murmur was heard. An echocardiogram demonstrated a subaortic membrane with a gradient of 44 mm Hg and concomitant presence of moderate aortic valve regurgitation. The left ventricle is borderline enlarged, with an LVEF of 57%. At TEE, the aortic valve does not appear to be calcified. Which of the following statements are correct?

A. This type of lesion responds well to balloon dilatation.

B. The patient should undergo resection of the subaortic membrane and aortic valve replacement.

C. Careful inspection of the pulmonary valve and pulmonary artery should be carried out during TEE.

D. Doppler interrogation of the abdominal aorta provides no information in this case.

Question 3

Teaching points

- Watch units!!!

6. Which of the following statements regarding aortic regurgitation (AR) is correct?

A. A PISA radius of 0.8 cm with an aliasing velocity of 40 cm/s and a peak aortic regurgitant velocity of 4 m/s is consistent with severe AR.

B. A pressure half-time greater than 250 ms is consistent with severe AR.

C. Vena contracta is best evaluated from the apical long-axis view.

D. The use of the suprasternal notch window is not useful in the assessment of AR.

continuity equation as

Isovelocity flow = regurgitant flow

Isovelocity area × aliasing velocity = EROA × Regurgitant velocity

$2 \times \pi \times R^2 \times$ aliasing velocity = ERO × regurgitant velocity

$$\text{EROA} = \frac{2 \times \pi \times R^2 \times \text{aliasing velocity}}{\text{Regurgitant velocity}}$$

Replacing the numbers, this becomes:

$$\text{EROA} = \frac{2 \times \pi \times 0.8^2 \times 40}{400} = 0.40\ \text{cm}^2,$$

Question 4

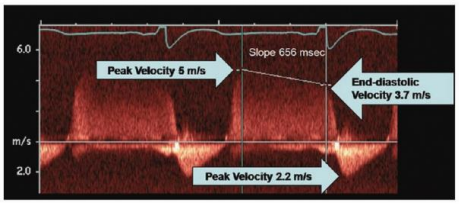

8. A 67-year-old man with aortic regurgitation underwent transthoracic echocardiographic examination. There was no mitral stenosis or regurgitation. The following values were obtained:

Table 8-8

Peak diastolic velocity of aortic regurgitant jet	5.0 m/s
End-diastolic velocity of aortic regurgitant jet	3.7 m/s
Pressure half-time of aortic regurgitant jet	656 ms
Peak aortic antegrade flow velocity	2.2 m/s
Blood pressure	130/65 mm Hg

Based on the aforementioned data, one can conclude that:

A. Pressure half-time is consistent with severe aortic regurgitation.

B. Aortic valve area can be estimated as 220 divided by pressure half-time.

C. Peak left ventricular systolic pressure (LVSP) is lower than the systolic blood pressure (SBP).

D. Left ventricular end-diastolic pressure (LVEDP) is estimated at 10 mm Hg.

E. Aortic valve area cannot be calculated using continuity equation because there is aortic regurgitation.

Using the end-diastolic velocity (V) of the aortic regurgitant jet, one can calculate the pressure gradient (ΔP) between the diastolic blood pressure (DBP) and the LVEDP.

$$\Delta P = \text{DBP} - \text{LVEDP} = 4 \times V^2 \quad (1)$$

Rearranging Eq. 1, LVEDP can be calculated in the following manner if the DBP is known:

$$\text{LVEDP} = \text{DBP} - 4 \times V^2 \quad (2)$$

In our patient:

LVEDP = 65 mm Hg - 4 × $(3.7\ \text{m/s})^2$ = 10 mm Hg

Therefore, answer D is correct.

Thank You
and
Good Luck!