3D Echocardiography

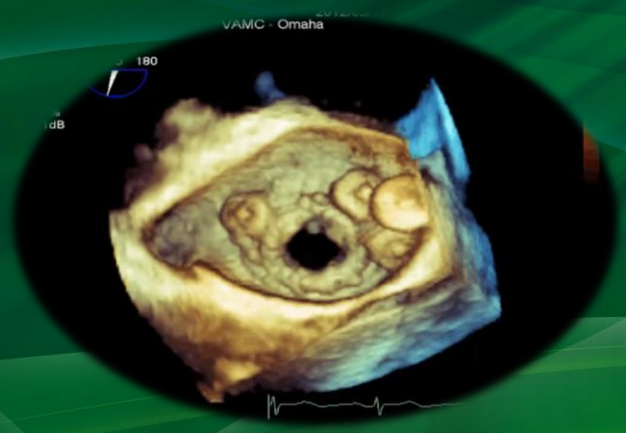

Aiman Smer, MBBCh, FACC, FASE
Associate Professor of Medicine
Creighton University School of Medicine

No Disclosure

Objectives

- Understand the concepts of 3D imaging
- Clinical applications of 3D echocardiography
- 3D image acquisition and optimization

The Heart

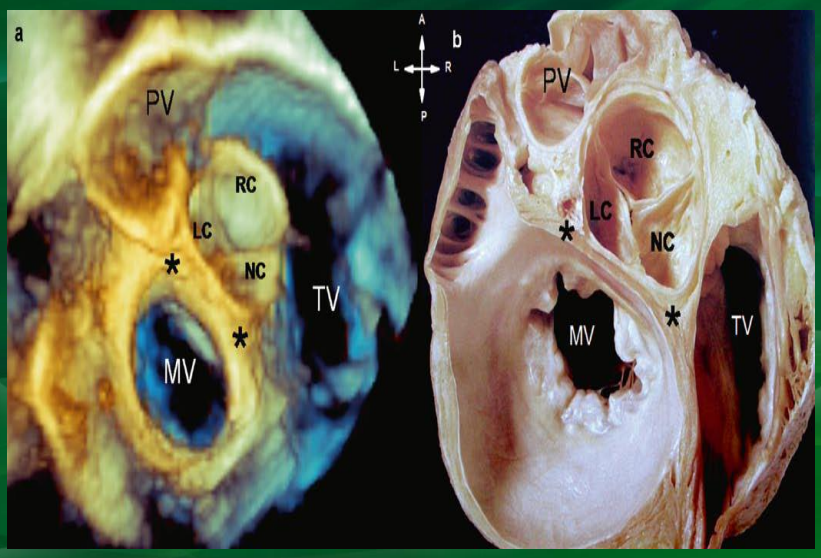

The Evolution of Echocardiography

A-mode

B-mode

M-mode

2D-mode

3D-mode

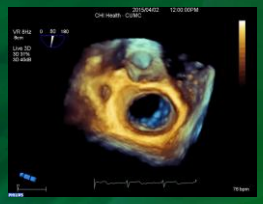

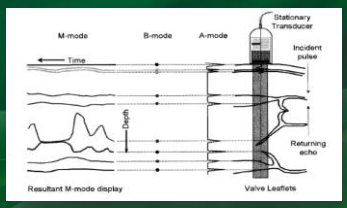

1st Cardiac US
1960

From Edler I, Ultrasound cardiography. Acta Med Scand Suppl 370 1961; 170:39

3D Technology

- New generation Piezoelectric crystals (PureWave Crystals)
- Microelectronics



FIGURE 1.2 (a) The figure shows the imperfect, multicrystalline, randomly orientated grains of conventional transducer material; (b) This figure, however, shows the nearly perfect atomic level arrangement: uniform, with no grain boundaries of PureWave material.

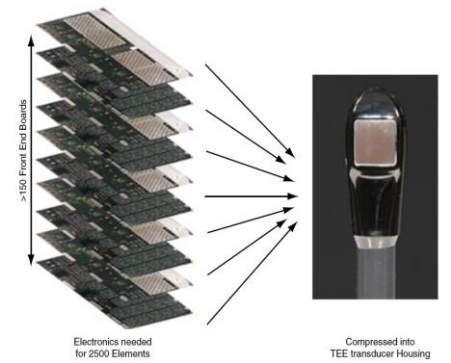

3D Technology

- New generation Piezoelectric crystals (PureWave Crystals)
- Microelectronics

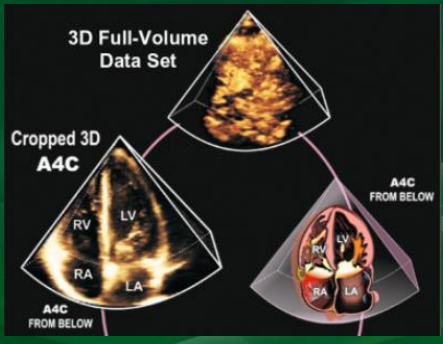

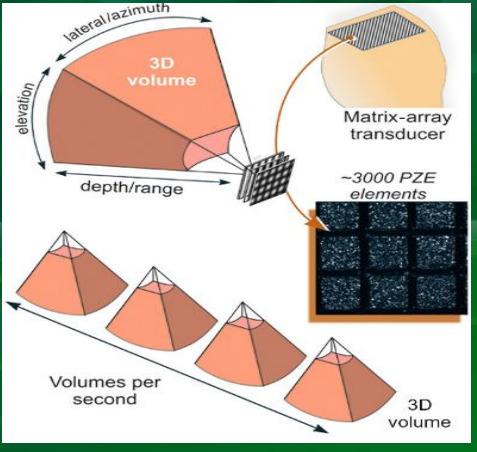

Modified from Bulwer BE, Rivero JM, editors. Echocardiography Pocket Guide: The Transthoracic Examination. Burlington, Mass: Jones & Bartlett Learning, 2011, 2013, p 208

3D Probe

- The 3D probe provides all conventional modalities, such as 2D imaging, M-mode, pulse and continuous wave Doppler, and color Doppler imaging
- X-Plane technology

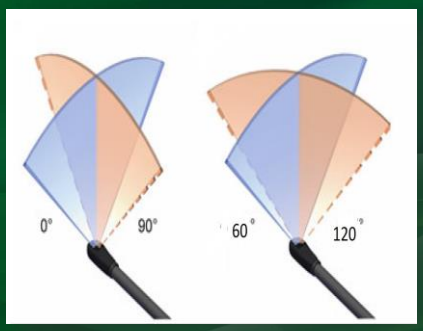

Clinical applications of 3D echocardiography

- Chamber quantification
- Valvular heart disease
  - Native and prosthetic valves
- Intracardiac masses
- Congenital heart defects
  - Anatomic assessment and procedural guidance
- Interventional cardiac procedures
  - TAVR, MitraClip, LAA occlusion devices
- Stress echo

Chamber Quantification and Function

- 2D method
  - Subjective
  - Experience dependent
  - Large inter- and intra-observer variability
- 3D method
  - No geometric assumption
  - Avoid foreshortening
  - Reproducible
  - Excellent correlation with CMR

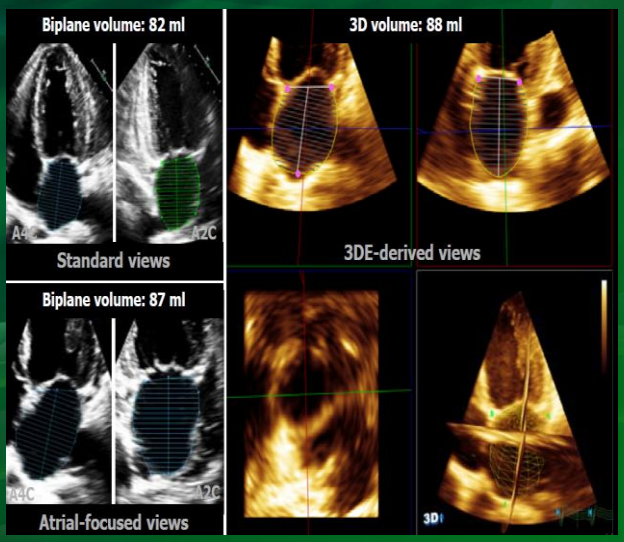

Mor-Avi V, Lang RM et al., *Circulation* 2004. 110: 1814-1818
Jacobs LD, et al. Eur Heart J 2005; 27:460-8

Valvular heart disease

- Assessment of mitral valve anatomy
- LVOT and aortic annulus sizing
- Valve area measurement via direct planimeter in mitral and aortic valve stenosis
- Regurgitant orifice measurement via vena contracta in regurgitant lesions
- Evaluation of prosthetic valve malfunction and paravalvular leak

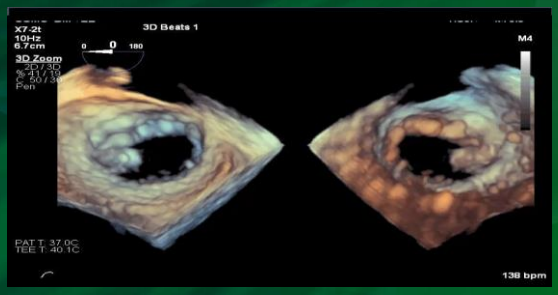

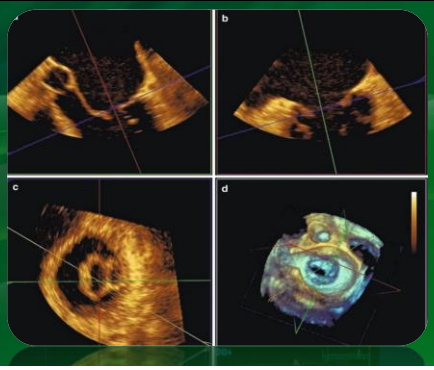

54 M with new onset AF …!

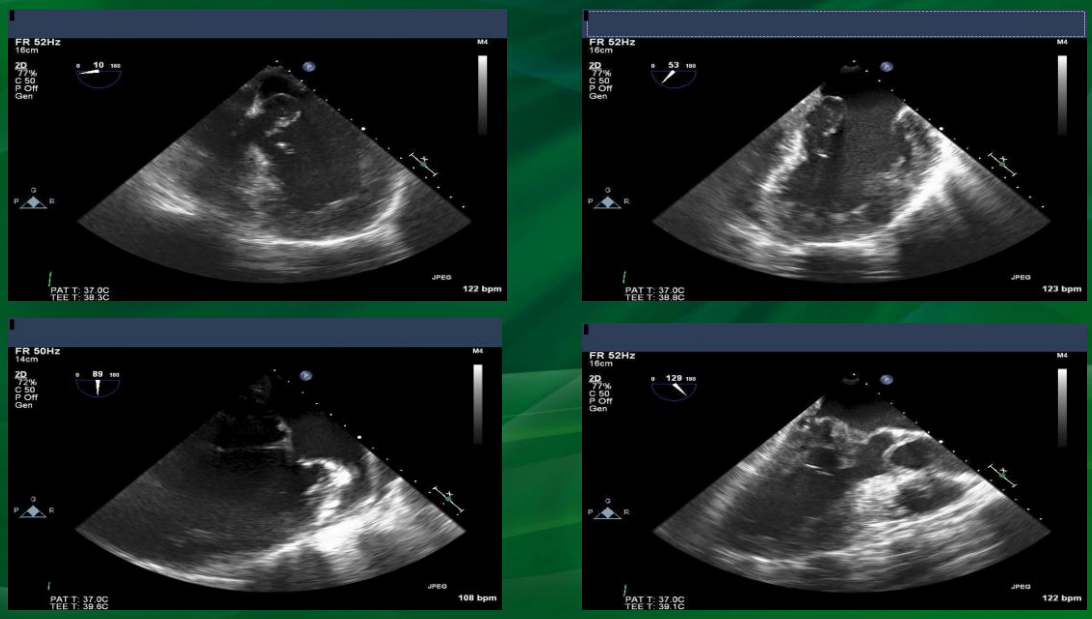

54 M with new onset AF …!

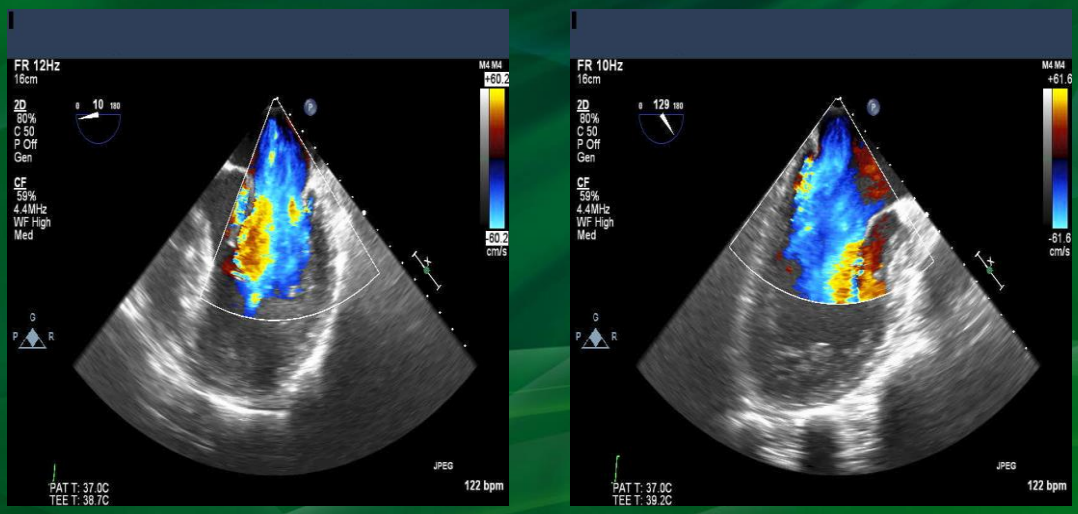

54 M with new onset AF …!

LA *en face* view of MV

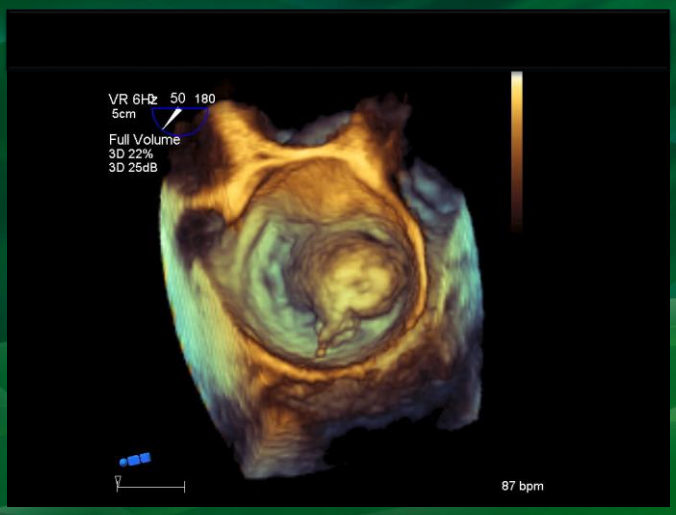

71 M with severe MR due to MSSA IE, s/p bioprosthetic MVR

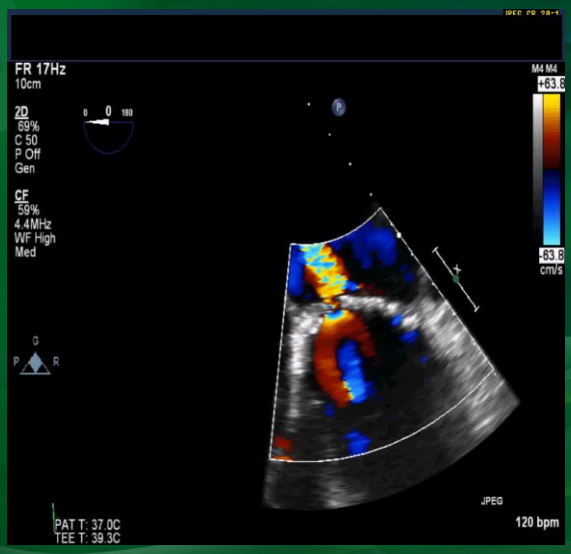

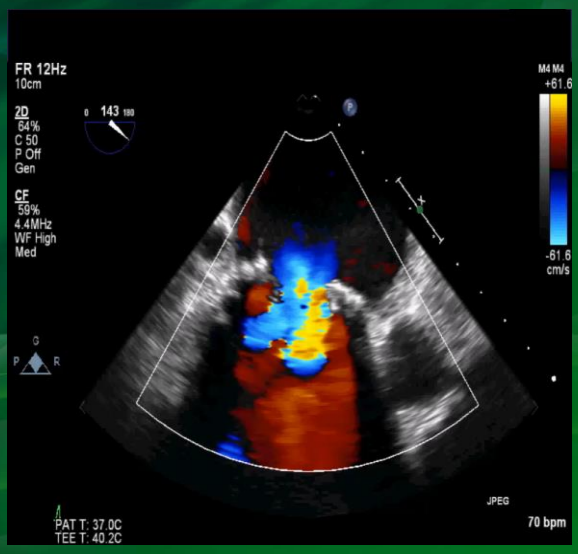

71 M with severe MR due to MSSA IE, s/p bioprosthetic MVR

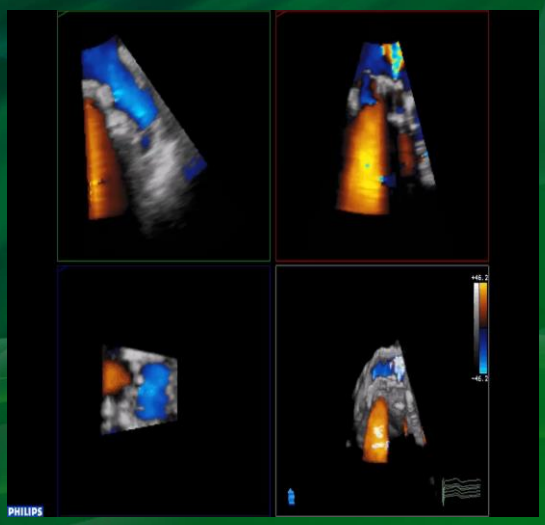

71 M with severe MR due to MSSA IE s/p bioprosthetic MVR

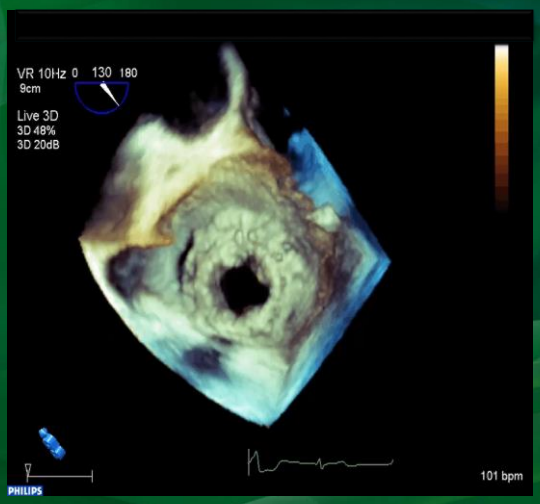

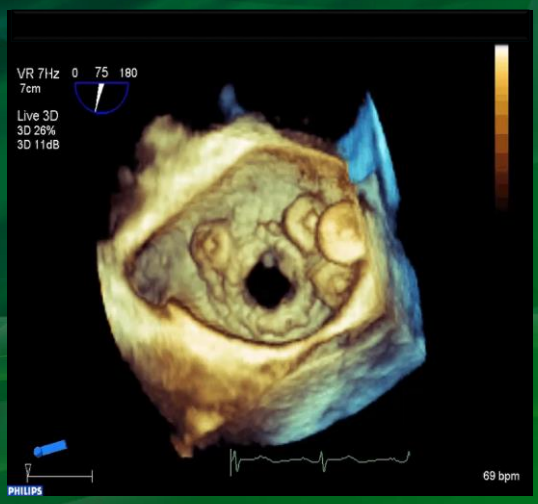

Cardiac masses

Lambl's excrescences

Papillary fibroelastoma

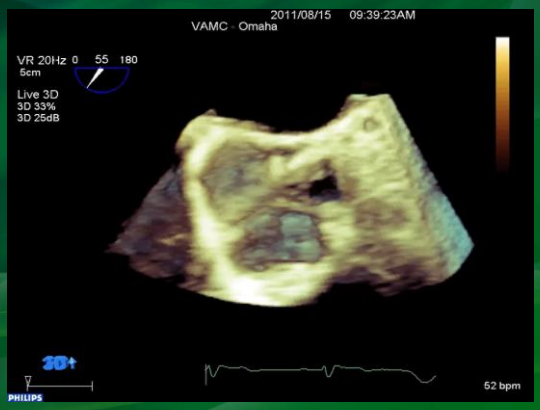

Interventional cardiac procedures

MitraClip

LAA occlusion device

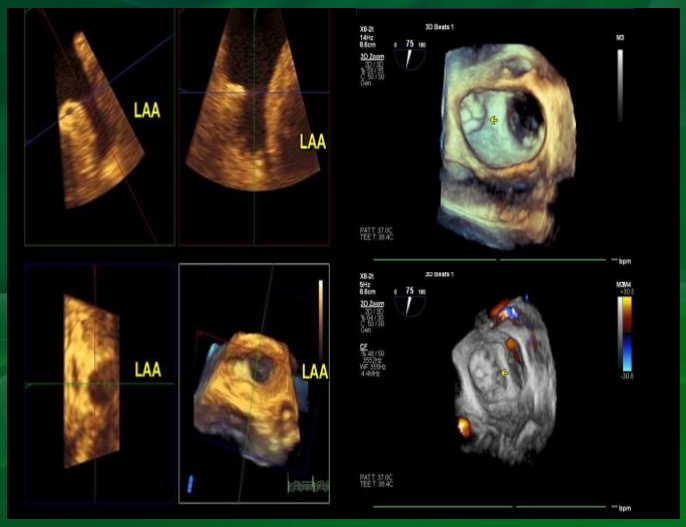

3D Imaging Acquisition, Display and Processing

GUIDELINES AND STANDARDS

EAE/ASE Recommendations for Image Acquisition and Display Using Three-Dimensional Echocardiography

Roberto M. Lang, MD, FASE,*‡ Luigi P. Badano, MD, FESC,†‡ Wendy Tsang, MD,* David H. Adams, MD,* Eustachio Agricola, MD,† Thomas Buck, MD, FESC,† Francesco F. Faletra, MD,† Andreas Franke, MD, FESC,† Judy Hung, MD, FASE,* Leopoldo Pérez de Isla, MD, PhD, FESC,† Otto Kamp, MD, PhD, FESC,† Jaroslaw D. Kasprzak, MD, FESC,† Patrizio Lancellotti, MD, PhD, FESC,† Thomas H. Marwick, MBBS, PhD,* Marti L. McCulloch, RDCS, FASE,* Mark J. Monaghan, PhD, FESC,† Petros Nihoyannopoulos, MD, FESC,† Natesa G. Pandian, MD,* Patricia A. Pellikka, MD, FASE,* Mauro Pepi, MD, FESC,† David A. Roberson, MD, FASE,* Stanton K. Shernan, MD, FASE,* Girish S. Shirali, MBBS, FASE,* Lissa Sugeng, MD,* Folkert J. Ten Cate, MD,† Mani A. Vannan, MBBS, FASE,* Jose Luis Zamorano, MD, FESC, FASE,† and William A. Zoghbi, MD, FASE*, *Chicago and Oak Lawn, Illinois; Padua and Milan, Italy; New York, New York; Essen and Hannover, Germany; Lugano, Switzerland; Boston, Massachusetts; Madrid, Spain; Amsterdam and Rotterdam, The Netherlands; Lodz, Poland; Liege, Belgium; Cleveland, Ohio; Houston, Texas; London, United Kingdom; Rochester, Minnesota; Charleston, South Carolina; New Haven, Connecticut; Morrisville, North Carolina*

(J Am Soc Echocardiogr 2012;25:3-46.)

Keywords: Echocardiography, Two-dimensional, Three-dimensional, Transthoracic, Transesophageal

Steps of Acquisition

1. 2D Image

2. Mode of Acquisition
   - Live 3D
   - 3D Zoom
   - Full Volume
   - Single vs multi-beat
   - Color Doppler

3. Rendering

4. Image Acquisition and Display
   - Cropping

5. Final Image

Imaging Acquisition

- Real-time (live) acquisition
  - Live 3D narrow volume
  - 3D zoom
- Full-volume (ECG-gated)

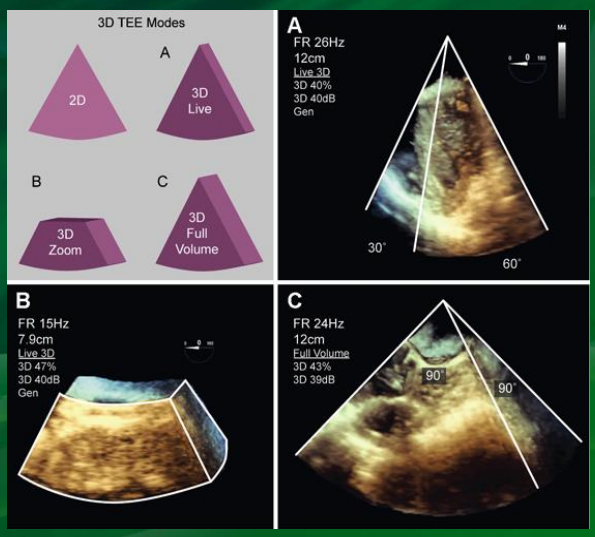

Imaging Acquisition

- Real-time (live) acquisition
  - Live 3D narrow volume (50x30)

  - 3D zoom

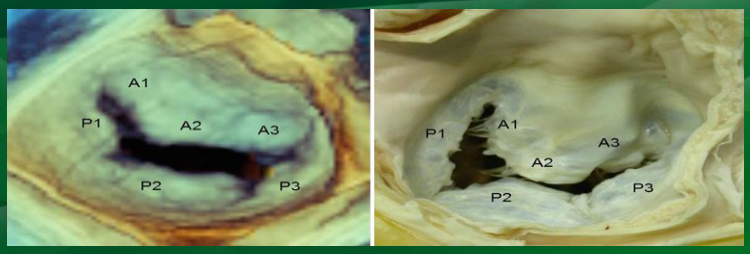

Imaging Acquisition

- Full-Volume
  - A pyramidal volume of 60 x 60 up to 100 x 100
  - Large cardiac volume
  - Require ECG gating
  - Full volume is constructed by merging 2-6 narrow segments of the pyramidal database
- Full-Volume 3 D with Color Doppler

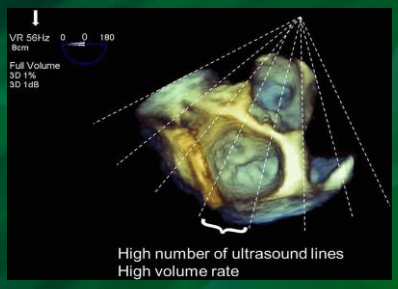

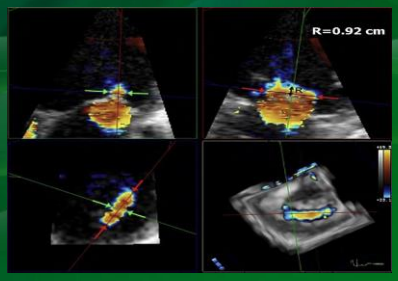

Which 3D mode to use ..?

LV, LA or RV quantification	Structural or congenital heart defects	Interventional Guidance
↓	↓	↓
Full Volume	Live 3D + Color 3D Zoom, Full Volume	Live 3D 3D Zoom

3D Zoom Acquisition of Mitral Valve

1) Initial view in 3D zoom is a biplane preview
2) X and Y planes and elevation width (Z axis) to include entire structure of interest
3) Press 3D zoom again will generates a pyramid of 3D volume (X,Y, Z)
4) En Face MV view, tilt 3D volume down 90 degree, then rotate clockwise or counter-clock to position the aortic valve at 12 clock
5) Decrease gain

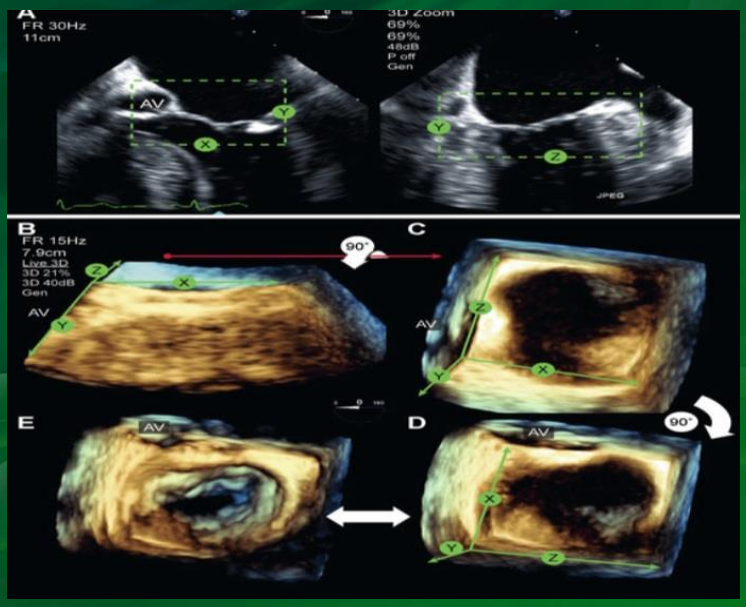

IAS at 90 degree

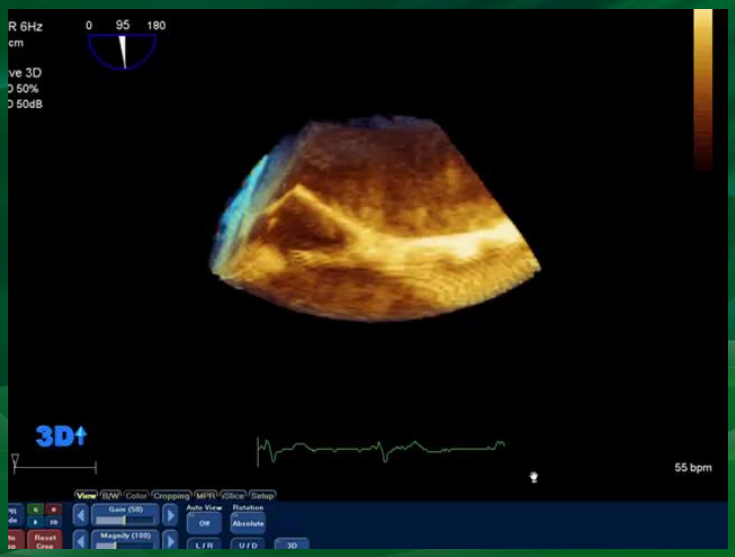

Saric M et al. J Am Soc Echocardiogr

Acquisition and presentation of cardiac valves

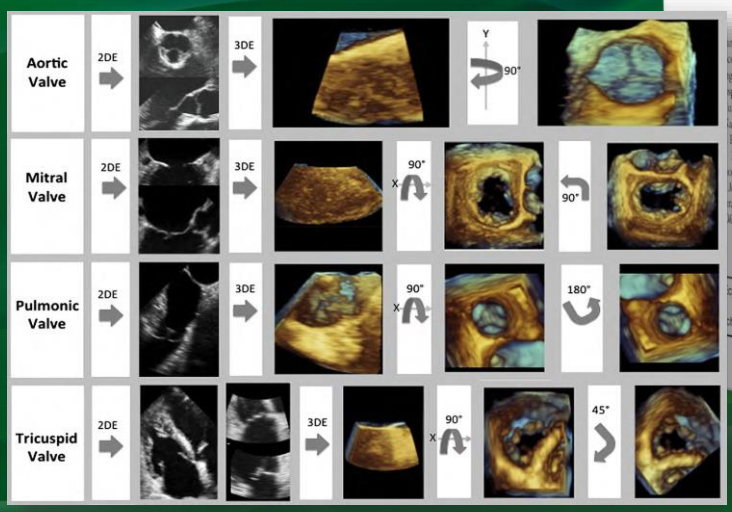

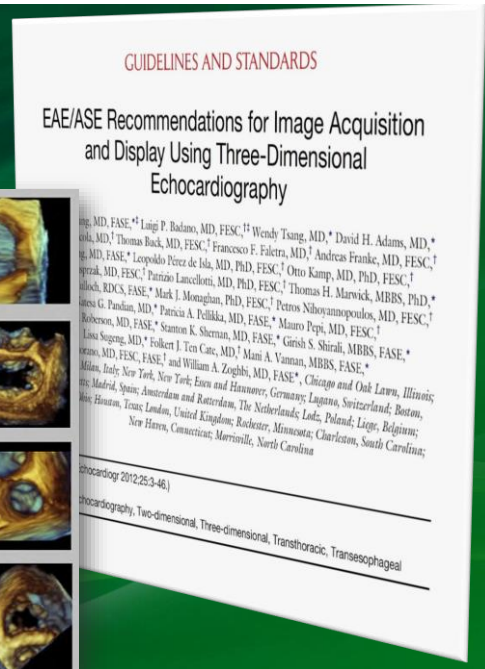
GUIDELINES AND STANDARDS

EAE/ASE Recommendations for Image Acquisition and Display Using Three-Dimensional Echocardiography

J Am Soc Echocardiogr 2012;25:3-46

3D presentation of cardiac structures

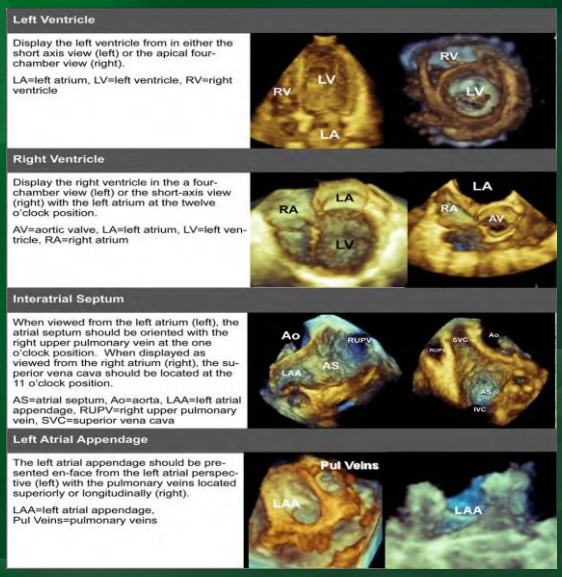

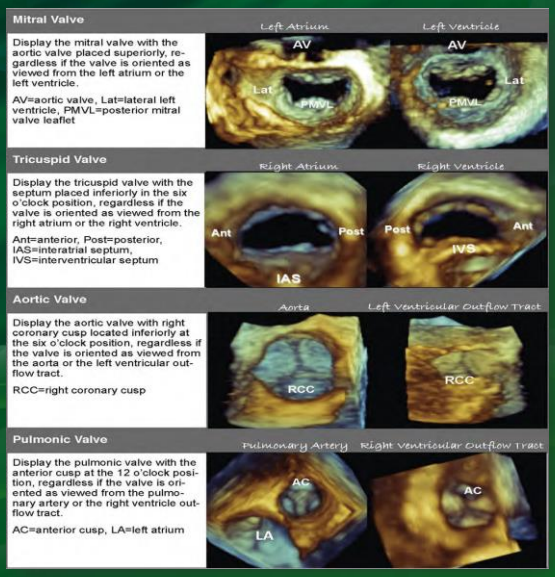

J Am Soc Echocardiogr 2012;25:3-46

3D image optimization

- Optimize 2 D image
- Adjust the gain
- Zoom on the ROI
- Adjust focus depth
- Choose small sector

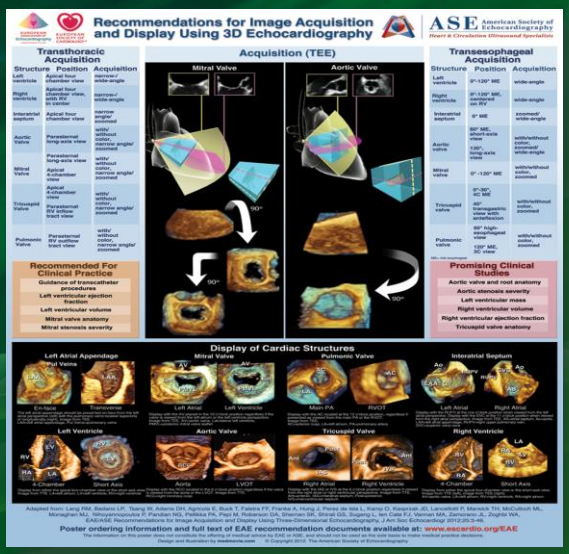

Quality 3D images always start wit a good 2D image

Imaging Rendering Process

- Cropping
- Gain
- Compression
- Brightness
- Smoothing
- Color-Map vision

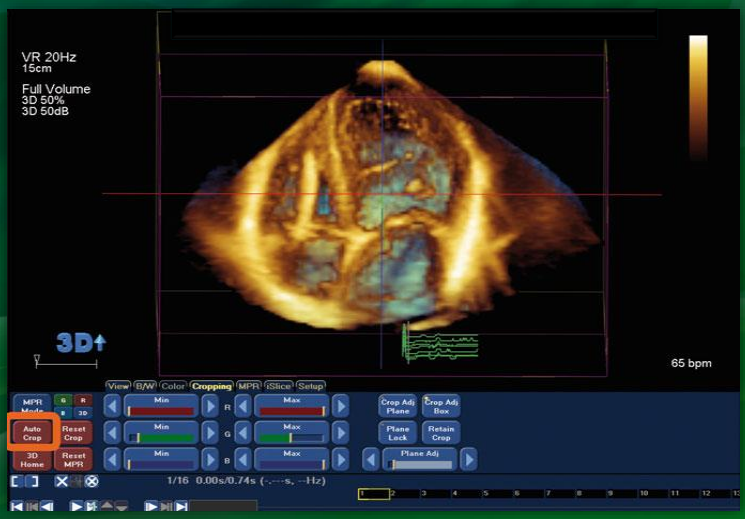

Gain

- Removes noise from structures

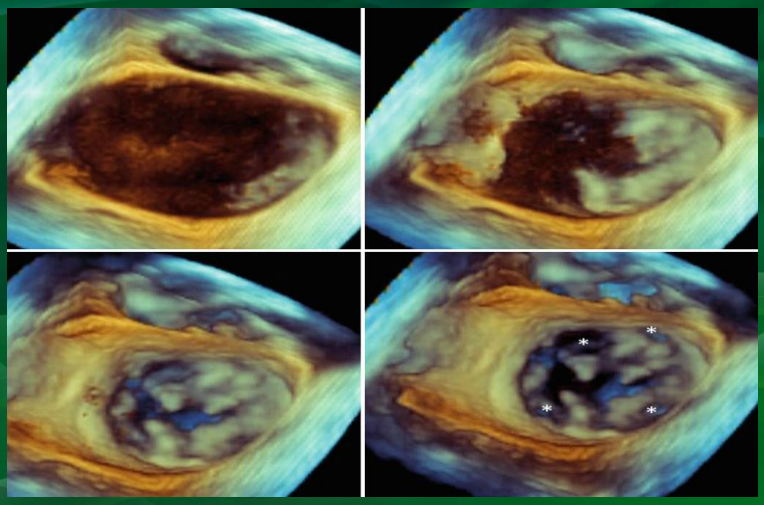

Compression

- High values of compression add “soft” echos, making objects appear more opaque and larger

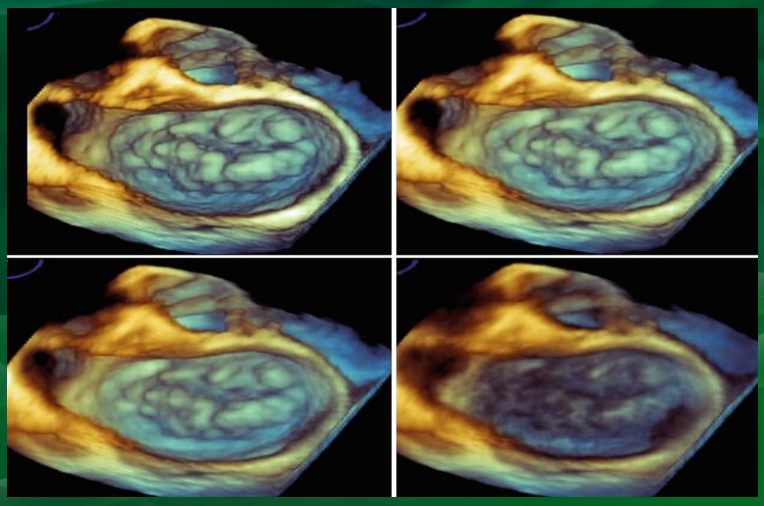

- Lower compression values are preferred, 2-4 on scale of 0-10

Brightness

- To avoid under-illumination or over-illumination, a medium level of brightness ranging from 40-50 (scan 0-100) should be used

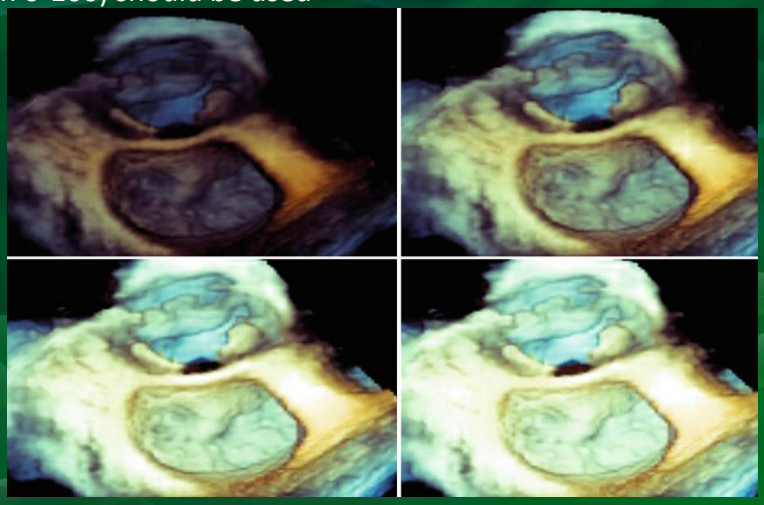

Smoothing

- Removes subtle roughness of the surface

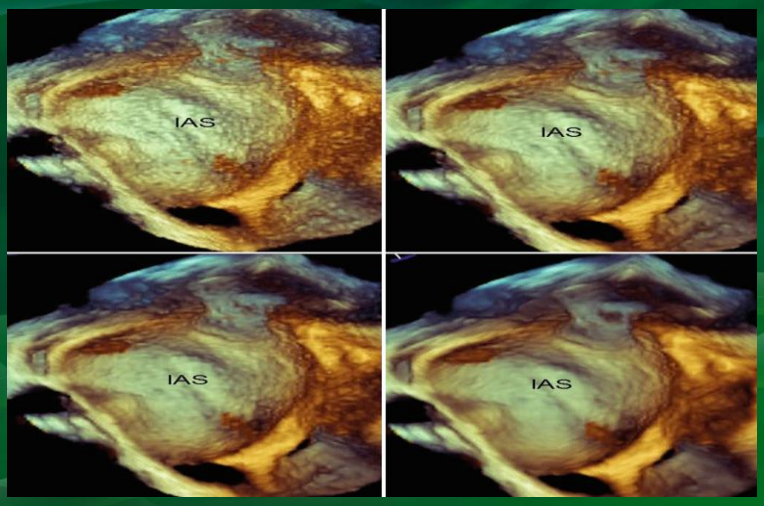

- Medium values 6-8 on a scale 0-10 allows precise definition of structure

Color-Map Vision

- Grayscale shades or dual-color mapping for depth perception

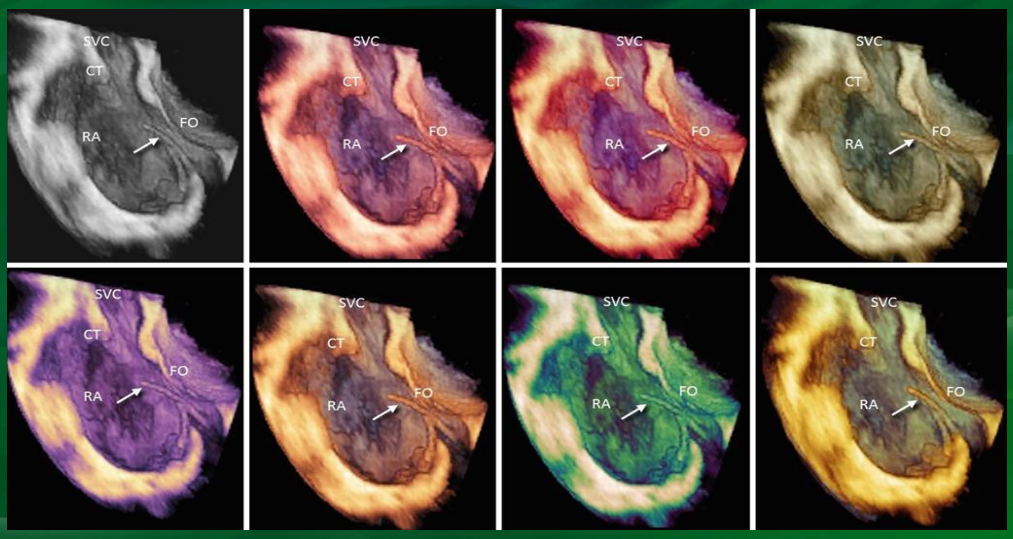

Advantages of 3D Echo

- Evaluation of cardiac chamber volumes and mass
- Assessment of regional left ventricular wall motion and quantification of systolic dyssynchrony
- Presentation of realistic views of heart valves
- Volumetric evaluation of regurgitant lesions and shunts with 3DE color Doppler imaging

Disadvantages of 3D Echo

- Time consuming
- Requires training in 3D analysis
- Accuracy varies with expertise and vendors
- Temporal resolution
- Relies on good 2D image

Everything in nature is *3D* …!

Thank you